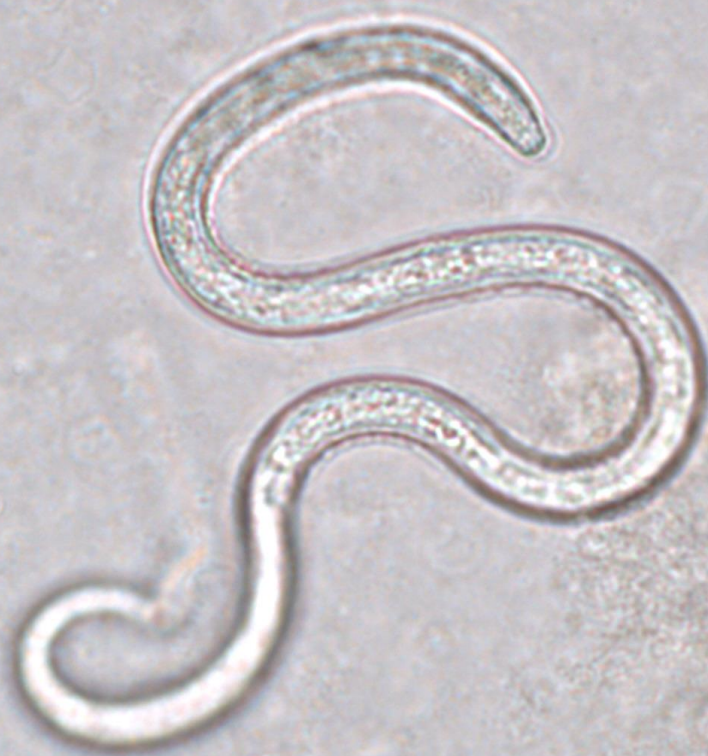



SKML 2020.1A
Loa loa (microfilaria - unstained)

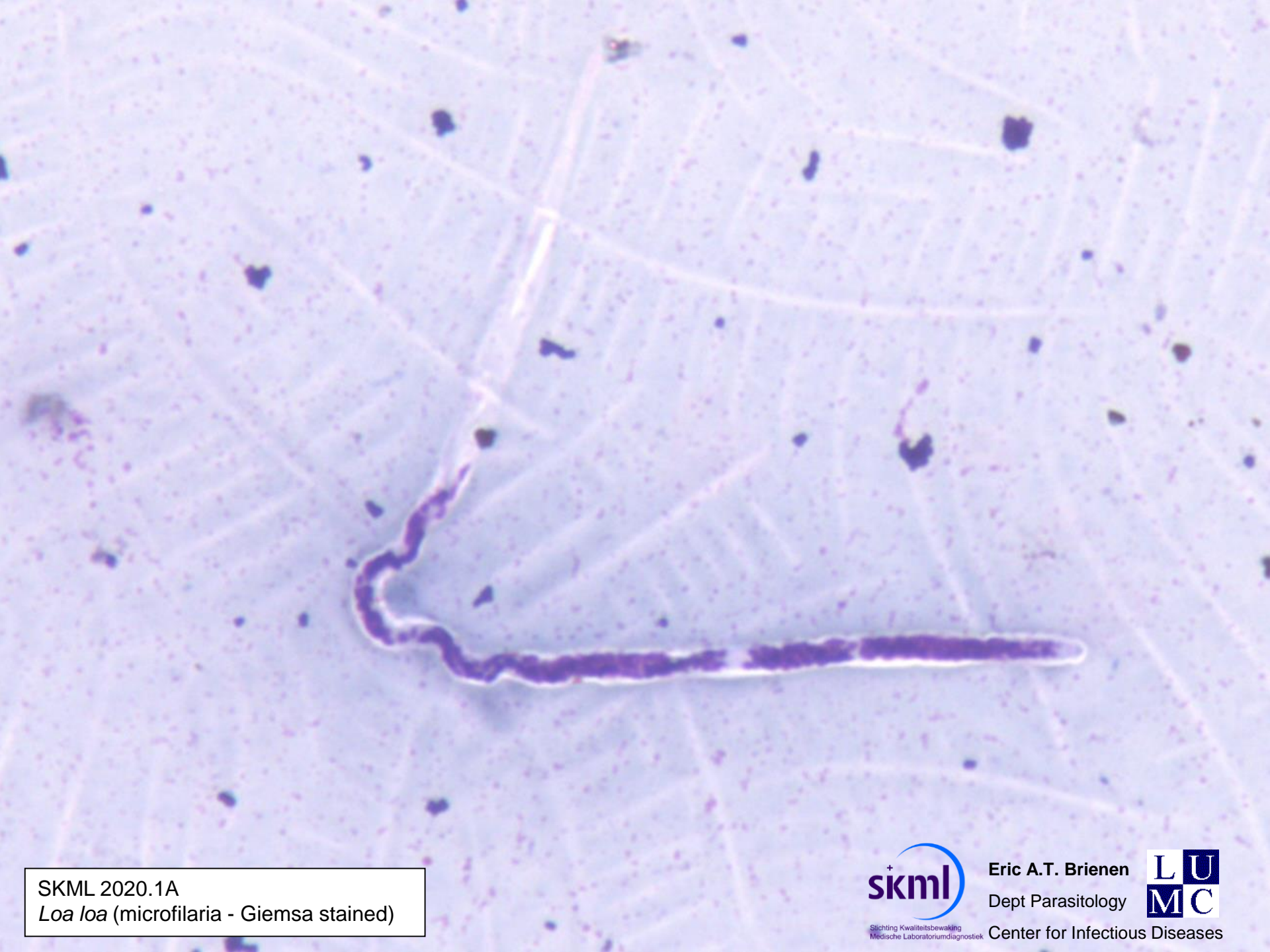

Stichting Kwaliteitsbewaking
Medische Laboratoriumdiagnostiek

Eric A.T. Brienen
Dept Parasitology



Center for Infectious Diseases



SKML 2020.1A
Loa loa (microfilaria - Giemsa stained)

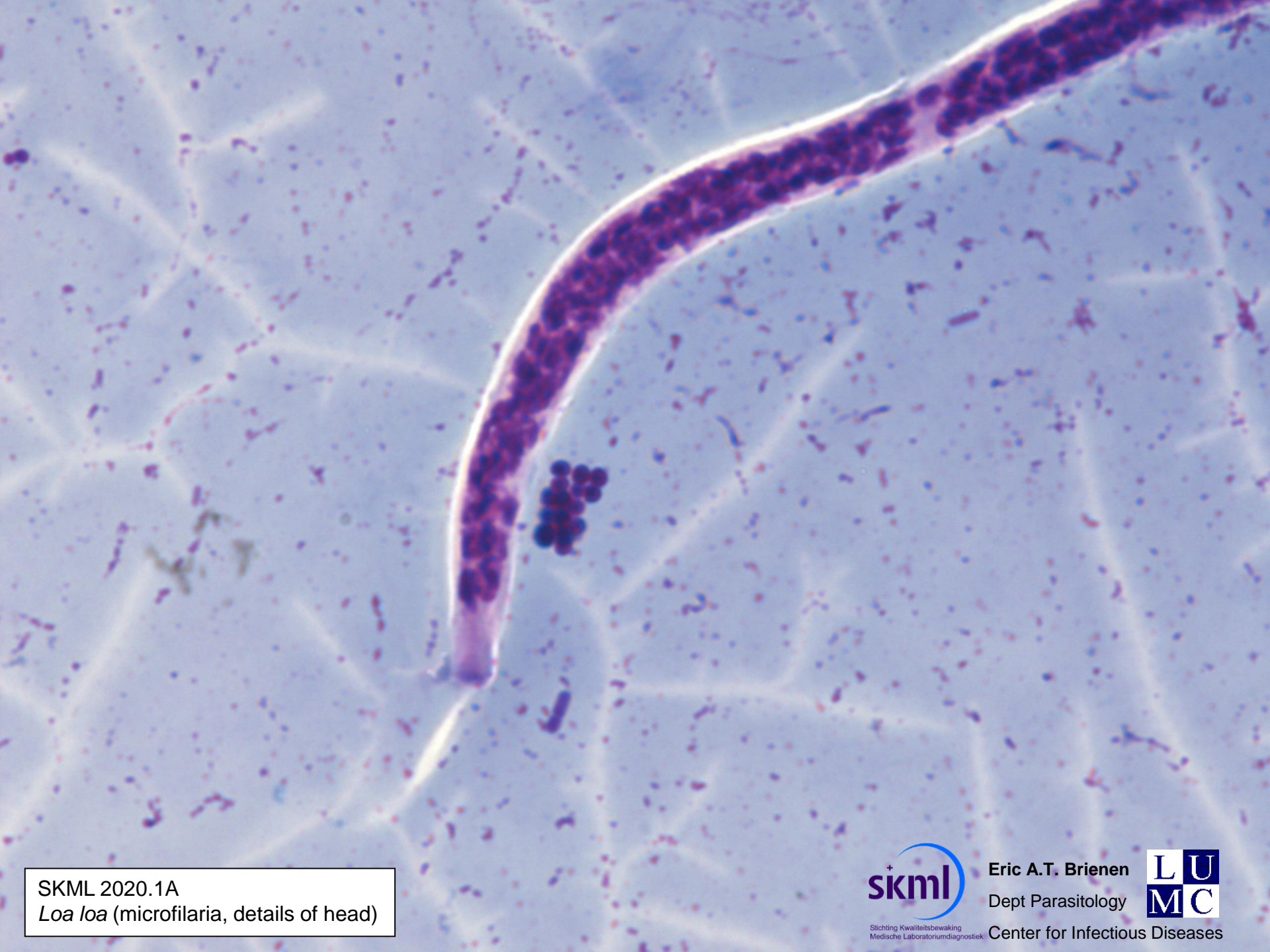


Stichting Kwaliteitsbewaking
Medische Laboratoriumdiagnostiek

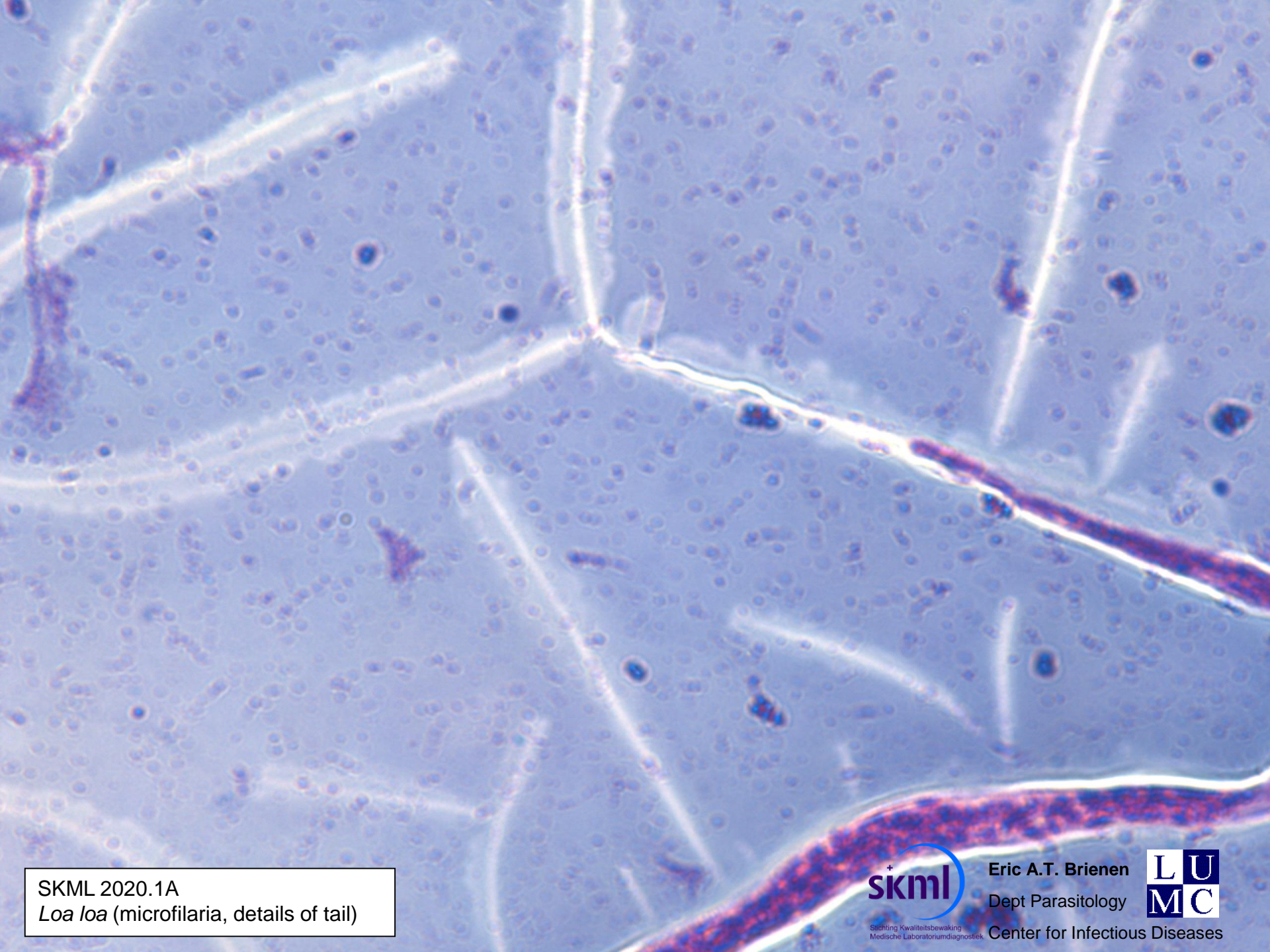
Eric A.T. Brienen
Dept Parasitology



Center for Infectious Diseases



SKML 2020.1A
Loa loa (microfilaria, details of head)



SKML 2020.1A
Loa loa (microfilaria, details of tail)

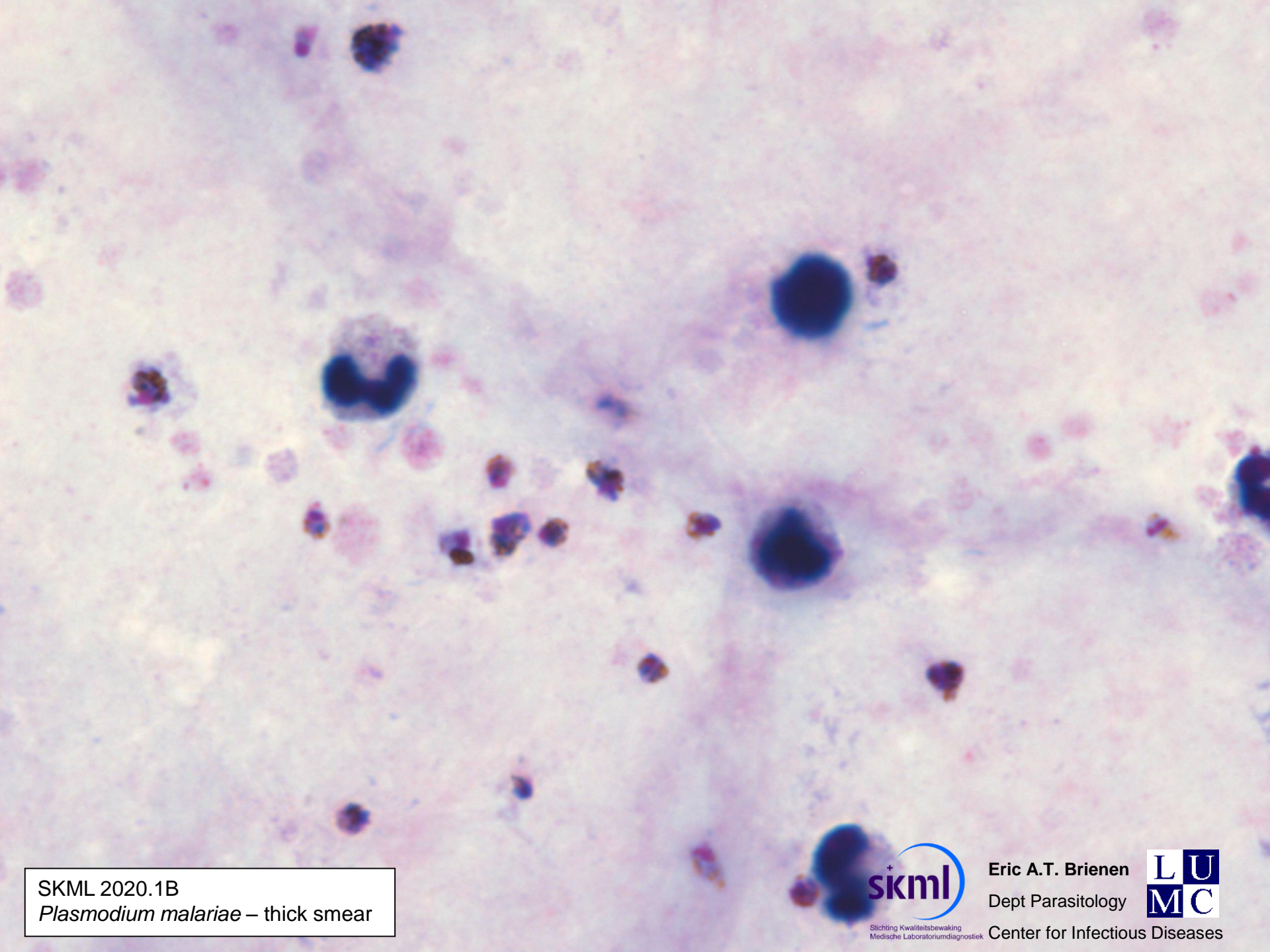


Stichting Kwaliteitsbewaking
Medische Laboratoriumdiagnostiek

Eric A.T. Brienen
Dept Parasitology



Center for Infectious Diseases



SKML 2020.1B

Plasmodium malariae – thick smear



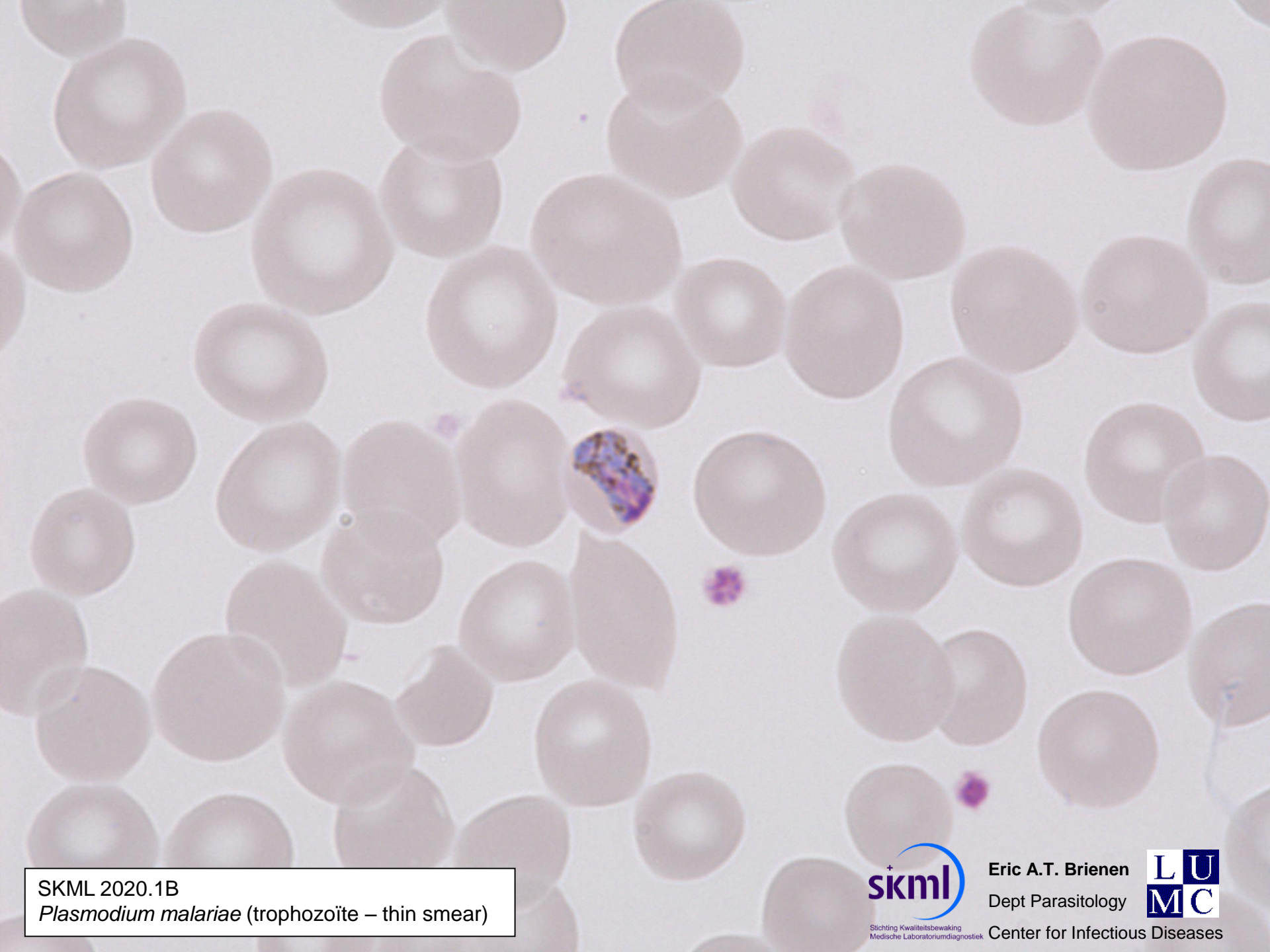Stichting Kwaliteitsbewaking
Medische Laboratoriumdiagnostiek

Eric A.T. Brienen

Dept Parasitology



Center for Infectious Diseases



SKML 2020.1B

Plasmodium malariae (trophozoïte – thin smear)



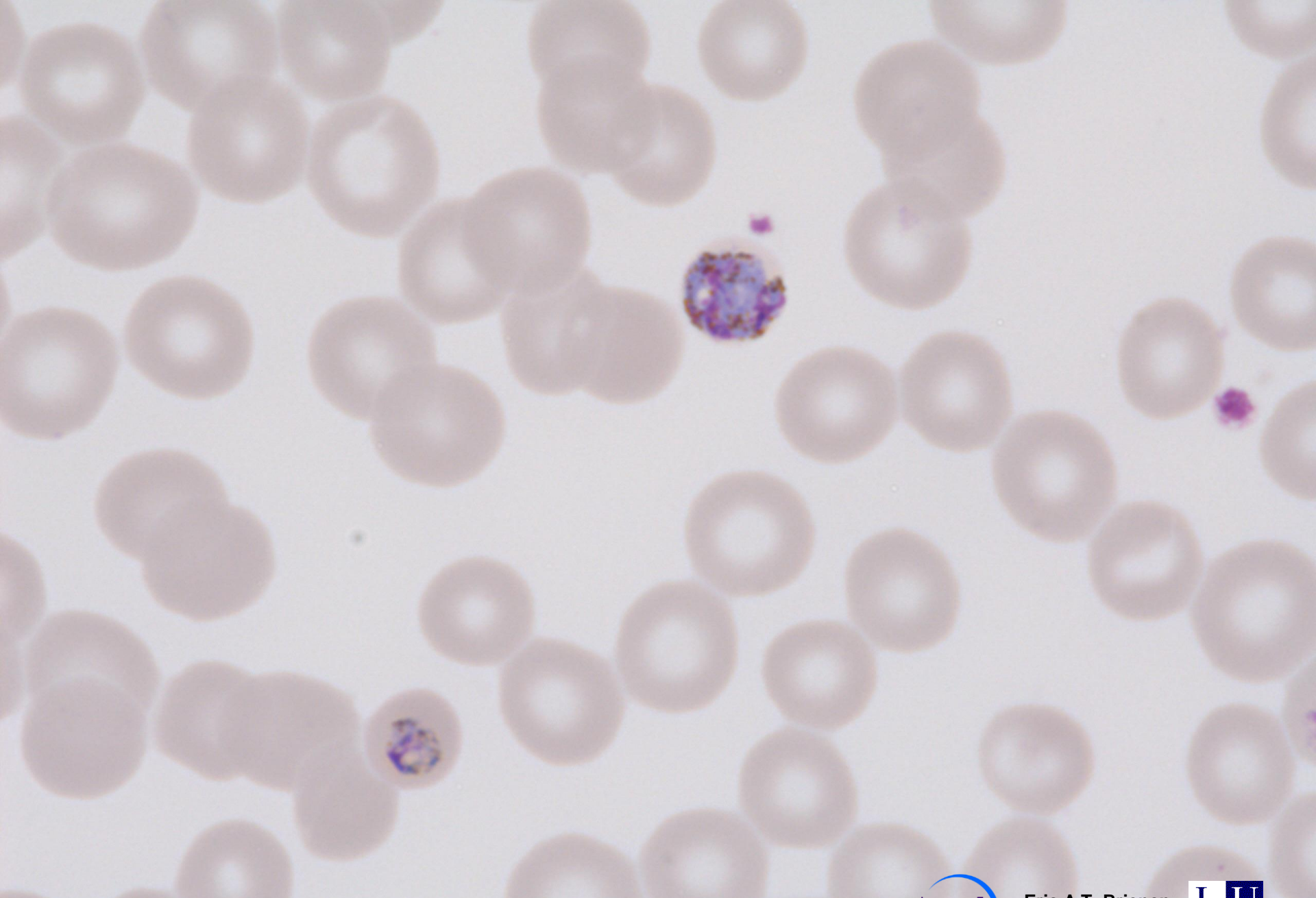
Stichting Kwaliteitsbewaking
Medische Laboratoriumdiagnostiek

Eric A.T. Brienen

Dept Parasitology

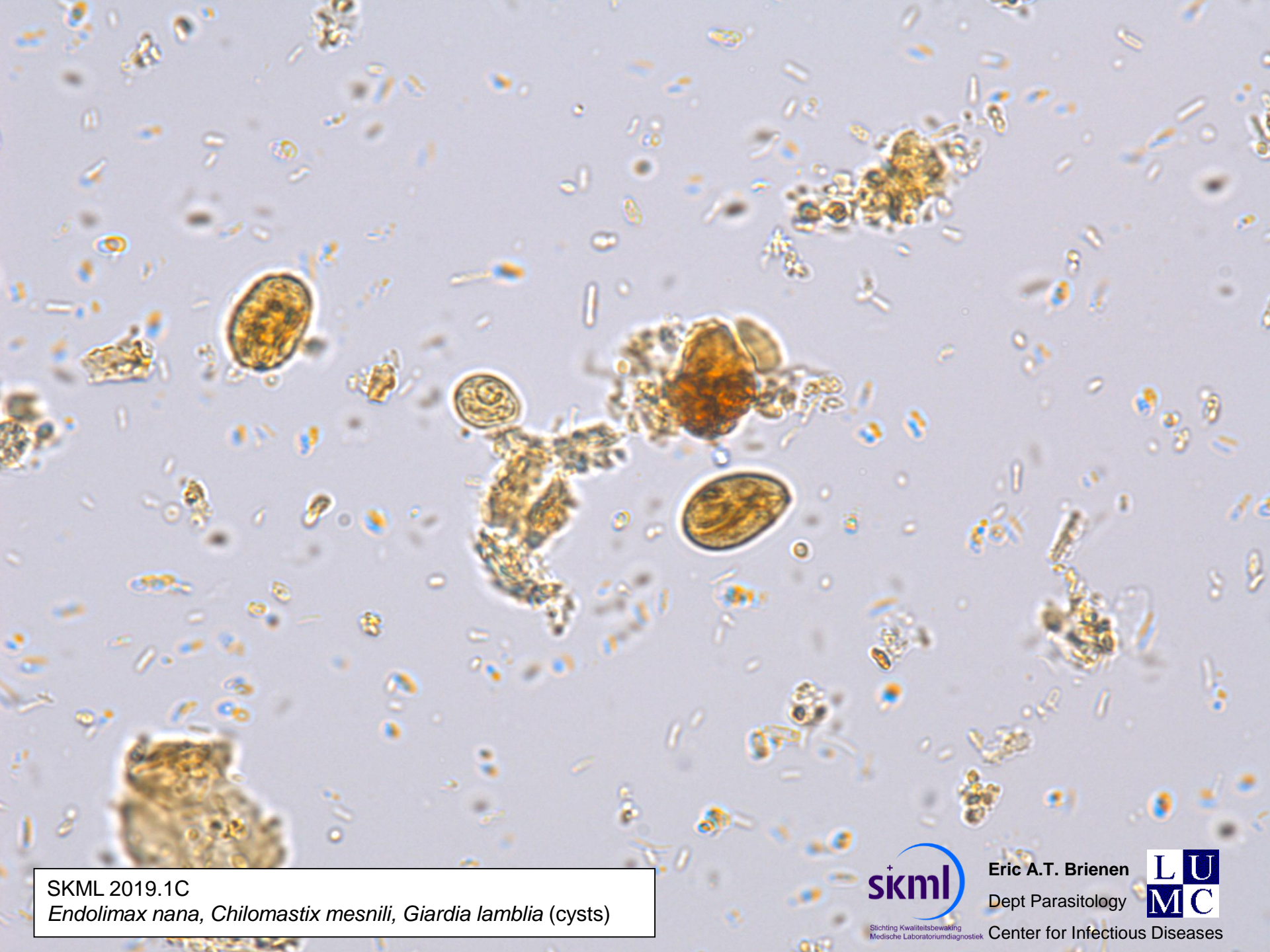


Center for Infectious Diseases



SKML 2020.1B

Plasmodium malariae (trophozoïte, gametocyte – thin smear)



SKML 2019.1C

Endolimax nana, *Chilomastix mesnili*, *Giardia lamblia* (cysts)




Stichting Kwaliteitsbewaking
Medische Laboratoriumdiagnostiek

Eric A.T. Brienens

Dept Parasitology



Center for Infectious Diseases



SKML 2019.1C
Dientamoeba fragilis (trophozoïte)

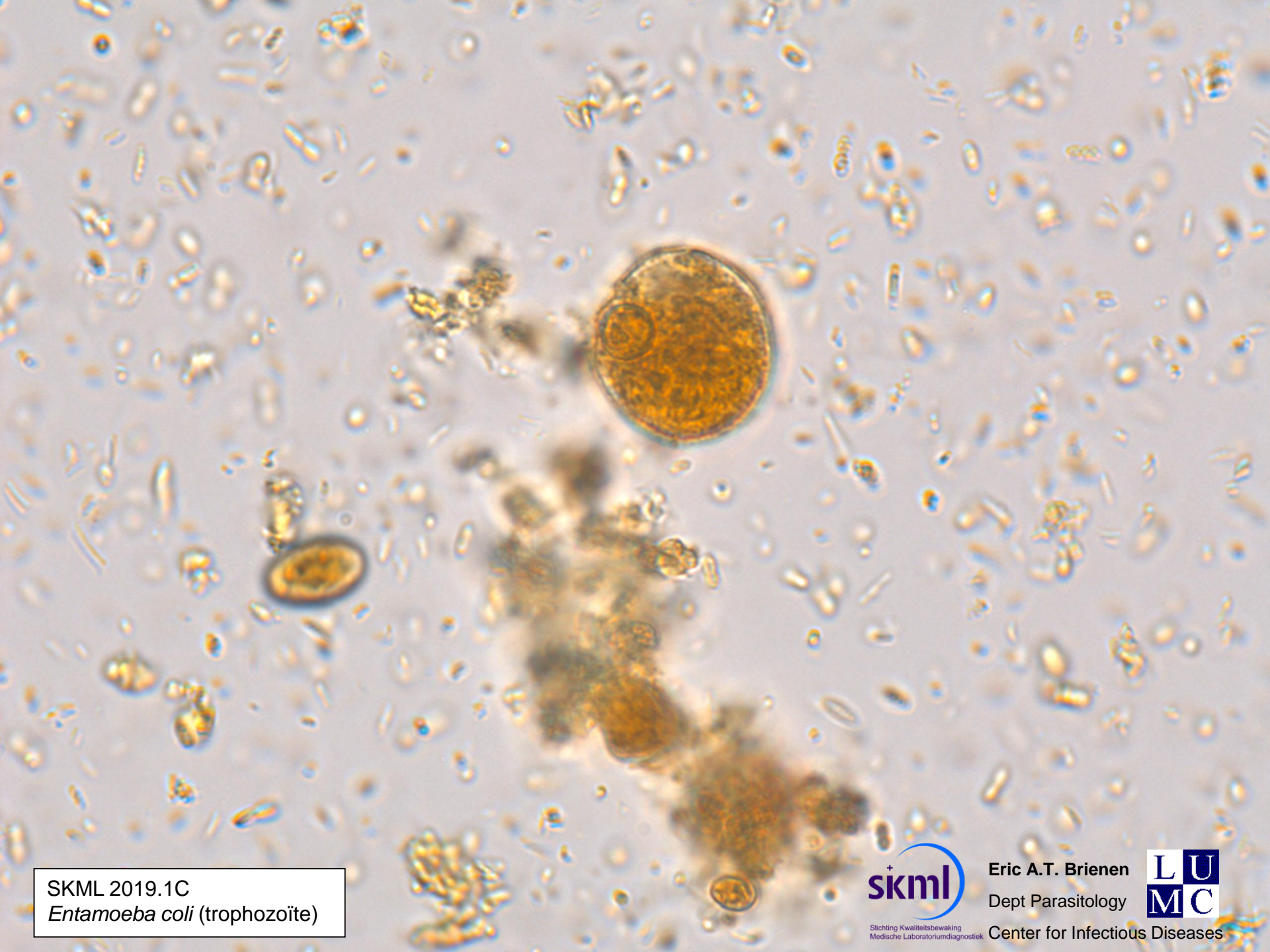


Stichting Kwaliteitsbewaking
Medische Laboratoriumdiagnostiek

Eric A.T. Brienens
Dept Parasitology



Center for Infectious Diseases



SKML 2019.1C
Entamoeba coli (trophozoïte)




Stichting Kwaliteitsbewaking
Medische Laboratoriumdiagnostiek

Eric A.T. Brienens
Dept Parasitology



Center for Infectious Diseases

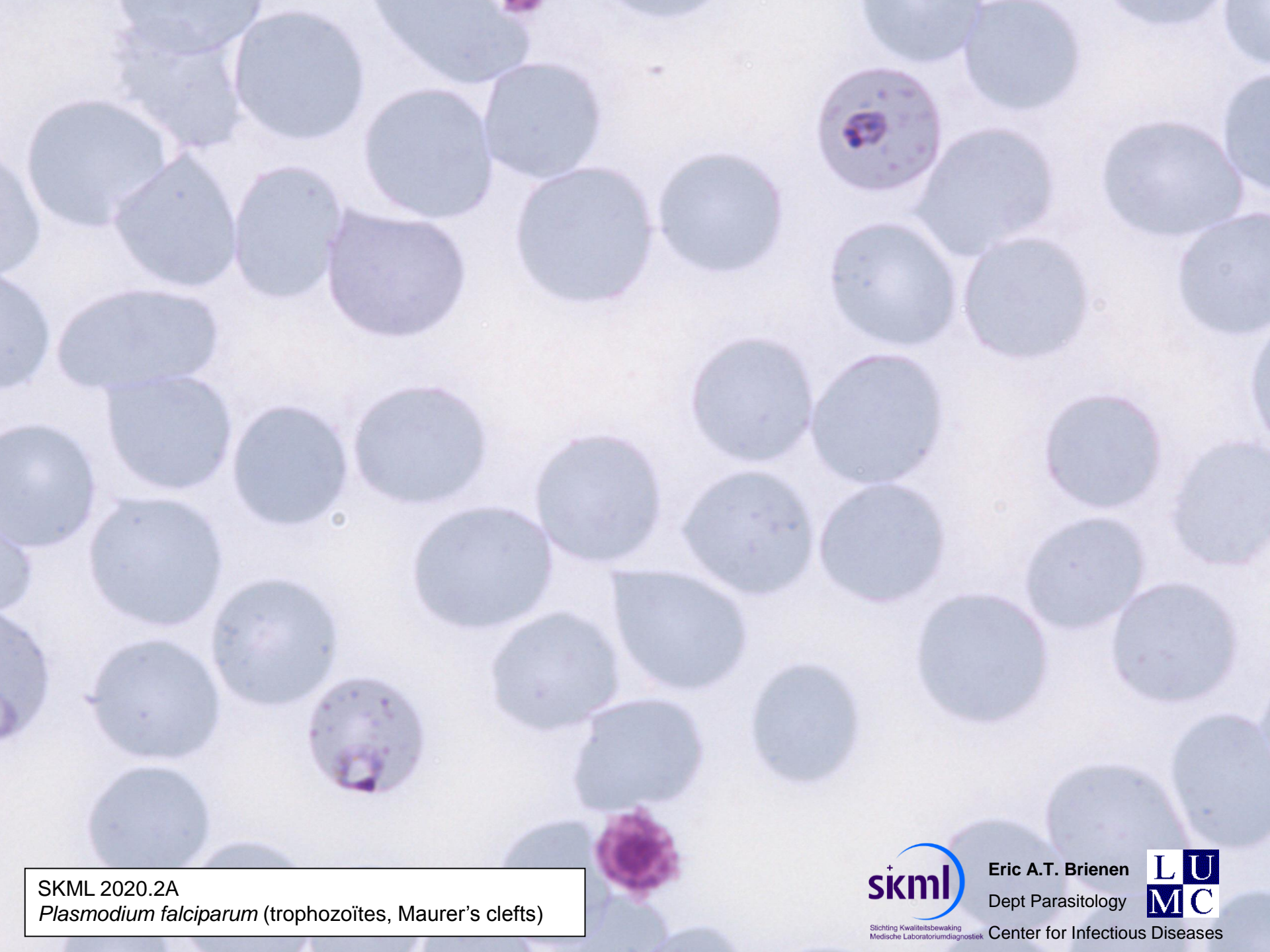


SKML 2020.1D
Schistosoma mansoni (egg)



Eric A.T. Brien
Dept Parasitology
Center for Infectious Diseases





SKML 2020.2A

Plasmodium falciparum (trophozoïtes, Maurer's clefts)



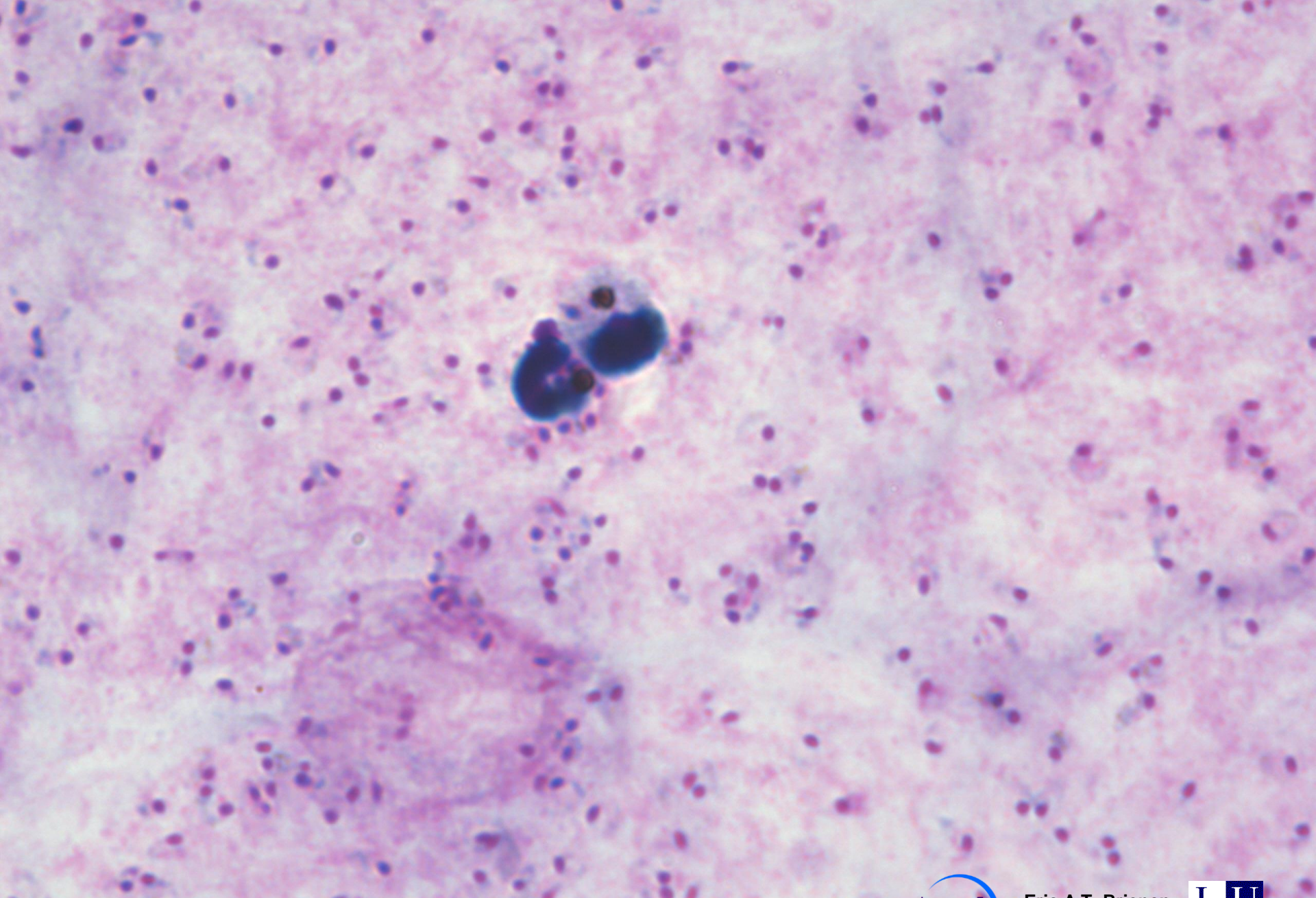
Stichting Kwaliteitsbewaking
Medische Laboratoriumdiagnostiek

Eric A.T. Brienen

Dept Parasitology



Center for Infectious Diseases



SKML 2020.2B

Plasmodium falciparum (trophozoïtes, pigment in leucocyte - thick smear)



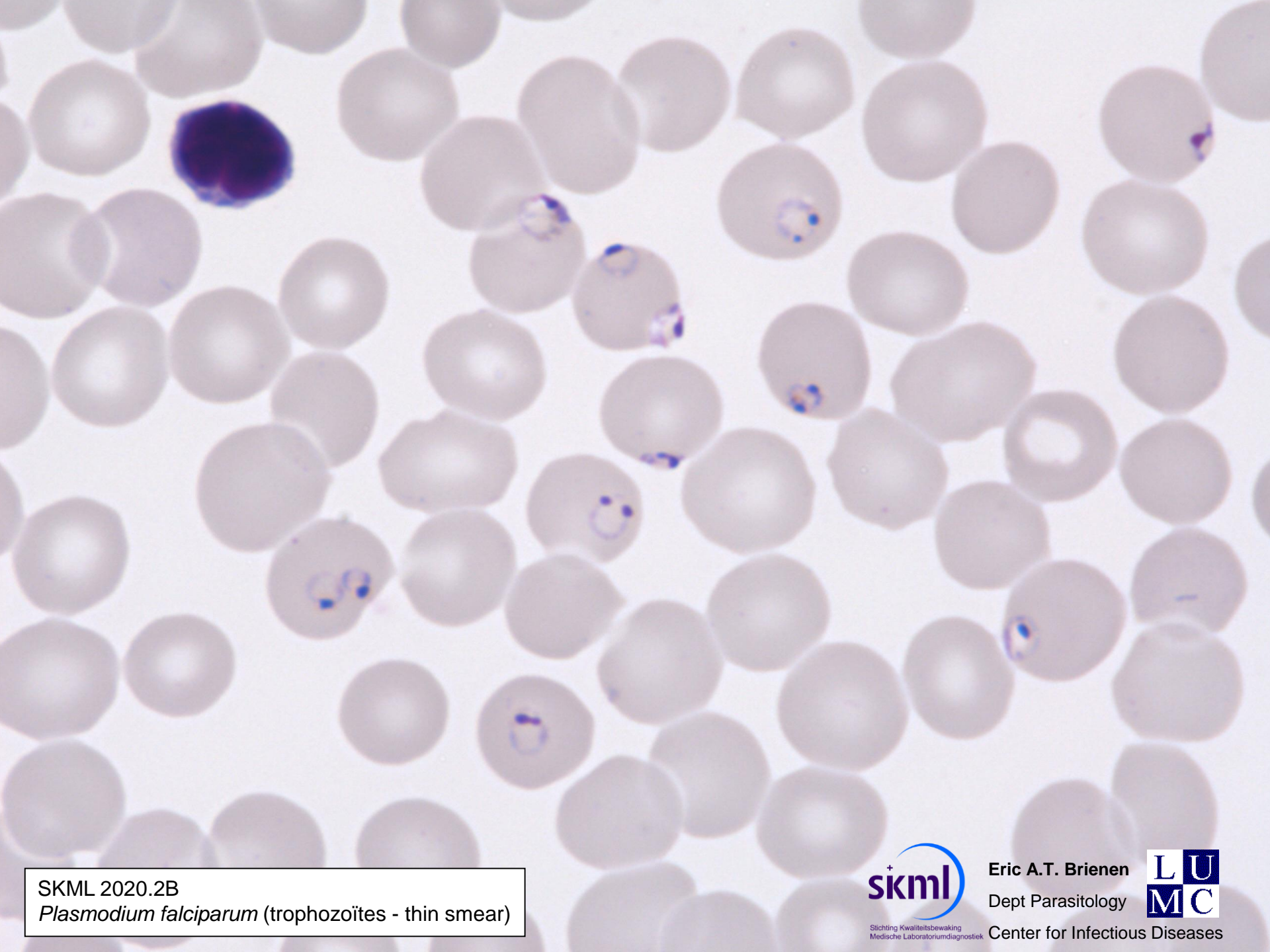Stichting Kwaliteitsbewaking
Medische Laboratoriumdiagnostiek

Eric A.T. Brienen

Dept Parasitology

Center for Infectious Diseases





SKML 2020.2B

Plasmodium falciparum (trophozoïtes - thin smear)



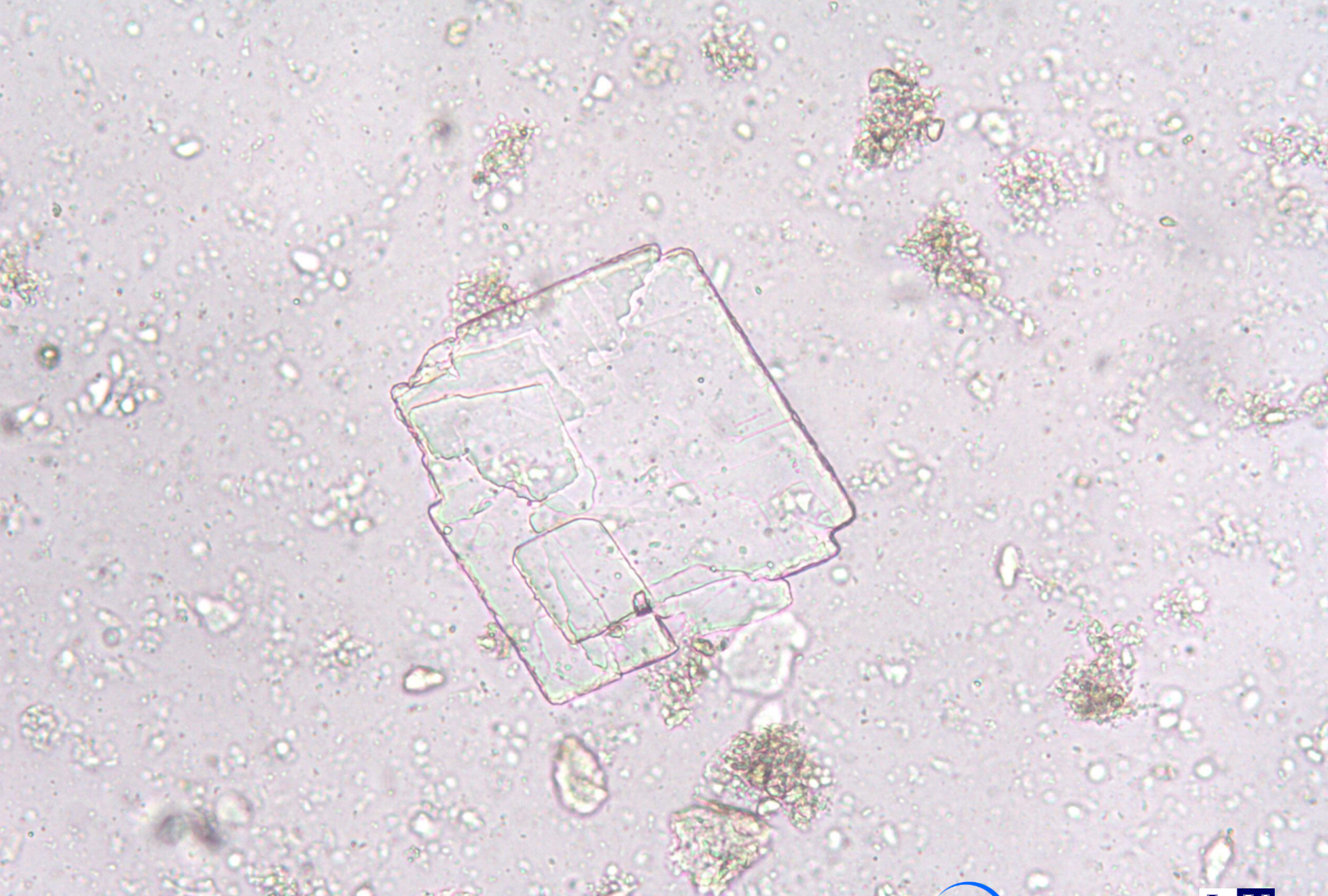
Stichting Kwaliteitsbewaking
Medische Laboratoriumdiagnostiek

Eric A.T. Brienens

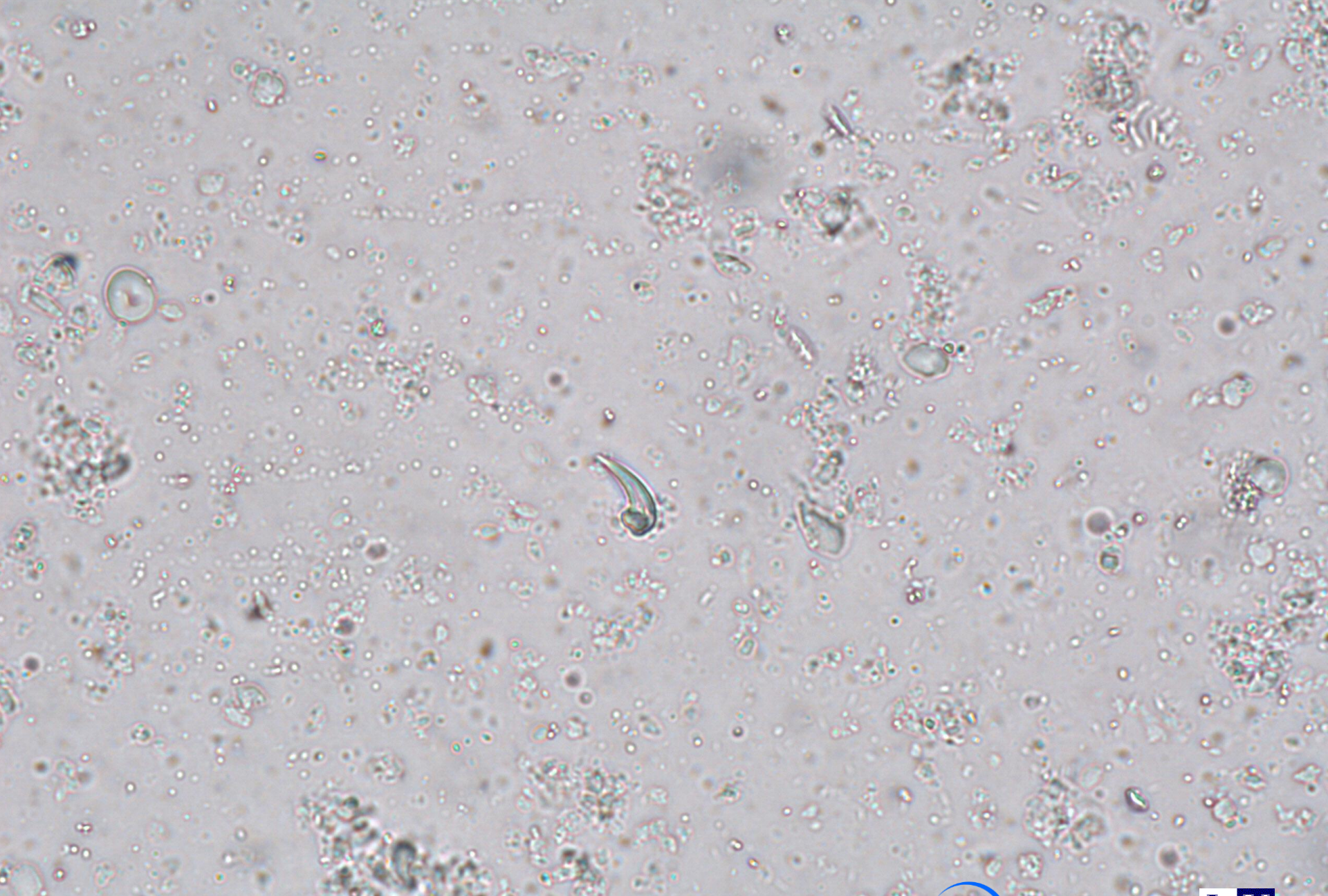
Dept Parasitology



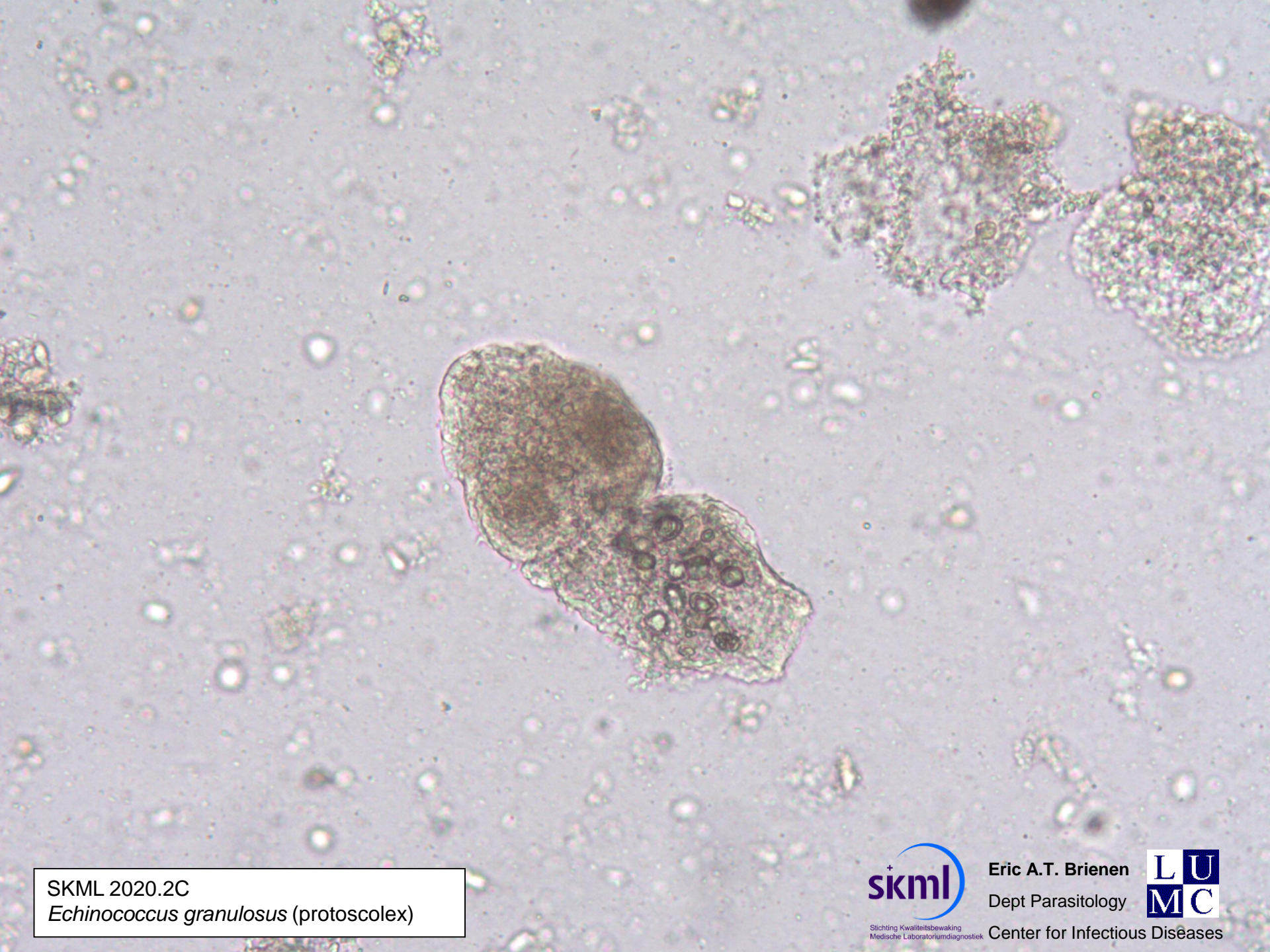Center for Infectious Diseases



SKML 2020.2C
Echinococcus granulosus (Hydatid sand, crystals in cyst fluid)



SKML 2020.2C
Echinococcus granulosus (Hooklet in cyst fluid)



SKML 2020.2C
Echinococcus granulosus (protoscolex)

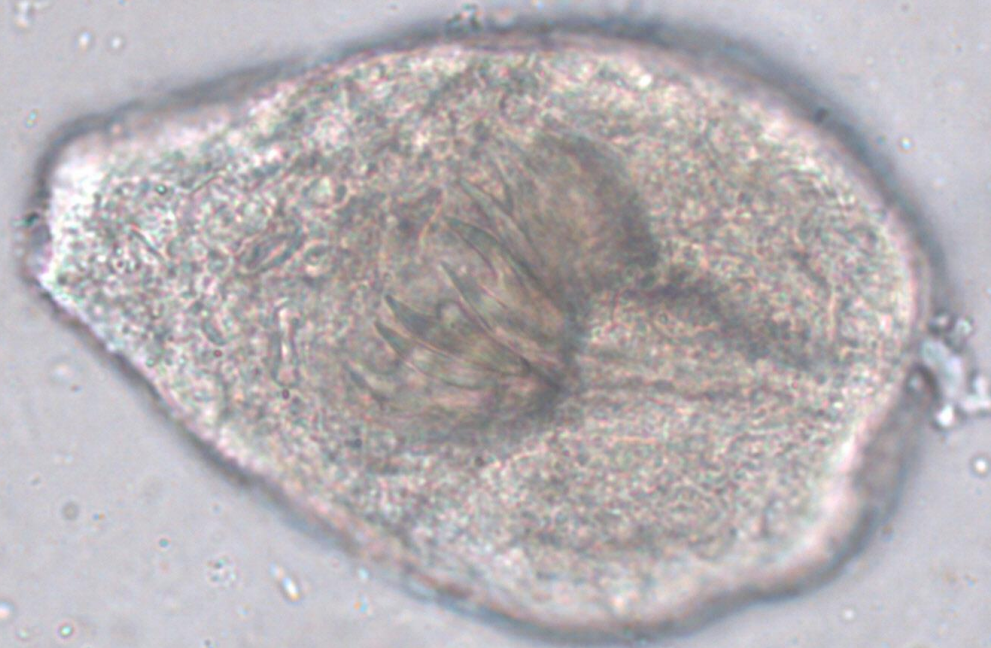

Stichting Kwaliteitsbewaking
Medische Laboratoriumdiagnostiek

Eric A.T. Brienens
Dept Parasitology



Center for Infectious Diseases



SKML 2020.2C
Echinococcus granulosus (protoscolex)

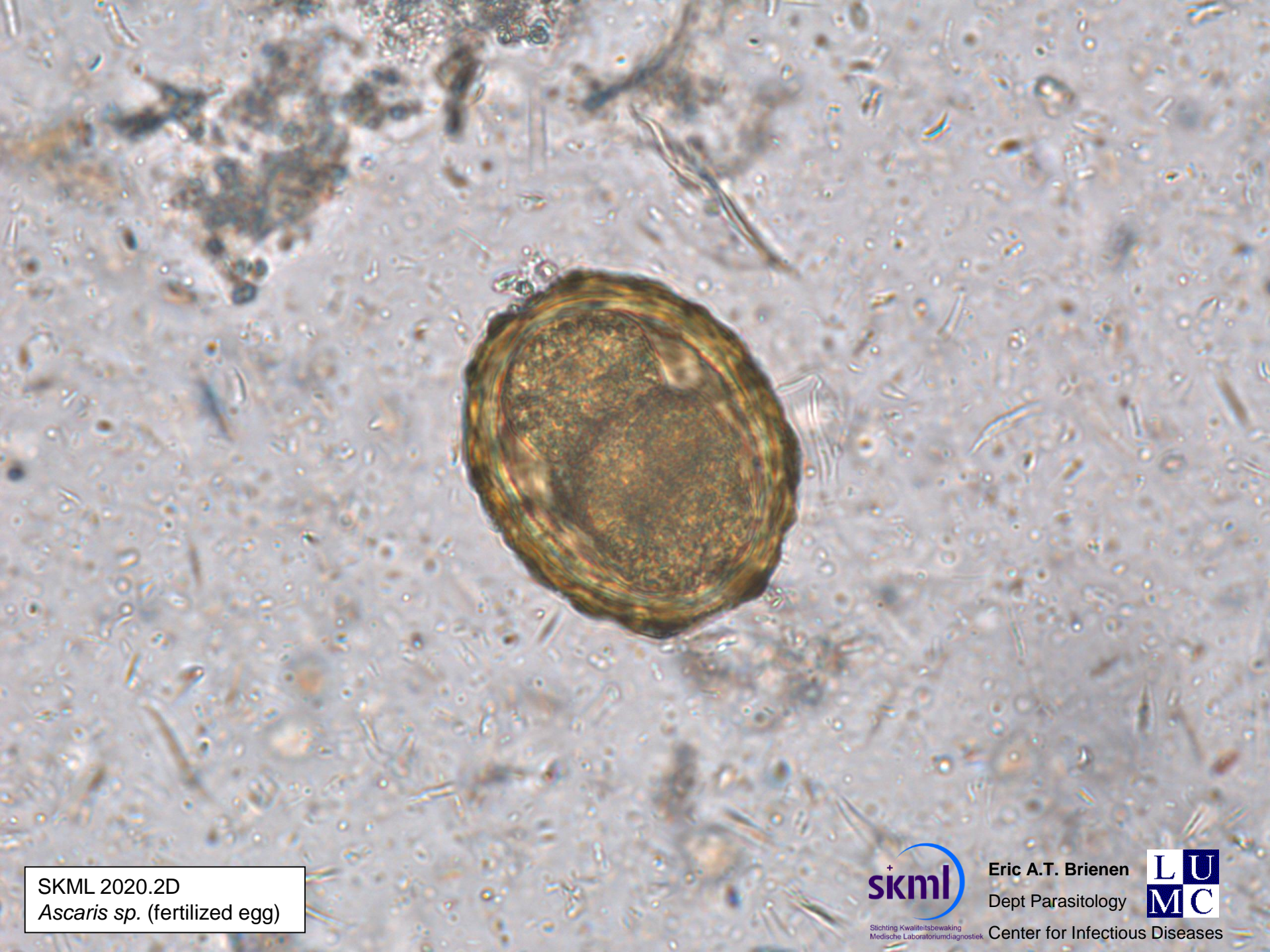

Stichting Kwaliteitsbewaking
Medische Laboratoriumdiagnostiek

Eric A.T. Brienen
Dept Parasitology



Center for Infectious Diseases



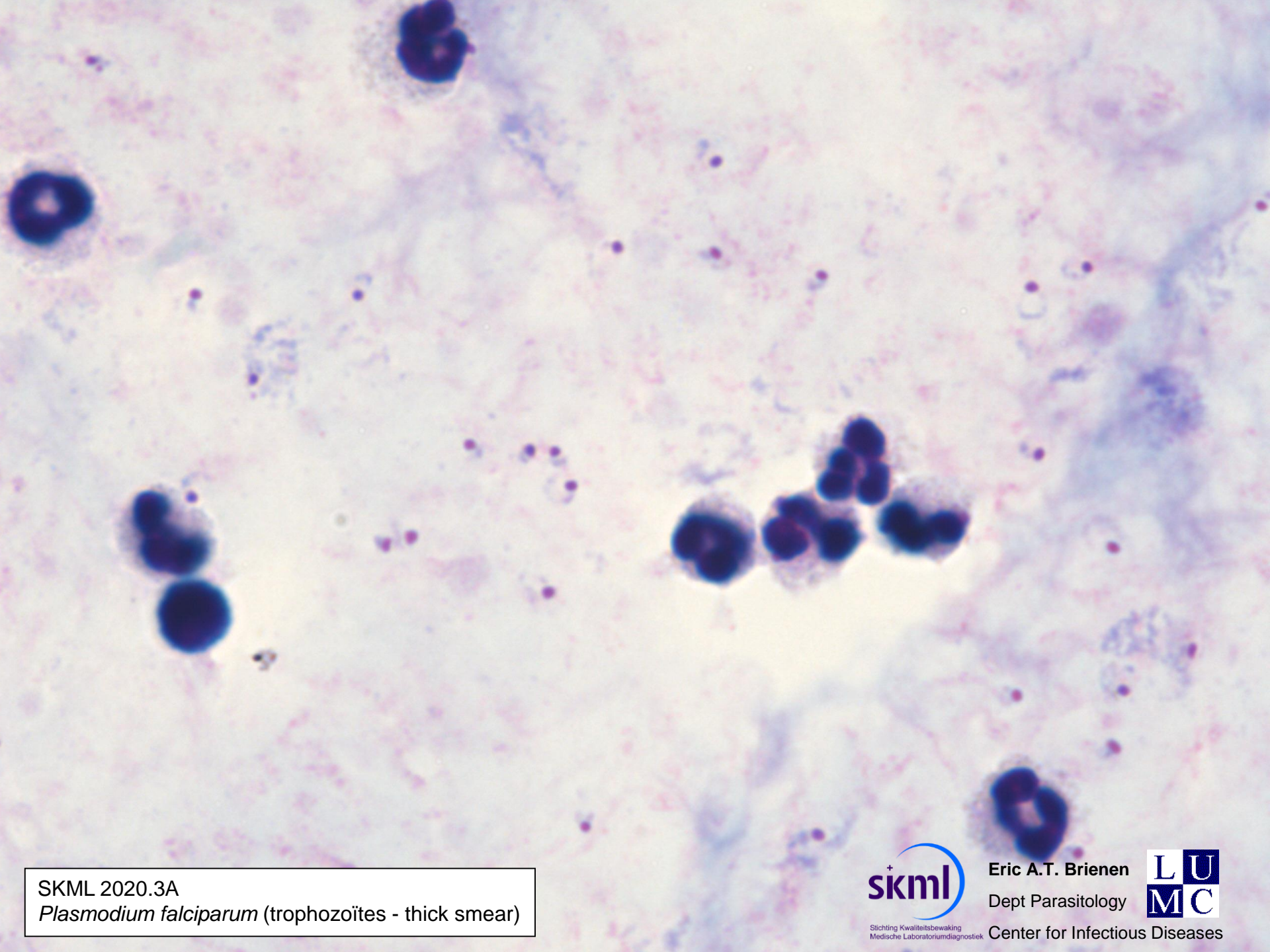
SKML 2020.2D
Ascaris sp. (fertilized egg)



Eric A.T. Brienen
Dept Parasitology



Center for Infectious Diseases



SKML 2020.3A
Plasmodium falciparum (trophozoïtes - thick smear)

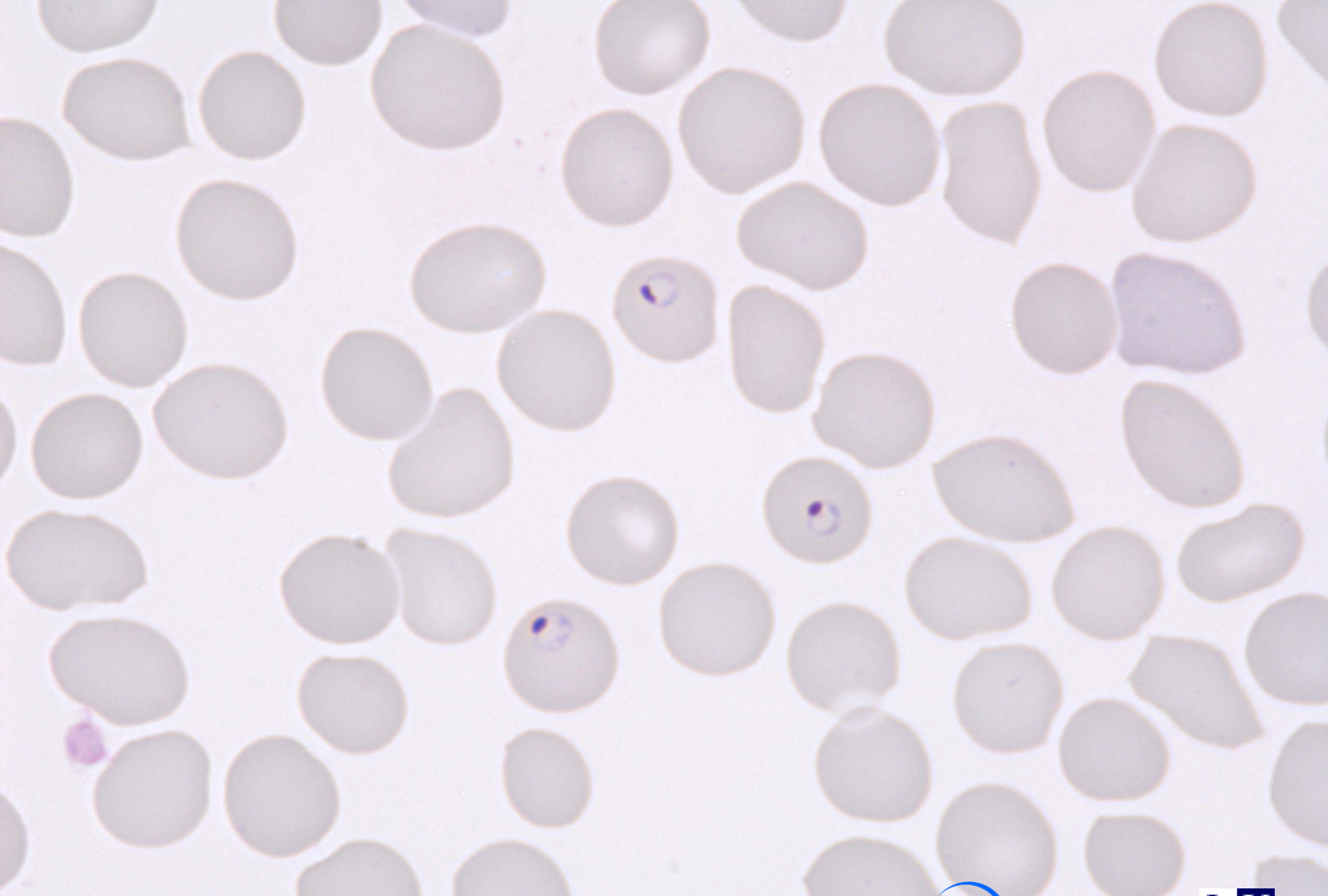


Stichting Kwaliteitsbewaking
Medische Laboratoriumdiagnostiek

Eric A.T. Brienens
Dept Parasitology



Center for Infectious Diseases



SKML 2020.3A
Plasmodium falciparum (trophozoïtes - thin smear)

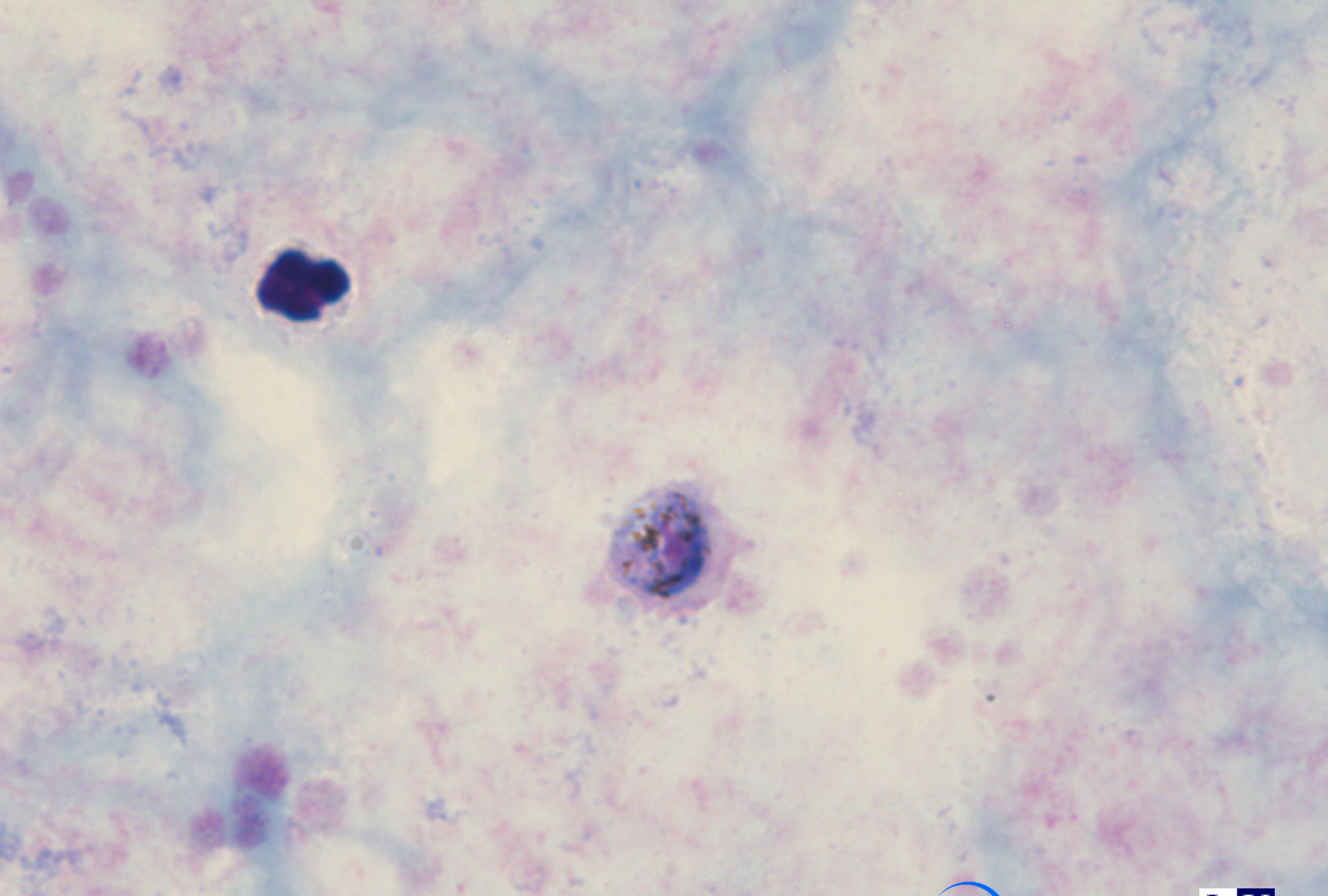


Stichting Kwaliteitsbewaking
Medische Laboratoriumdiagnostiek

Eric A.T. Brienens
Dept Parasitology



Center for Infectious Diseases



SKML 2020.3B

Plasmodium vivax (gametocyte - thick smear)



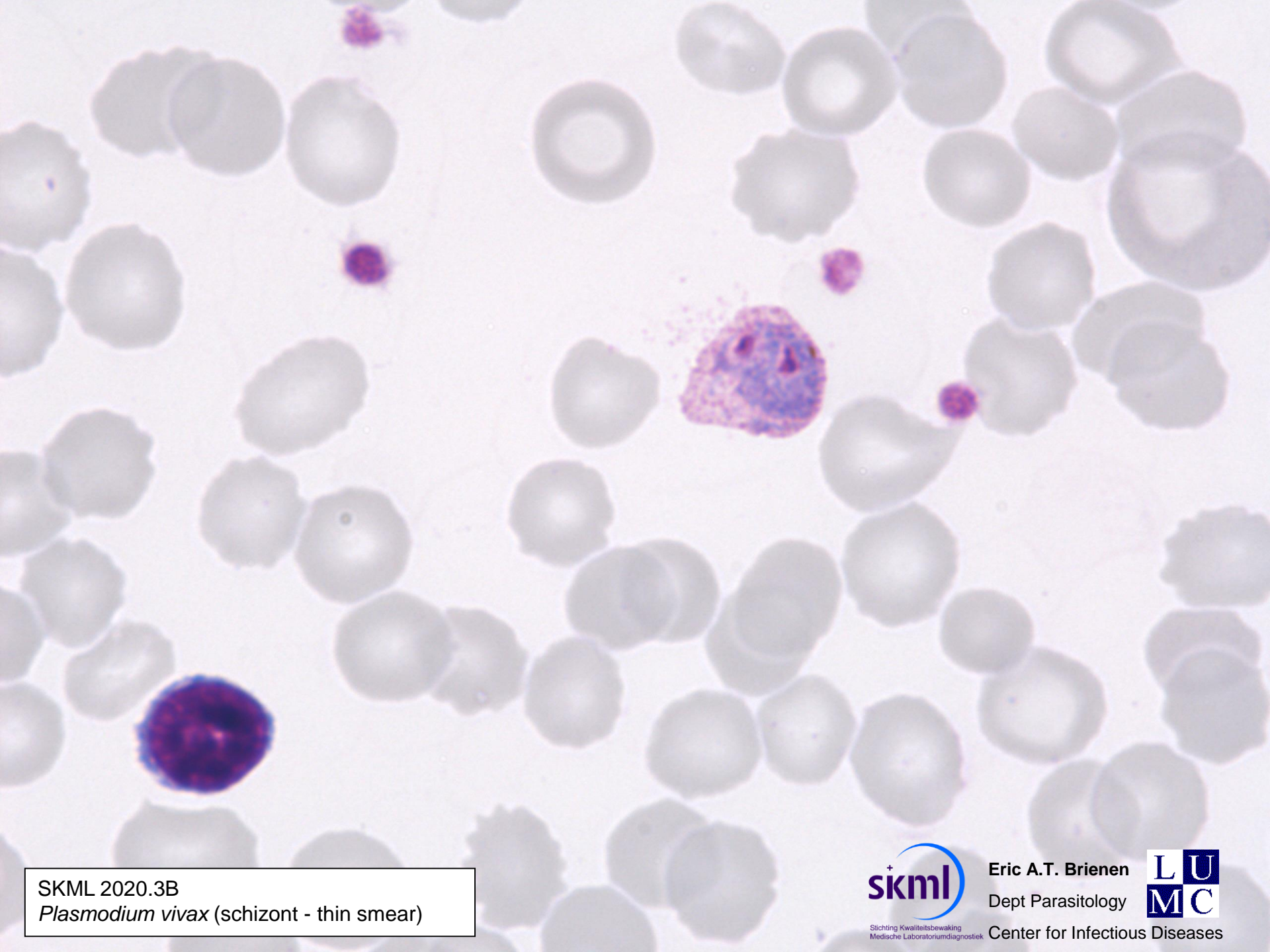
Stichting Kwaliteitsbewaking
Medische Laboratoriumdiagnostiek

Eric A.T. Brienens

Dept Parasitology



Center for Infectious Diseases



SKML 2020.3B

Plasmodium vivax (schizont - thin smear)



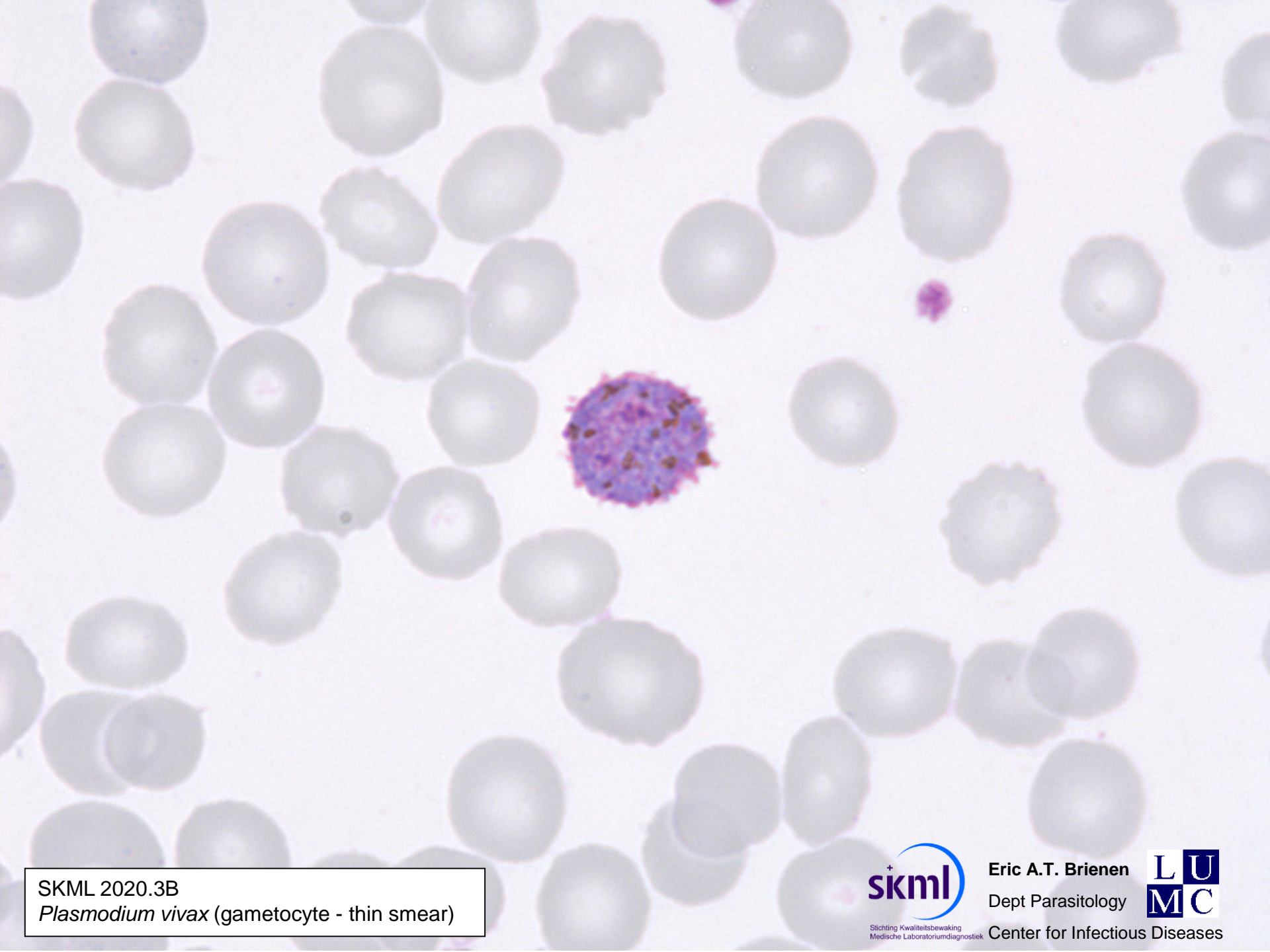
Stichting Kwaliteitsbewaking
Medische Laboratoriumdiagnostiek

Eric A.T. Brienen

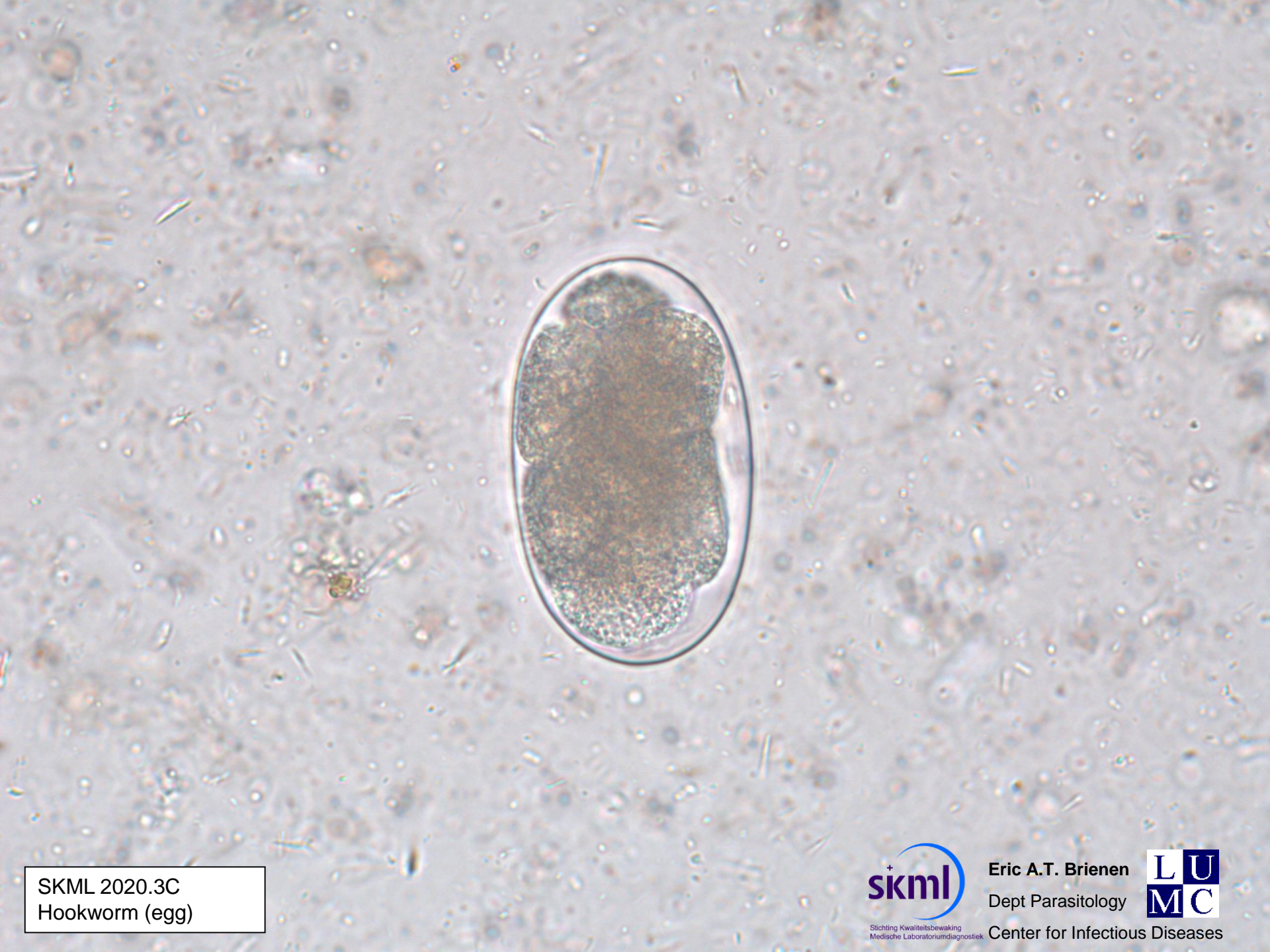Dept Parasitology



Center for Infectious Diseases



SKML 2020.3B
Plasmodium vivax (gametocyte - thin smear)



SKML 2020.3C
Hookworm (egg)

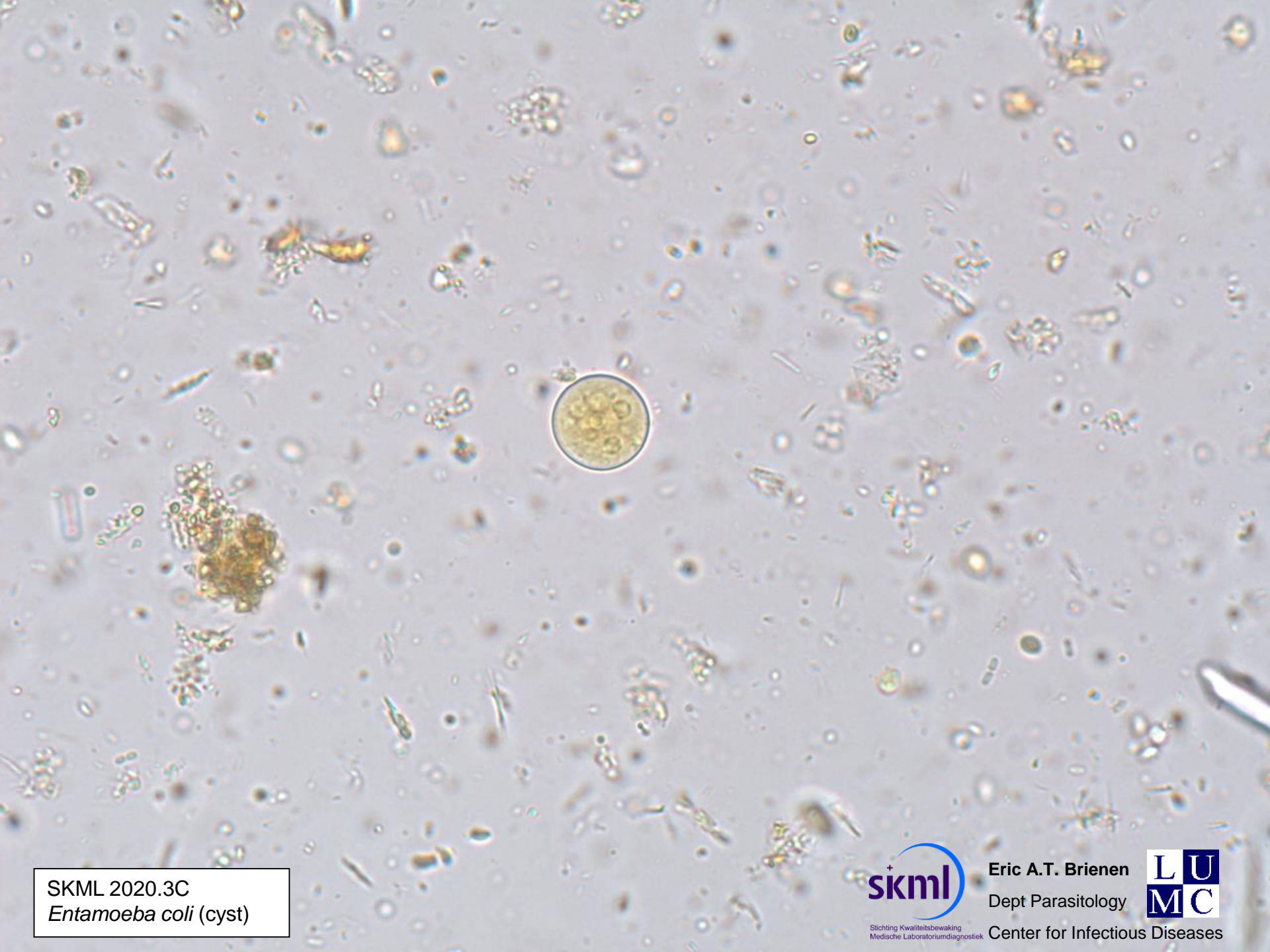


Stichting Kwaliteitsbewaking
Medische Laboratoriumdiagnostiek

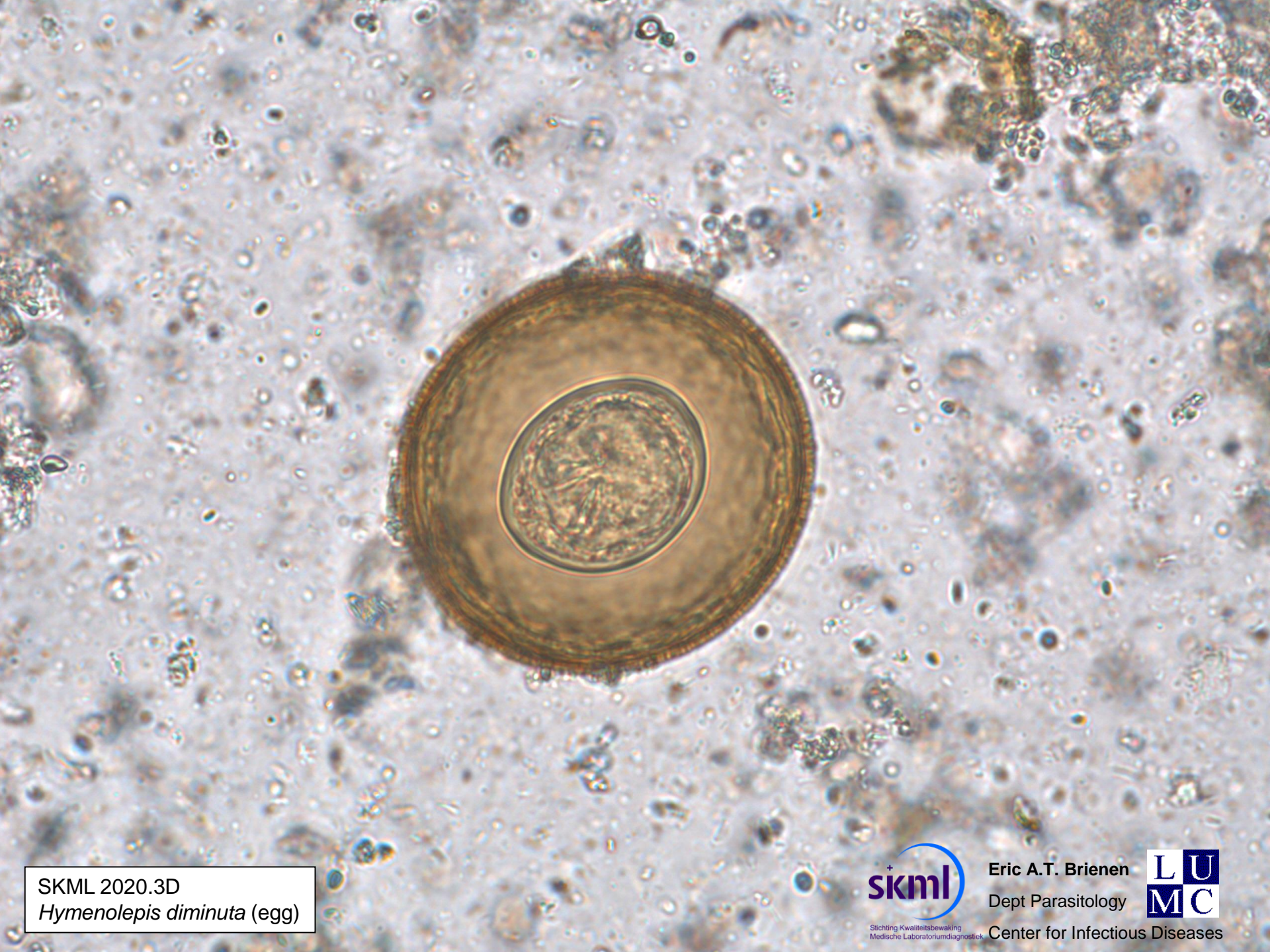Eric A.T. Brienen
Dept Parasitology



Center for Infectious Diseases



SKML 2020.3C
Entamoeba coli (cyst)



SKML 2020.3D
Hymenolepis diminuta (egg)

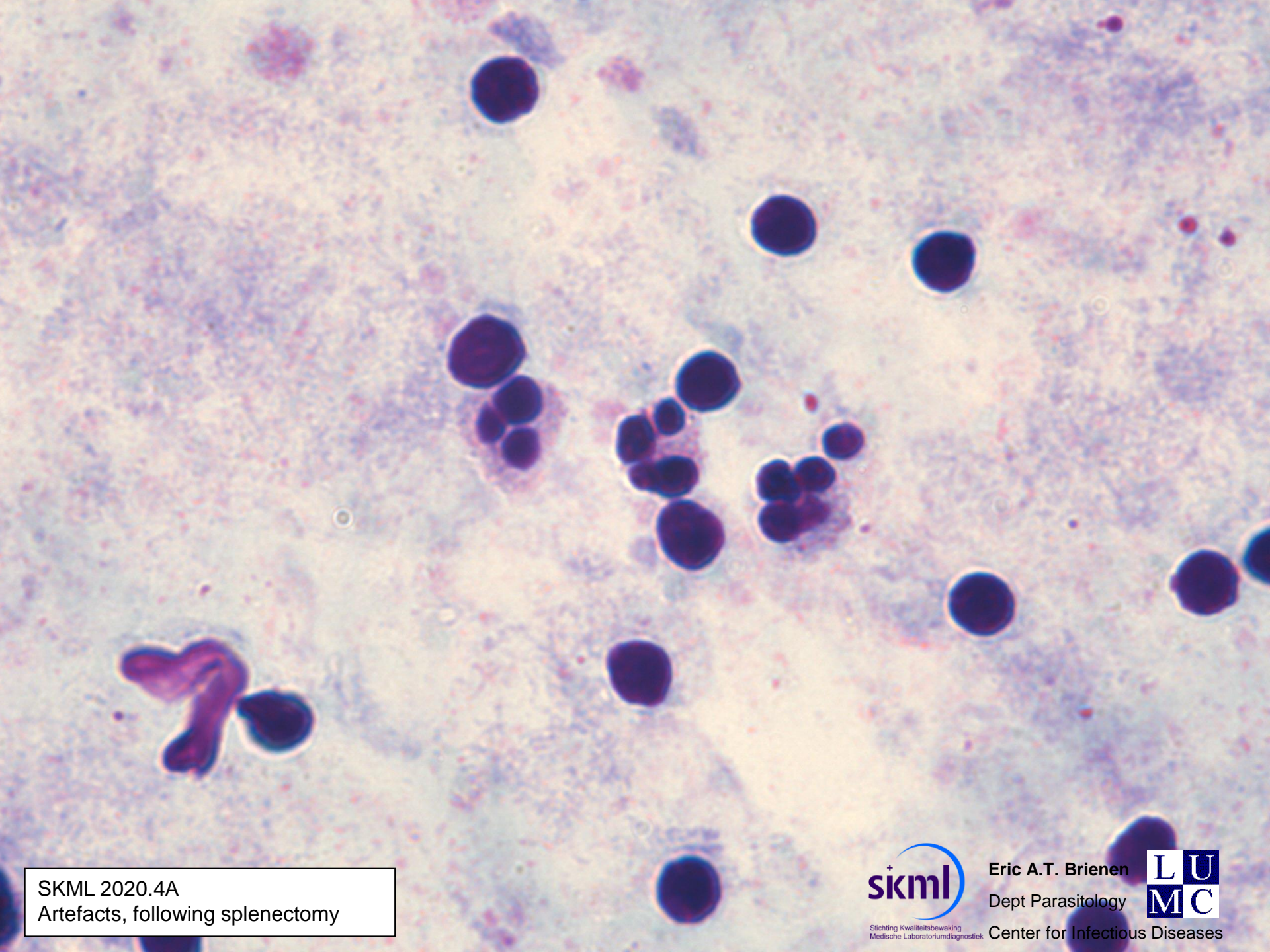


Stichting Kwaliteitsbewaking
Medische Laboratoriumdiagnostiek

Eric A.T. Brienen
Dept Parasitology



Center for Infectious Diseases



SKML 2020.4A
Artefacts, following splenectomy

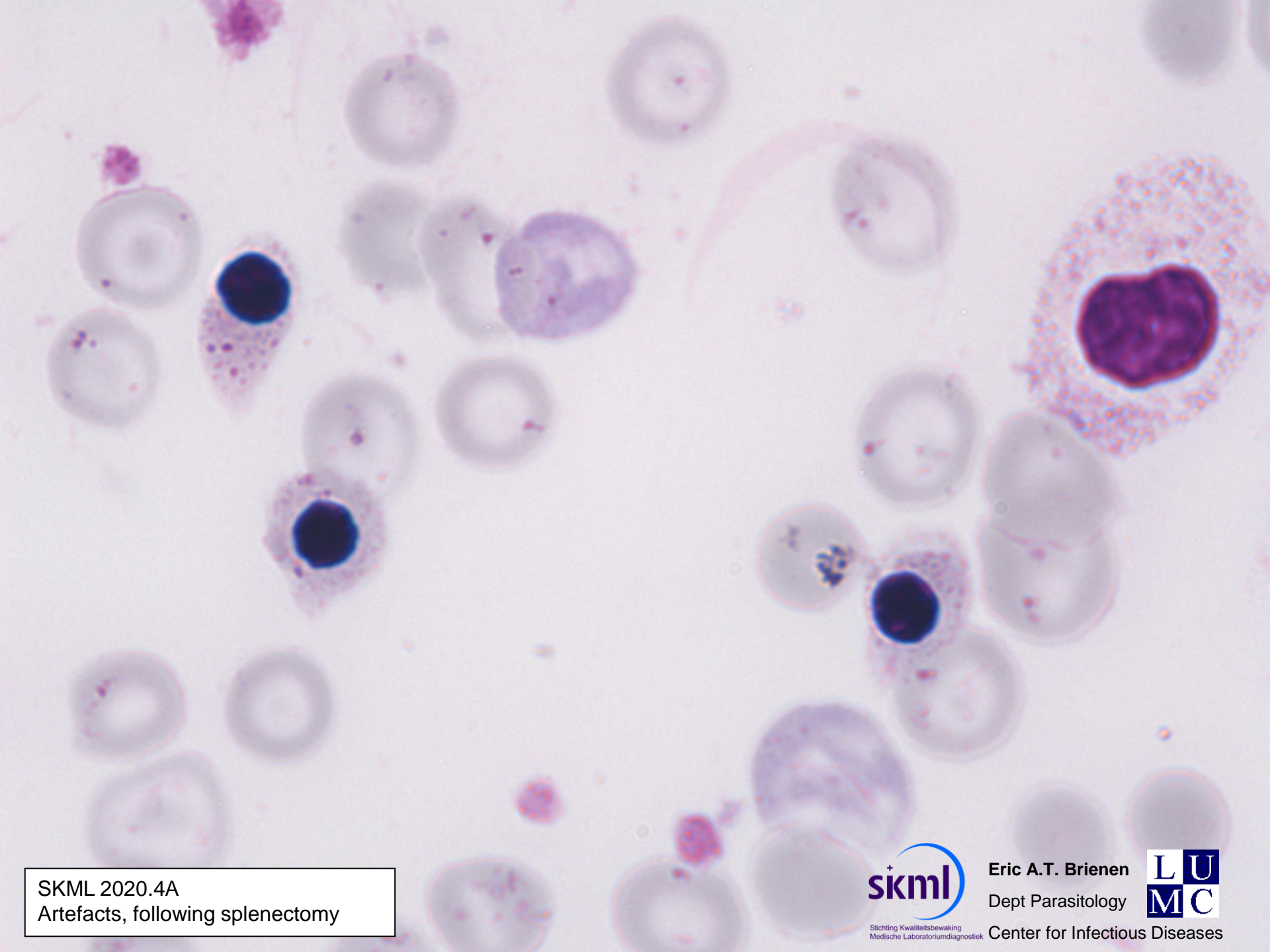


Stichting Kwaliteitsbewaking
Medische Laboratoriumdiagnostiek

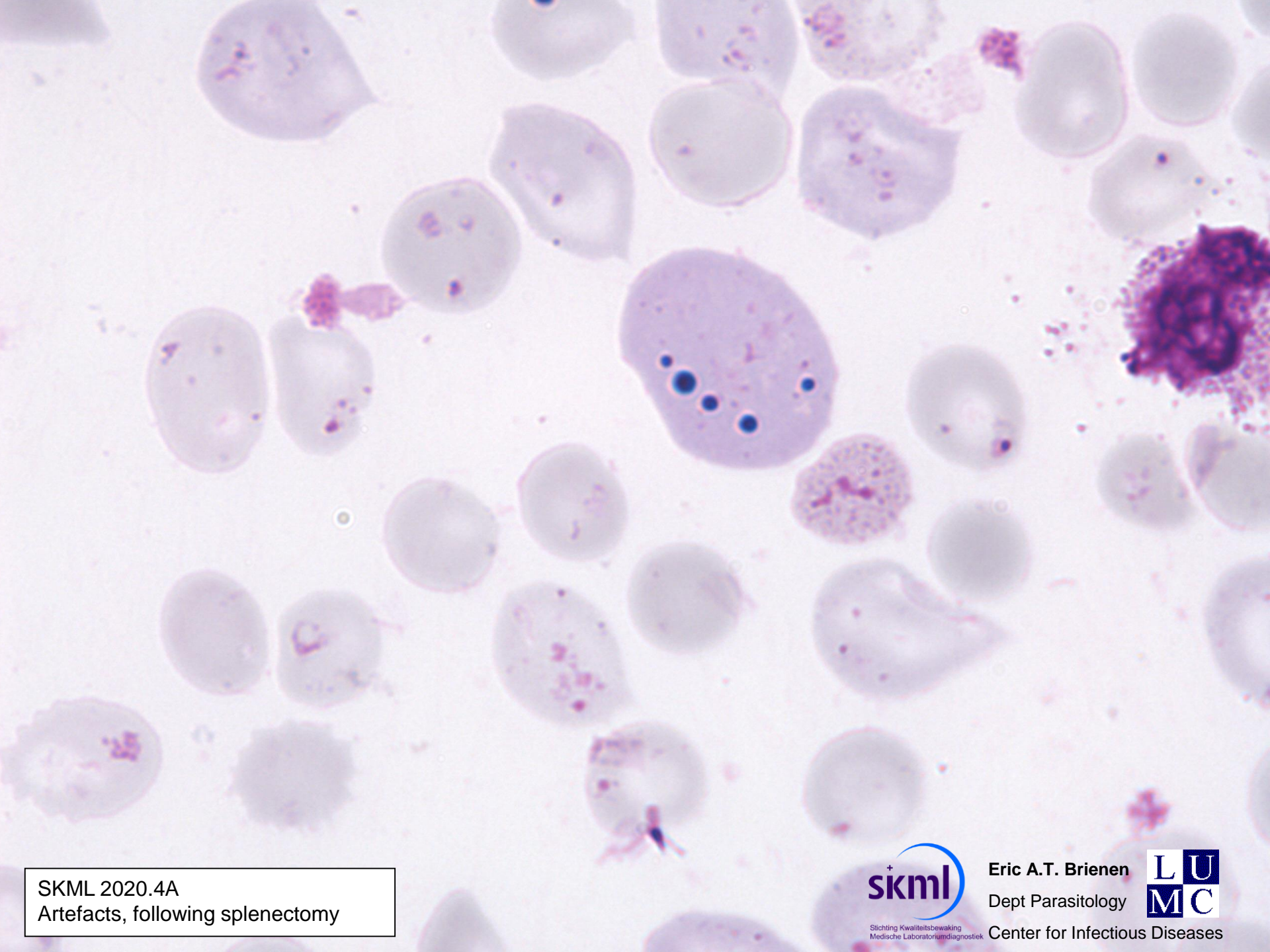
Eric A.T. Brienen
Dept Parasitology



Center for Infectious Diseases



SKML 2020.4A
Artefacts, following splenectomy



SKML 2020.4A
Artefacts, following splenectomy

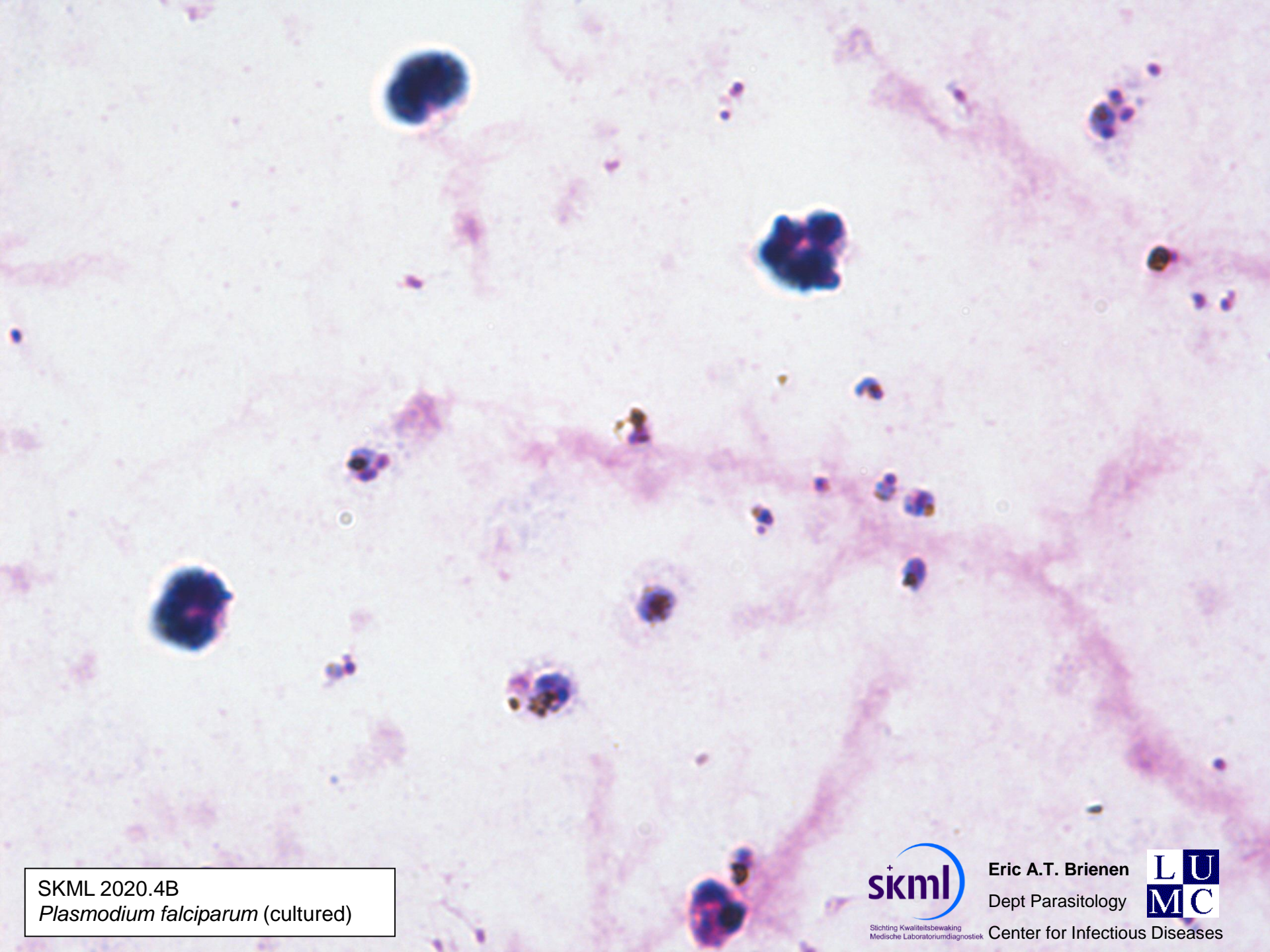


Stichting Kwaliteitsbewaking
Medische Laboratoriumdiagnostiek

Eric A.T. Brienen
Dept Parasitology



Center for Infectious Diseases



SKML 2020.4B
Plasmodium falciparum (cultured)

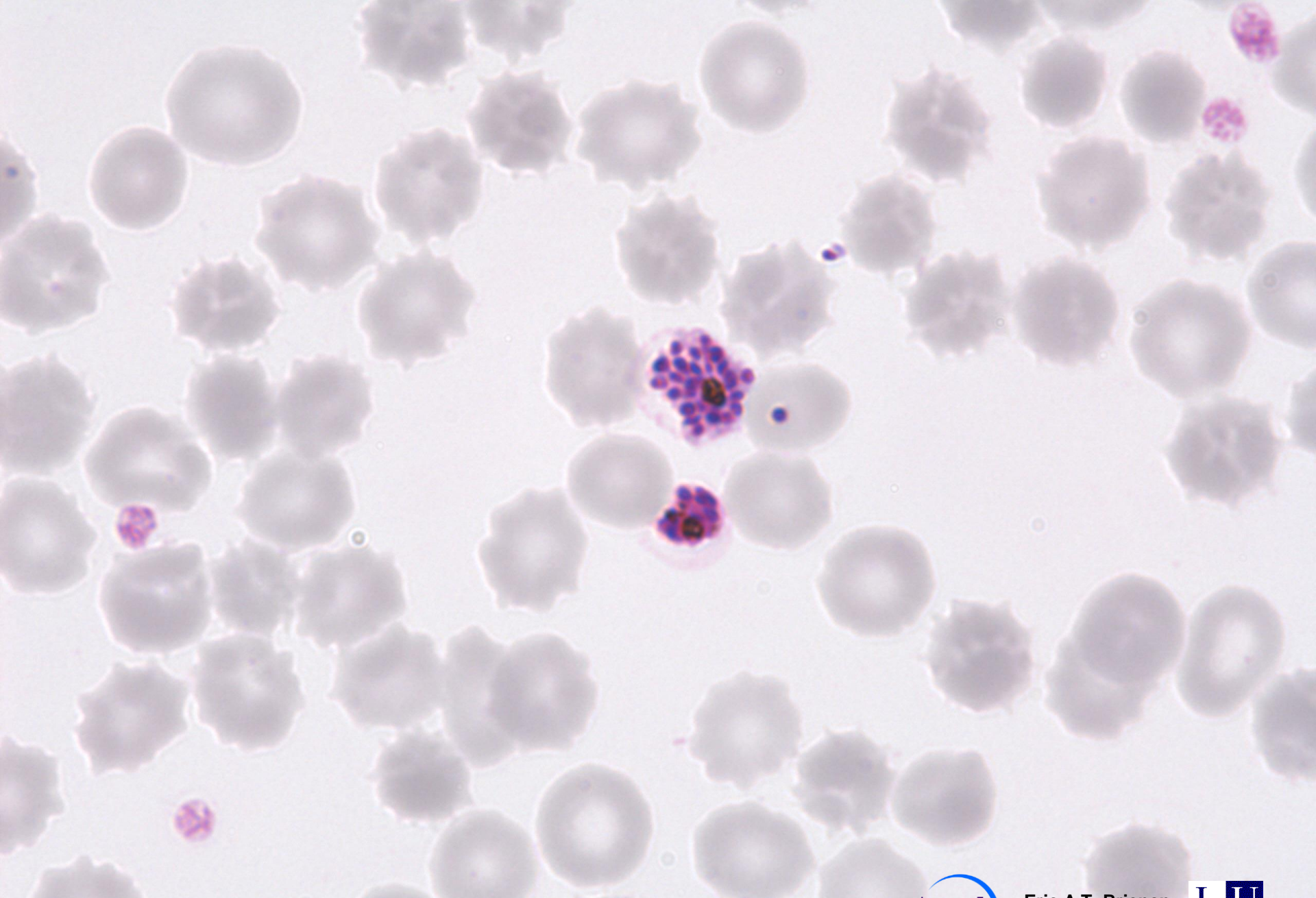


Stichting Kwaliteitsbewaking
Medische Laboratoriumdiagnostiek

Eric A.T. Brienen
Dept Parasitology



Center for Infectious Diseases



SKML 2020.4B

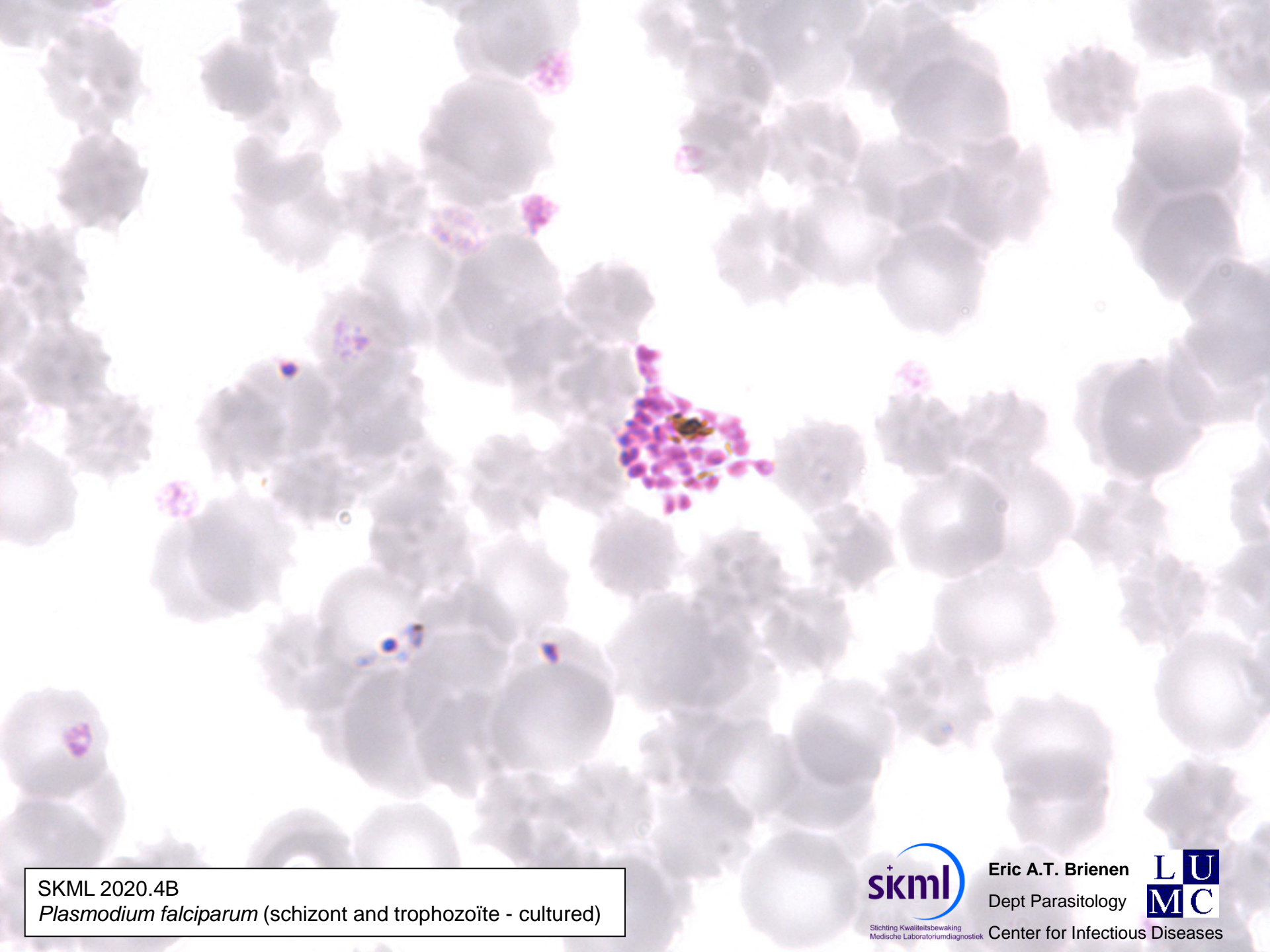
Plasmodium falciparum (schizonts and trophozoite - cultured)



Eric A.T. Brienen
Dept Parasitology



Center for Infectious Diseases



SKML 2020.4B

Plasmodium falciparum (schizont and trophozoite - cultured)



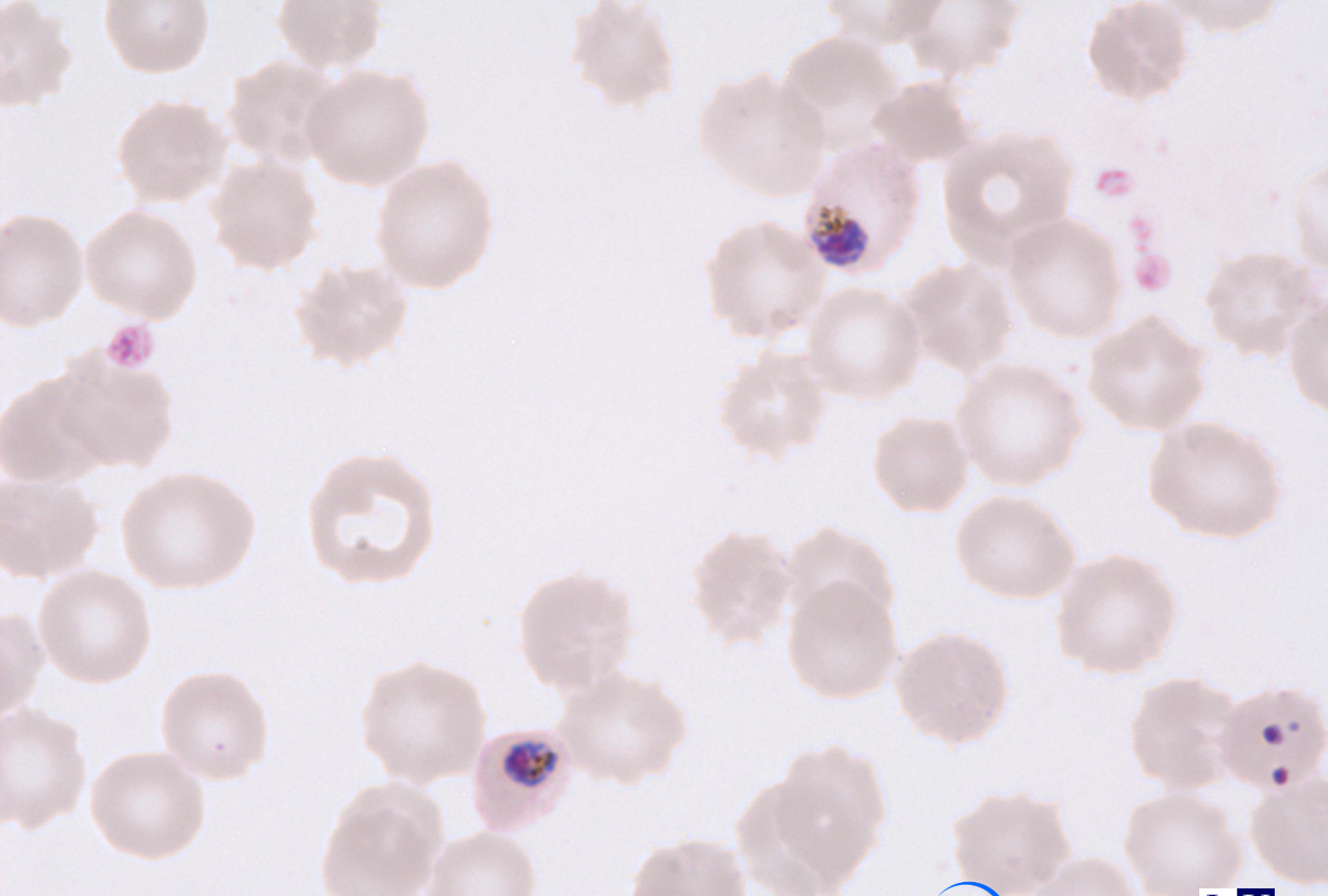
Stichting Kwaliteitsbewaking
Medische Laboratoriumdiagnostiek

Eric A.T. Brienen

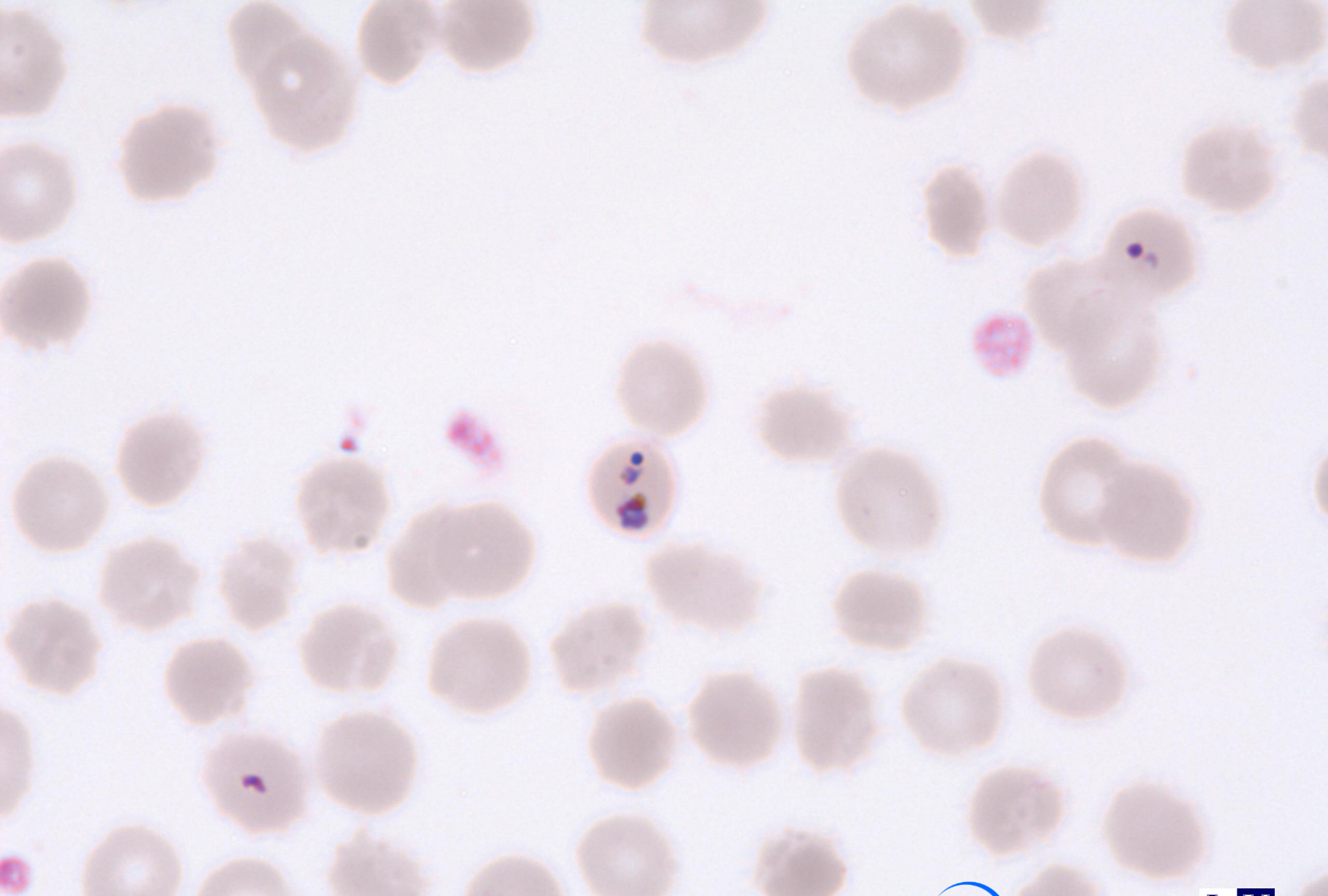
Dept Parasitology



Center for Infectious Diseases



SKML 2020.4B
Plasmodium falciparum (trophozoïtes - cultured)



SKML 2020.4B

Plasmodium falciparum (trophozoïtes - cultured)



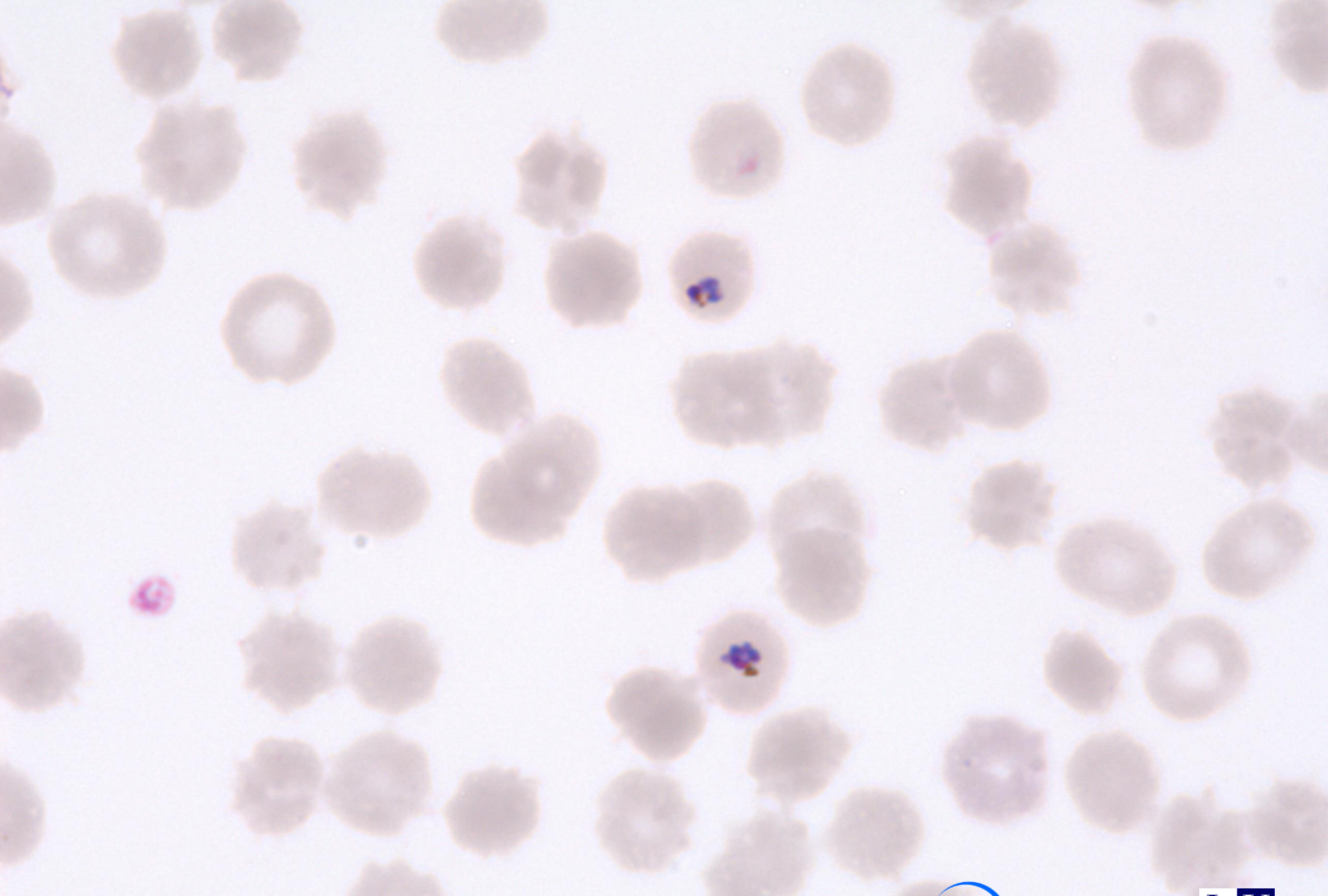
Stichting Kwaliteitsbewaking
Medische Laboratoriumdiagnostiek

Eric A.T. Brienen

Dept Parasitology



Center for Infectious Diseases



SKML 2020.4B

Plasmodium falciparum (trophozoïtes - cultured)



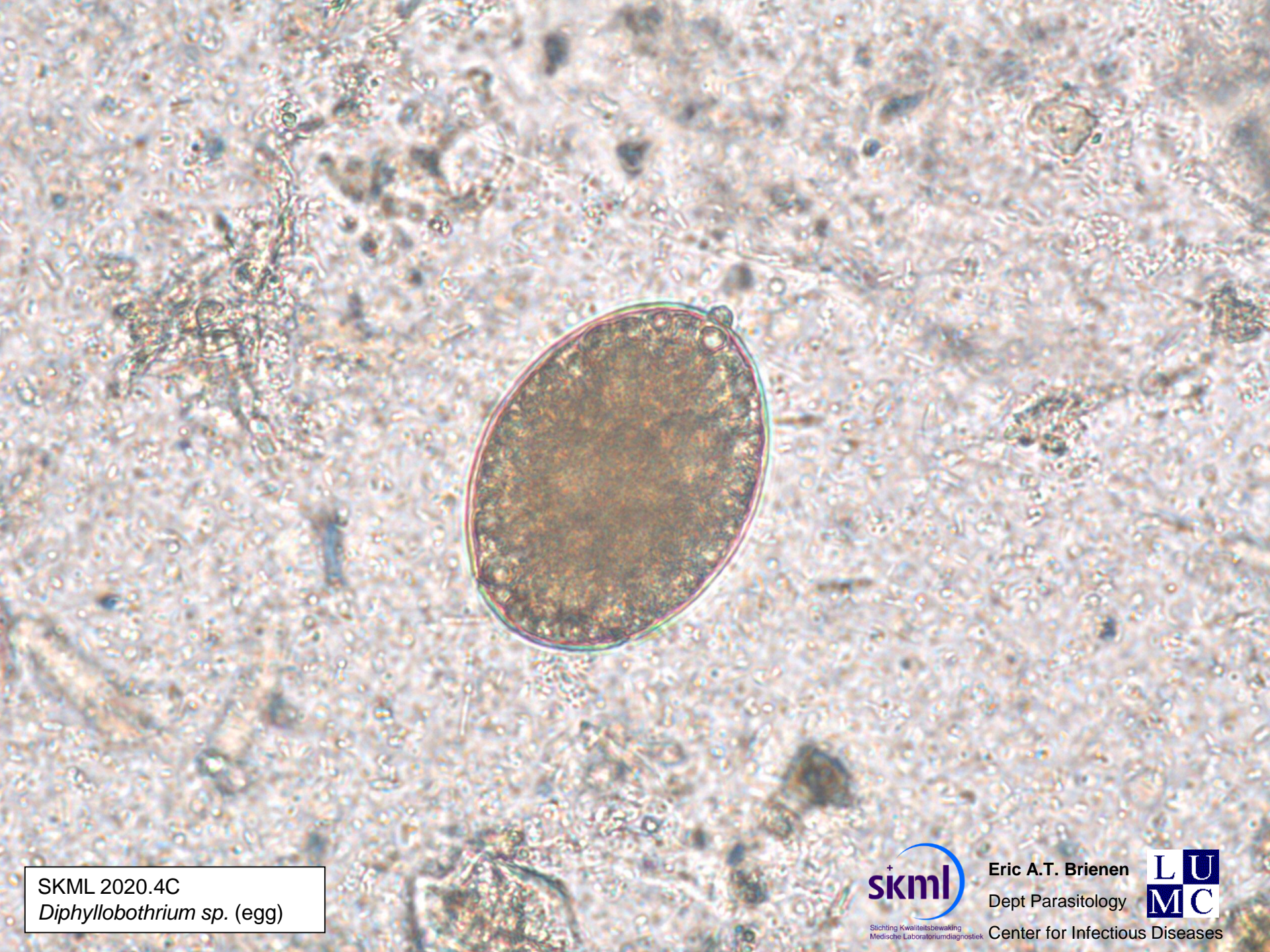
Stichting Kwaliteitsbewaking
Medische Laboratoriumdiagnostiek

Eric A.T. Brienen

Dept Parasitology



Center for Infectious Diseases



SKML 2020.4C
Diphyllobothrium sp. (egg)

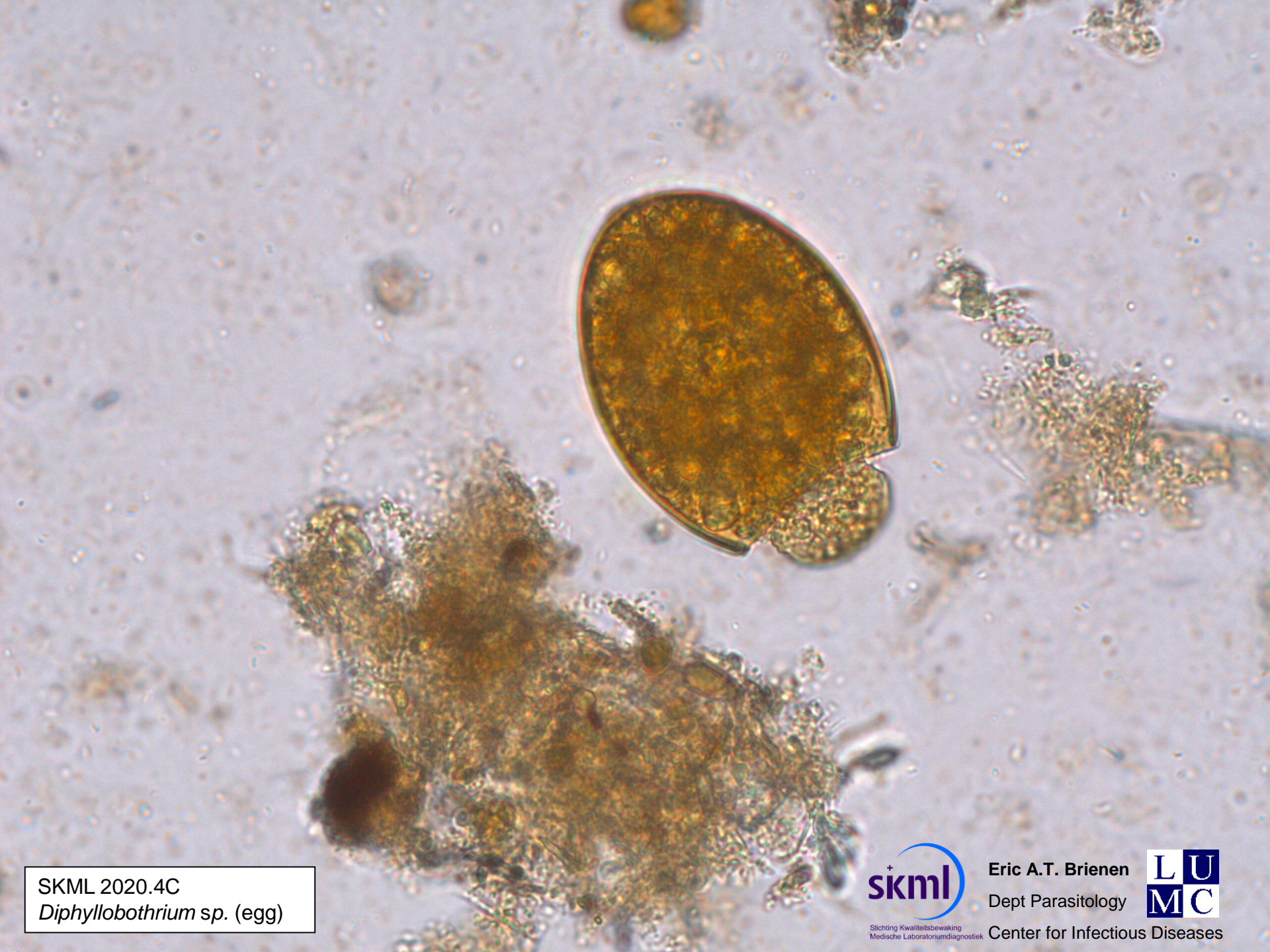


Stichting Kwaliteitsbewaking
Medische Laboratoriumdiagnostiek

Eric A.T. Brienen
Dept Parasitology



Center for Infectious Diseases



SKML 2020.4C
Diphyllobothrium sp. (egg)

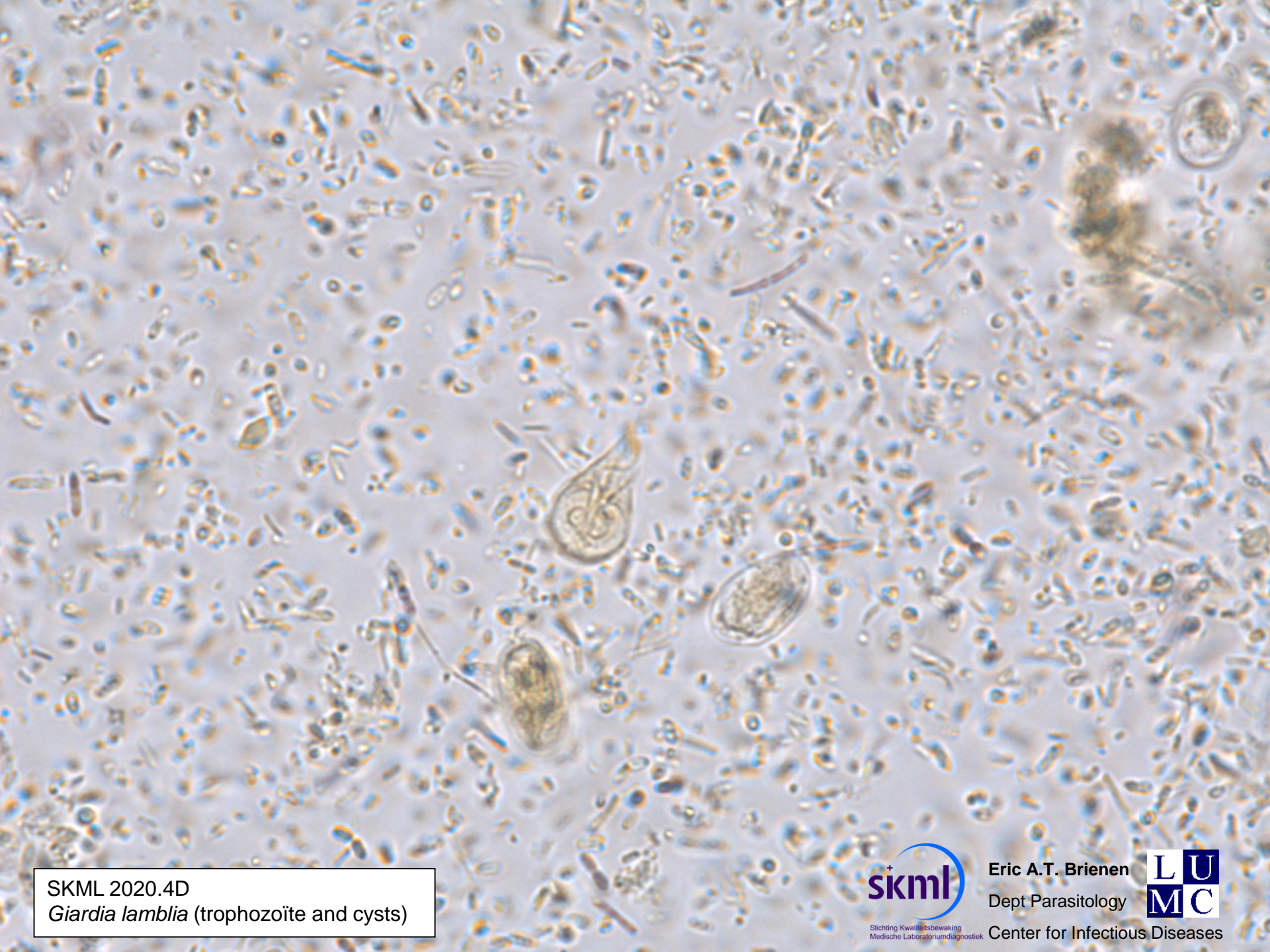


Stichting Kwaliteitsbewaking
Medische Laboratoriumdiagnostiek

Eric A.T. Brienen
Dept Parasitology



Center for Infectious Diseases



SKML 2020.4D
Giardia lamblia (trophozoïte and cysts)

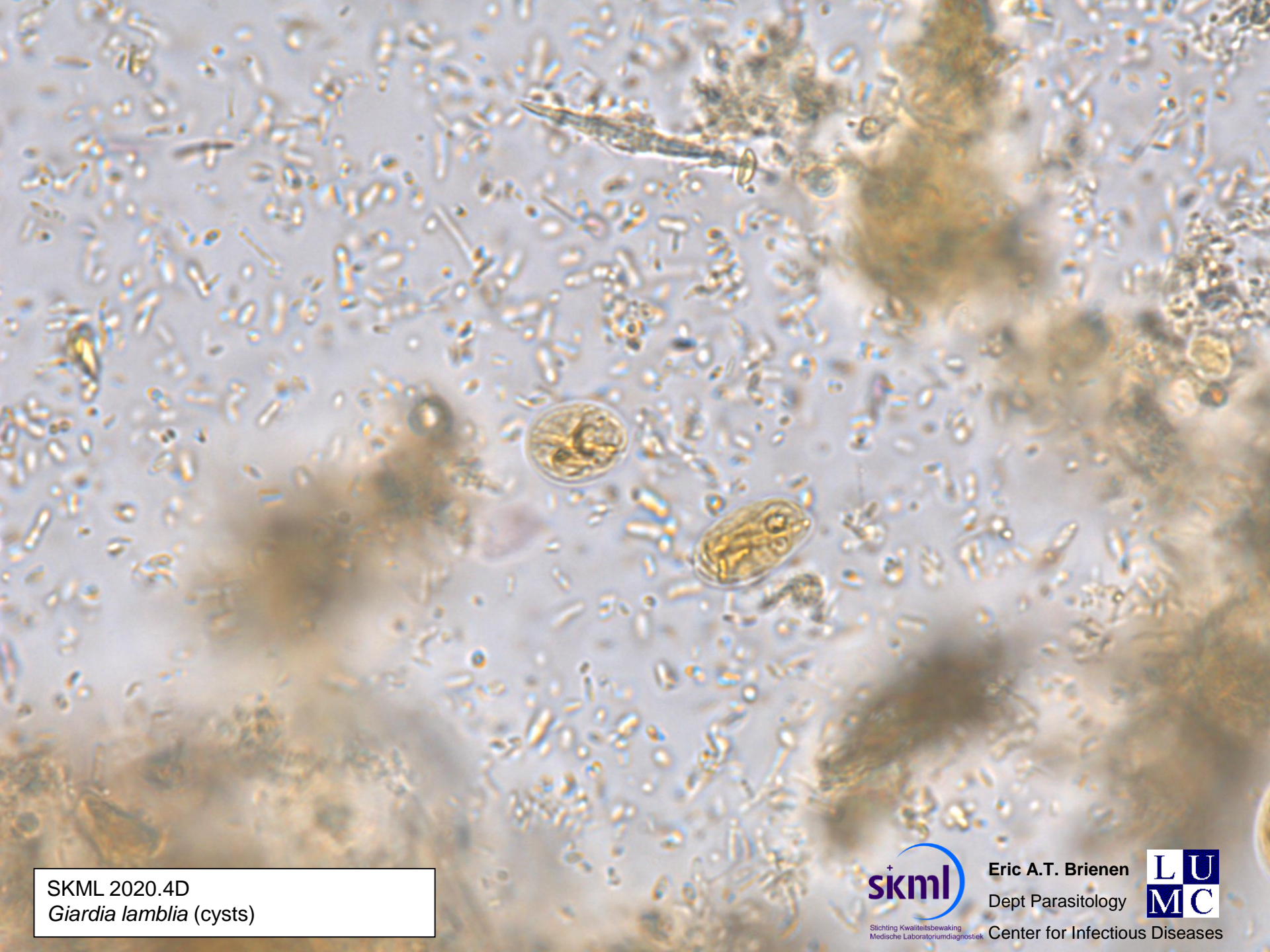


Stichting Kwaliteitsbewaking
Medische Laboratoriumdiagnostiek

Eric A.T. Brien
Dept Parasitology



Center for Infectious Diseases



SKML 2020.4D
Giardia lamblia (cysts)



Stichting Kwaliteitsbewaking
Medische Laboratoriumdiagnostiek

Eric A.T. Brienens
Dept Parasitology



Center for Infectious Diseases

SKML morphology parasitology – explanations

2020.1A *Loa loa* microfilaria

2020.1B *Plasmodium malariae*

2020.1C *Giardia lamblia* (+ sporadic *Dientamoeba* and some non-pathogen protozoa)

2020.1D *Schistosoma mansoni* eggs

2020.2A *Plasmodium falciparum*, ≈ 2%

2020.2B *Plasmodium falciparum*, ≈ 16%

2020.2C *Echinococcus granulosus*

2020.2D *Ascaris* sp. eggs

2020.3A *Plasmodium falciparum*, ≈ 2%

2020.3B *Plasmodium vivax*

2020.3C Hookworm eggs and *Entamoeba coli* cysts

2020.3D *Hymenolepis diminuta* eggs

2020.4A Negative (artefacts)

2020.4B *Plasmodium falciparum*, ≈ 1.3% (cultured)

2020.4C *Diphyllobothrium* sp. eggs

2020.4D *Giardia lamblia* trophozoites and cysts