

SKML overview of EQAS

Morphology External Quality Assessment Scheme

- Part 1: blood parasites
- Part 2: faecal and tissue parasites
- Last slide: names and details of parasites

(C) SKML section parasitology

For training and education purpose only

Please acknowledge:



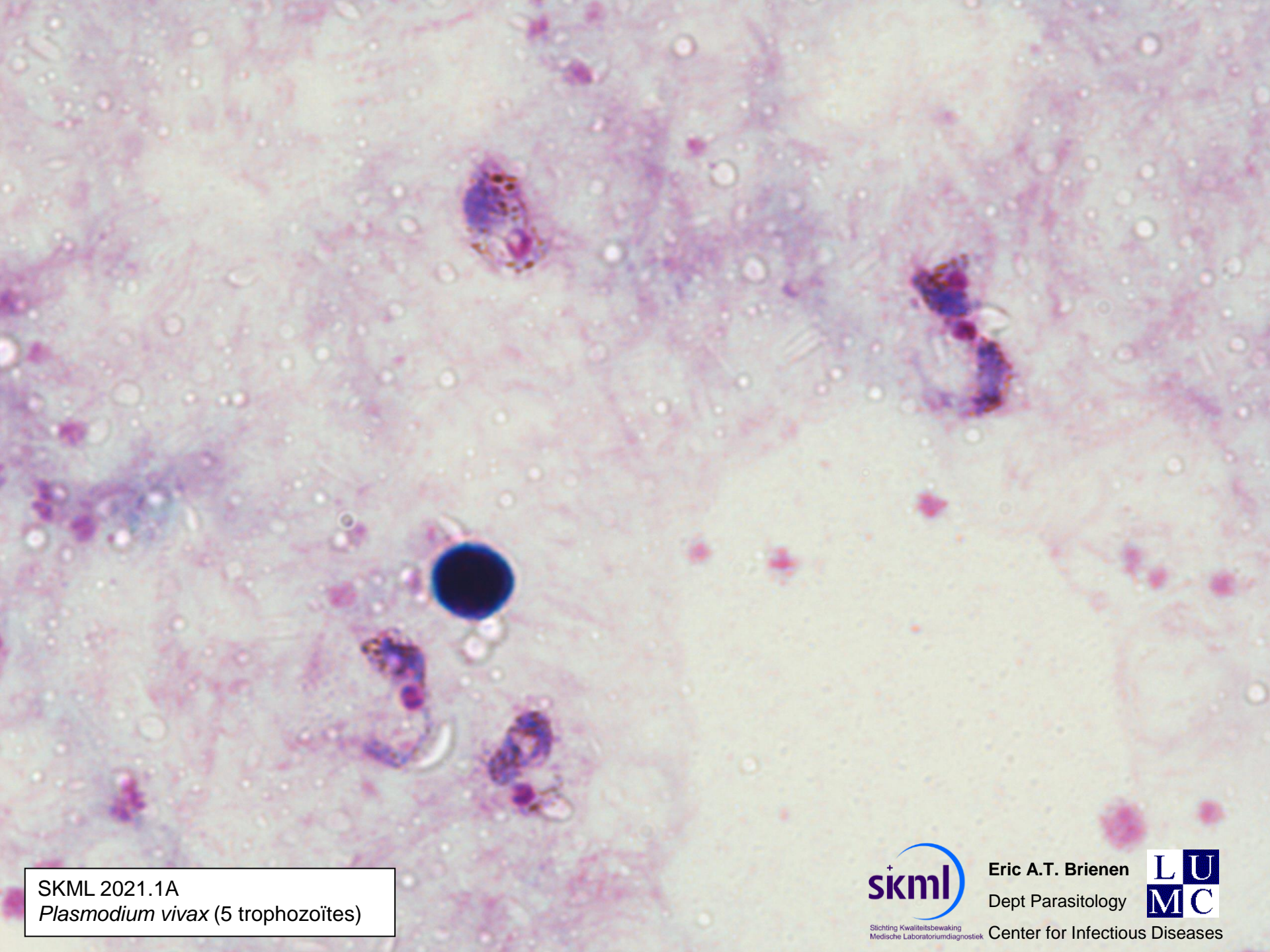
Eric A.T. Brienen

Dept Parasitology

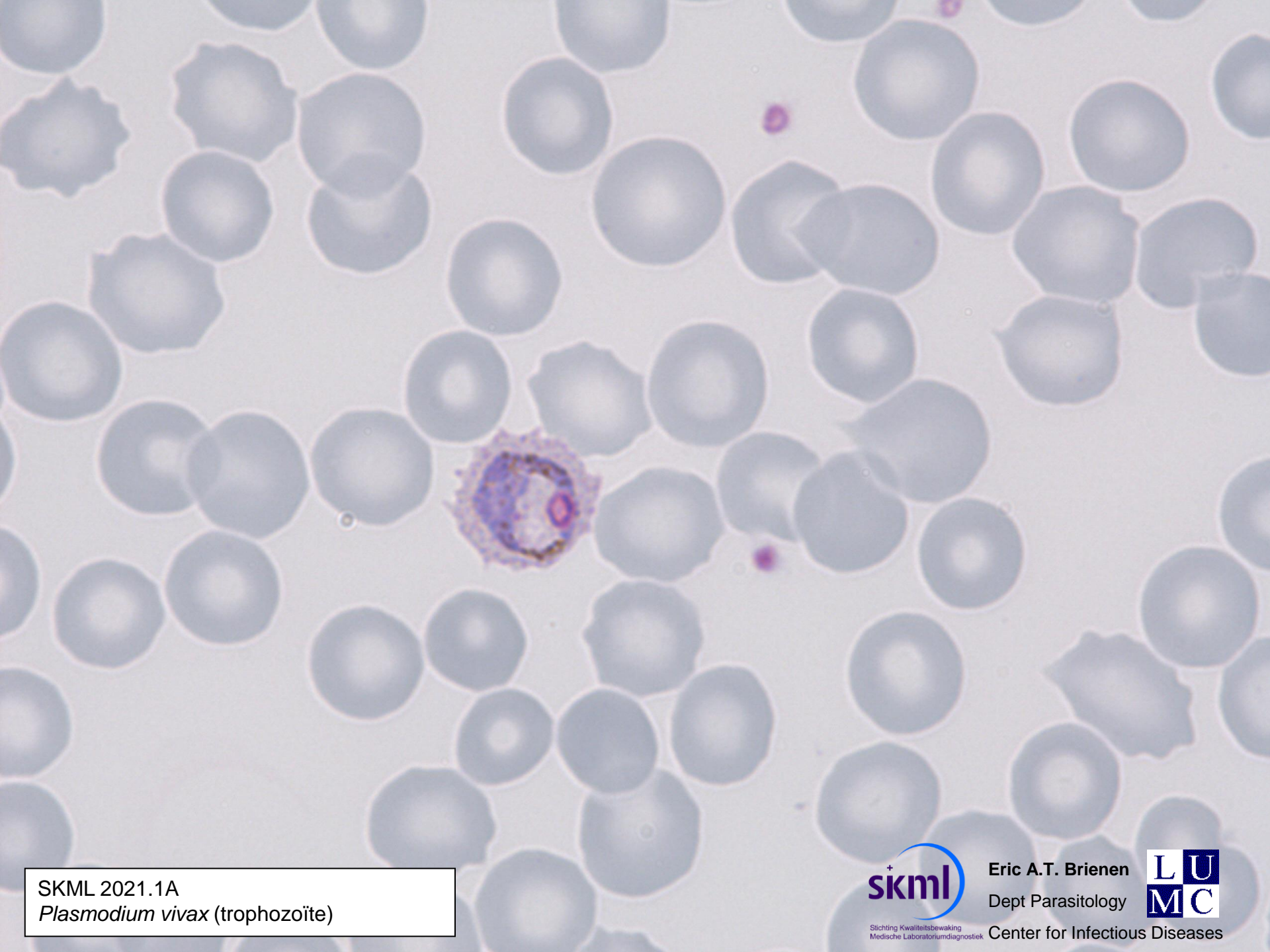Center for Infectious Diseases



NB: a separate file is provided without the name of the parasite depicted on each slide



SKML 2021.1A
Plasmodium vivax (5 trophozoïtes)



SKML 2021.1A
Plasmodium vivax (trophozoïte)

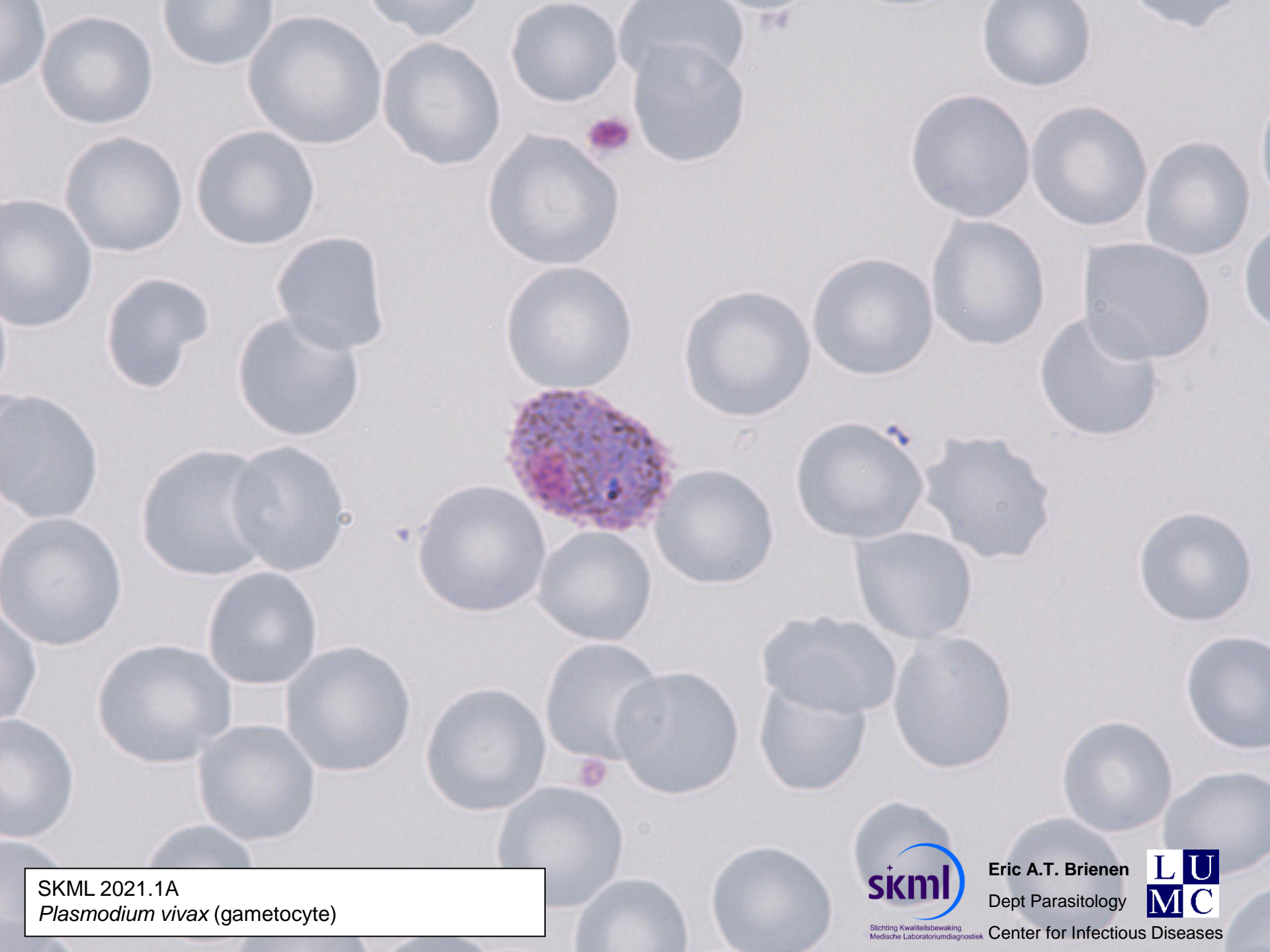

Stichting Kwaliteitsbewaking
Medische Laboratoriumdiagnostiek

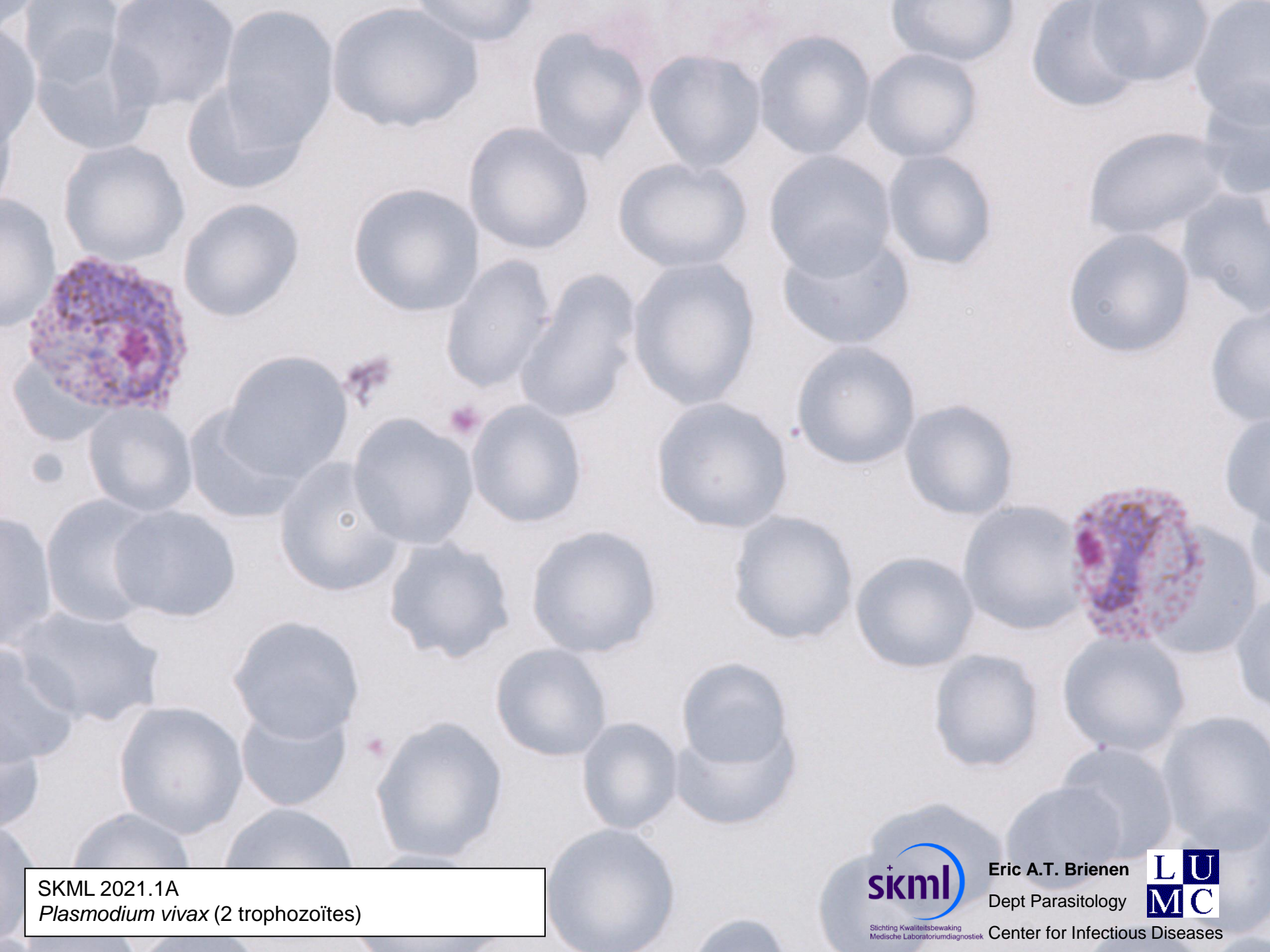Eric A.T. Brienen
Dept Parasitology



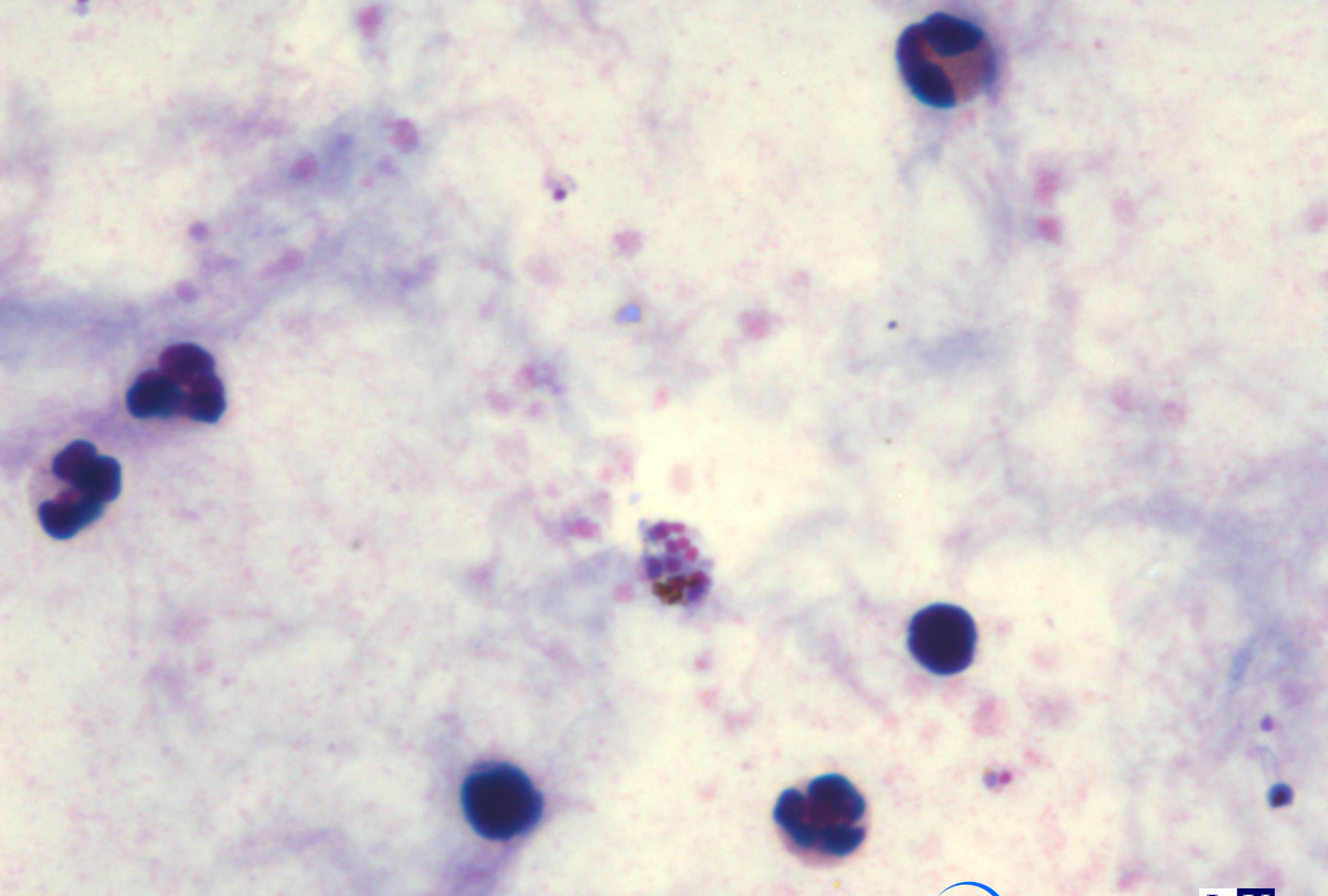
Center for Infectious Diseases



SKML 2021.1A
Plasmodium vivax (gametocyte)



SKML 2021.1A
Plasmodium vivax (2 trophozoïtes)



SKML 2021.1B

Plasmodium falciparum \approx 0.2 % (trophozoïtes and schizont)

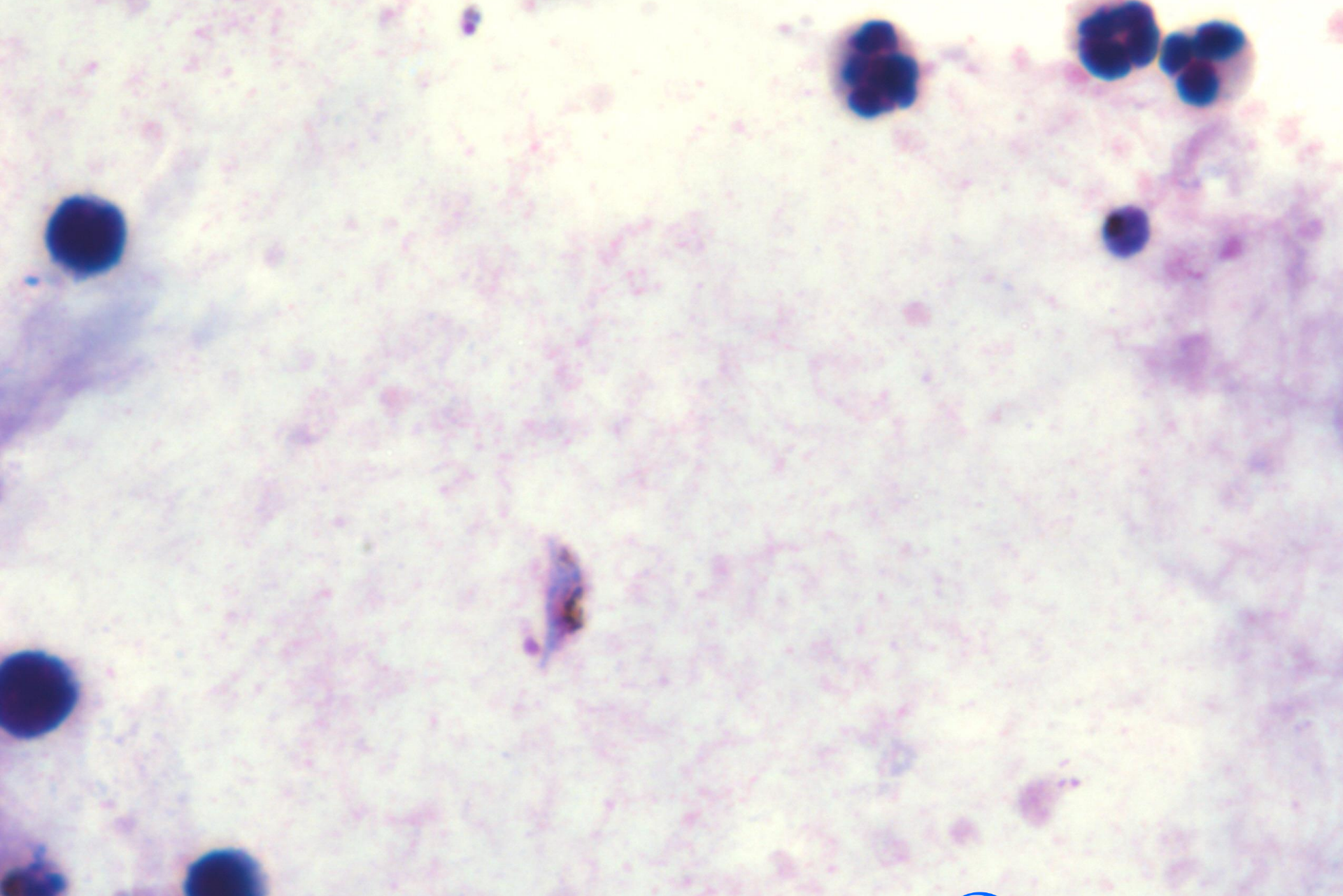


Eric A.T. Brien

Dept Parasitology

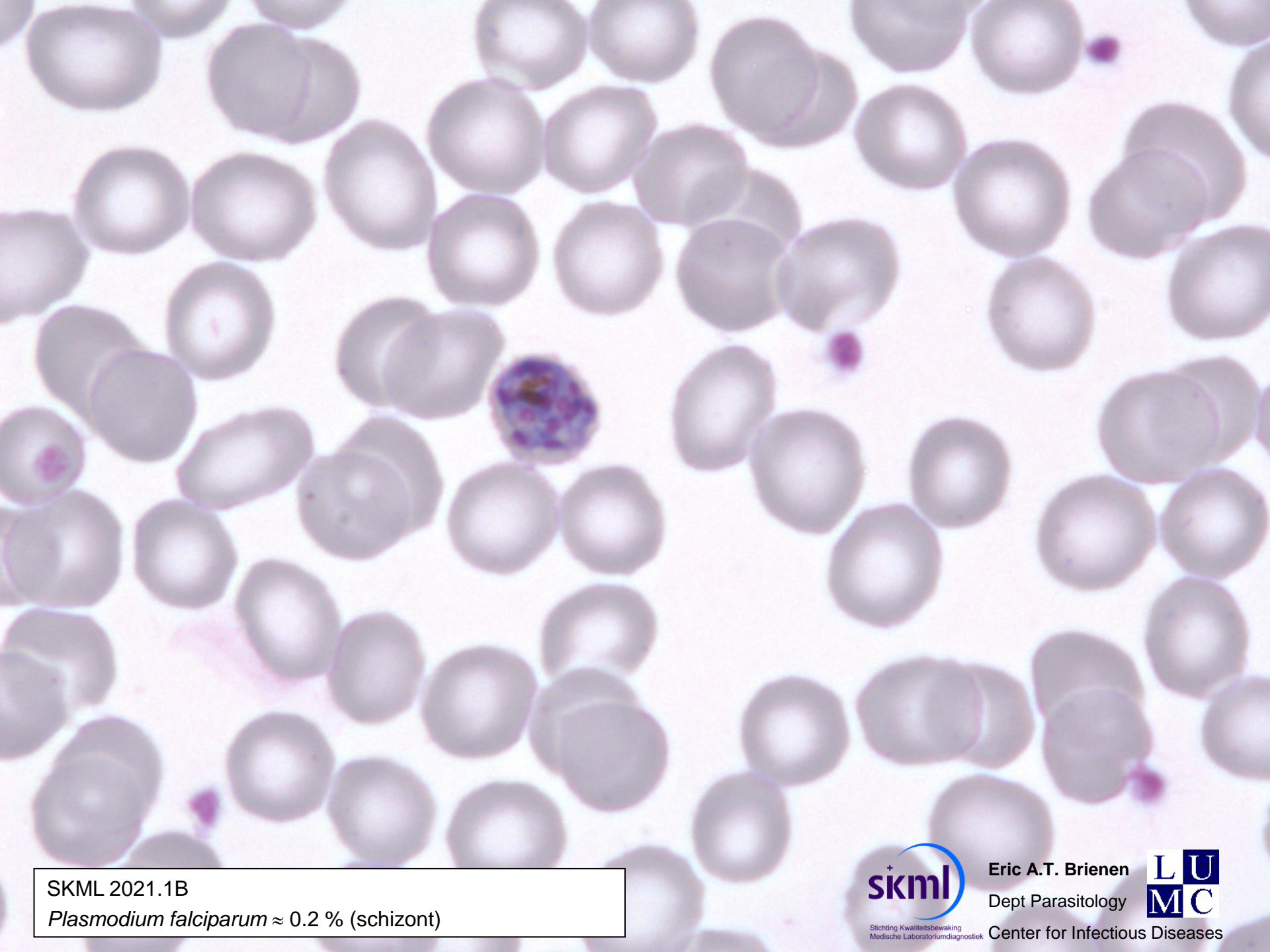
Center for Infectious Diseases





SKML 2021.1B

Plasmodium falciparum \approx 0.2 % (trophozoïte and gametocyte)



SKML 2021.1B

Plasmodium falciparum \approx 0.2 % (schizont)



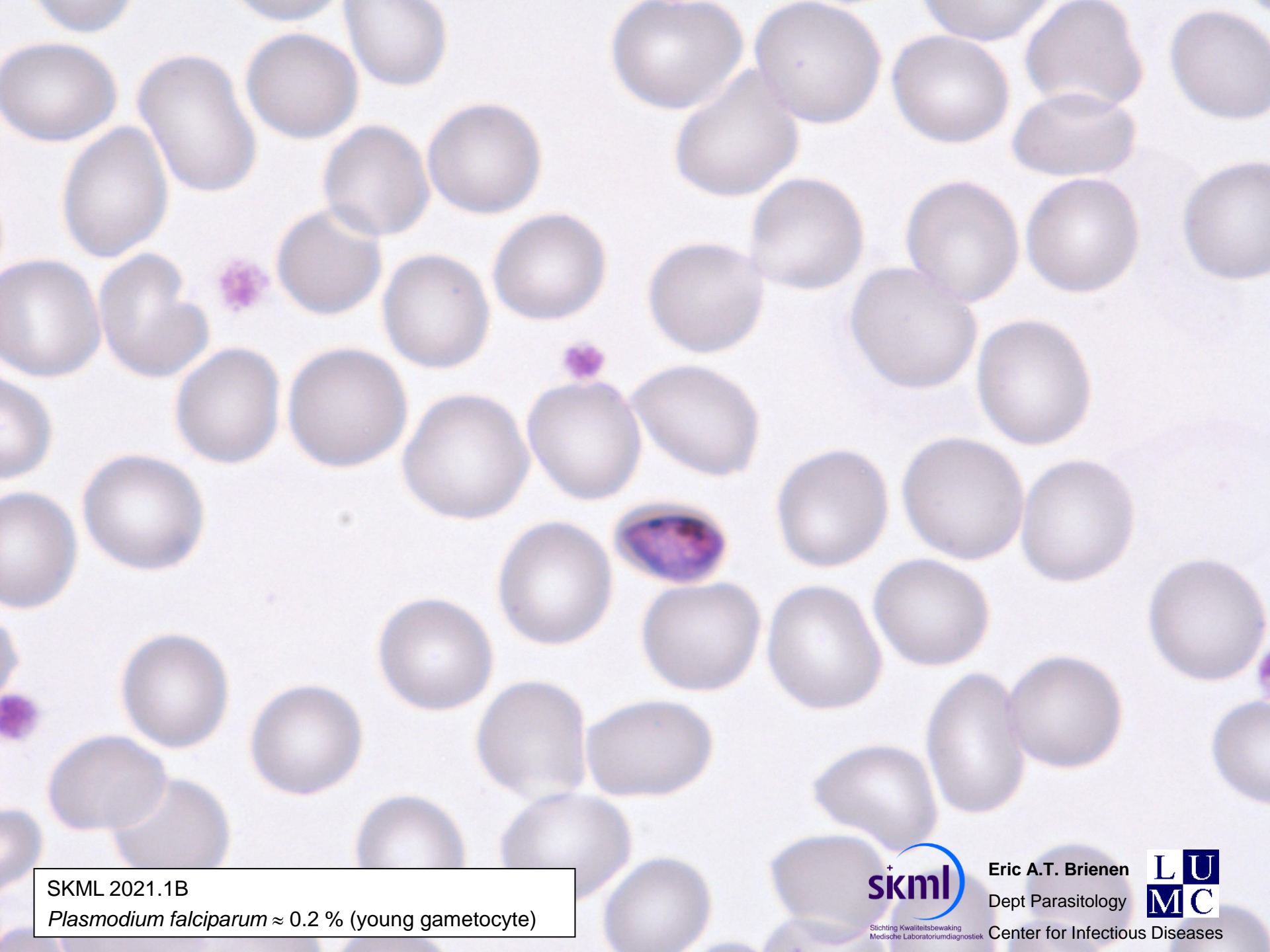Stichting Kwaliteitsbewaking
Medische Laboratoriumdiagnostiek

Eric A.T. Brien

Dept Parasitology

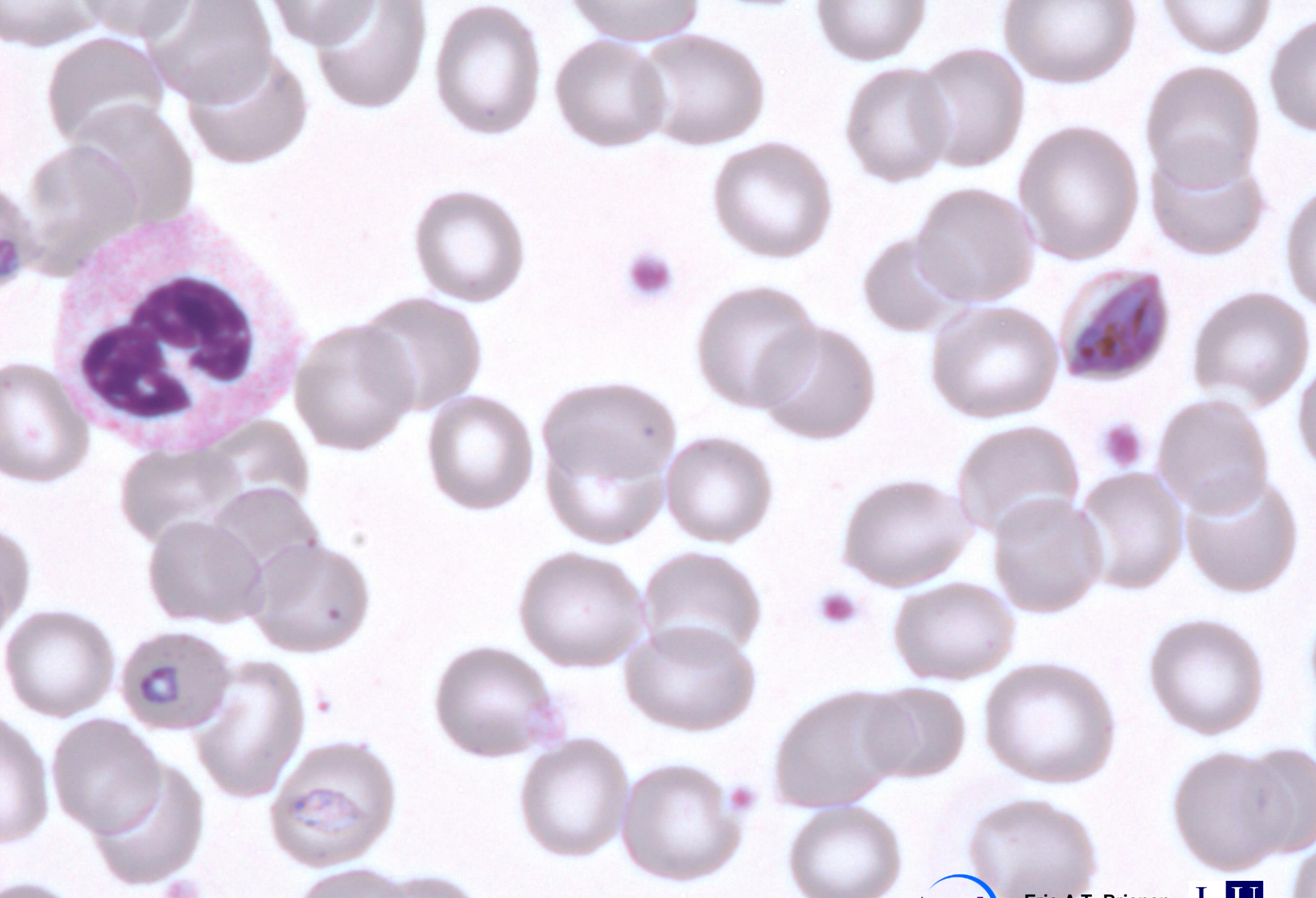


Center for Infectious Diseases



SKML 2021.1B

Plasmodium falciparum \approx 0.2 % (young gametocyte)



SKML 2021.1B
Plasmodium falciparum \approx 0.2 % (trophozoïte and young gametocyte)

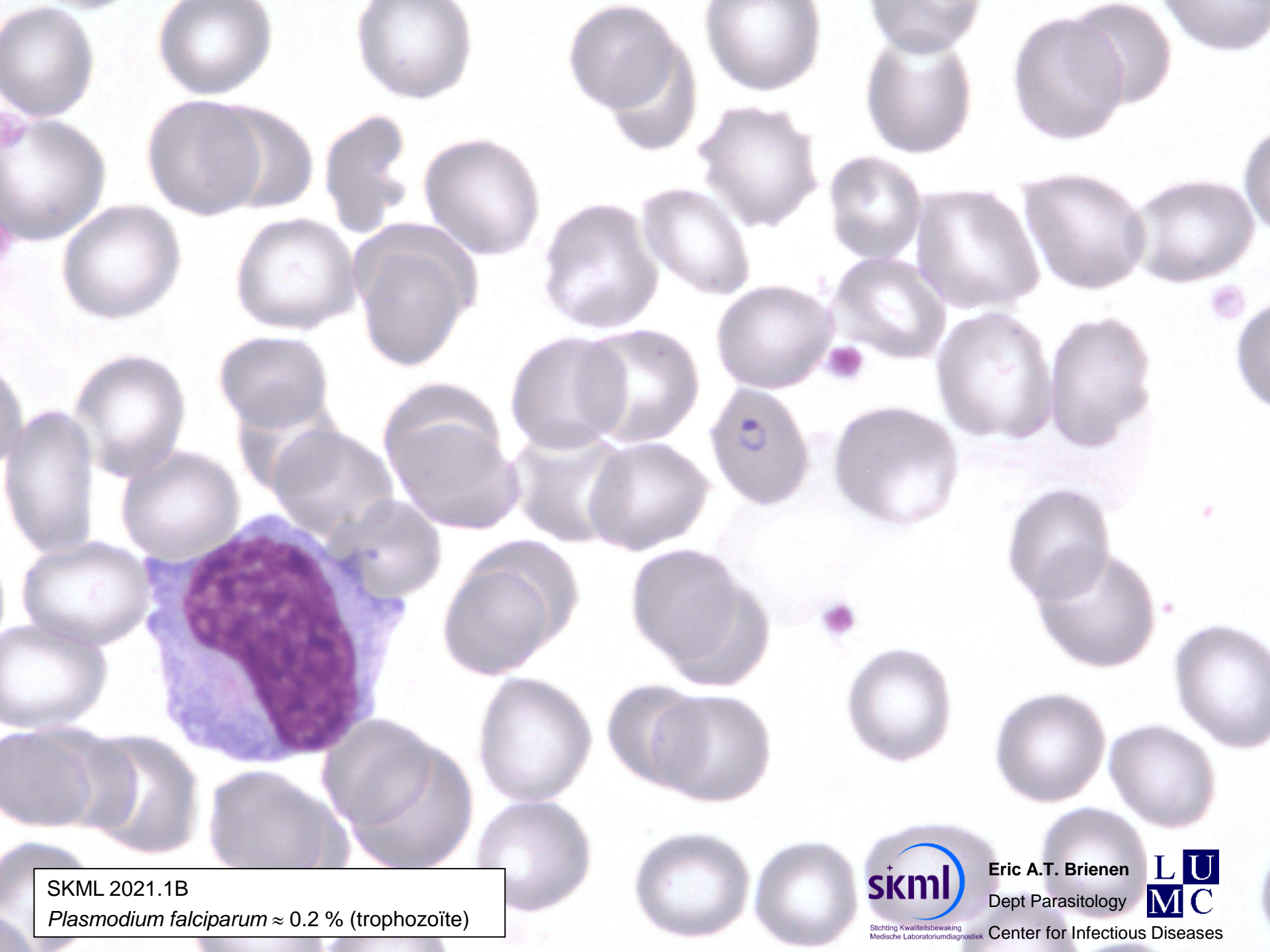


Stichting Kwaliteitsbewaking
Medische Laboratoriumdiagnostiek

Eric A.T. Brienens
Dept Parasitology



Center for Infectious Diseases



SKML 2021.1B

Plasmodium falciparum \approx 0.2 % (trophozoïte)



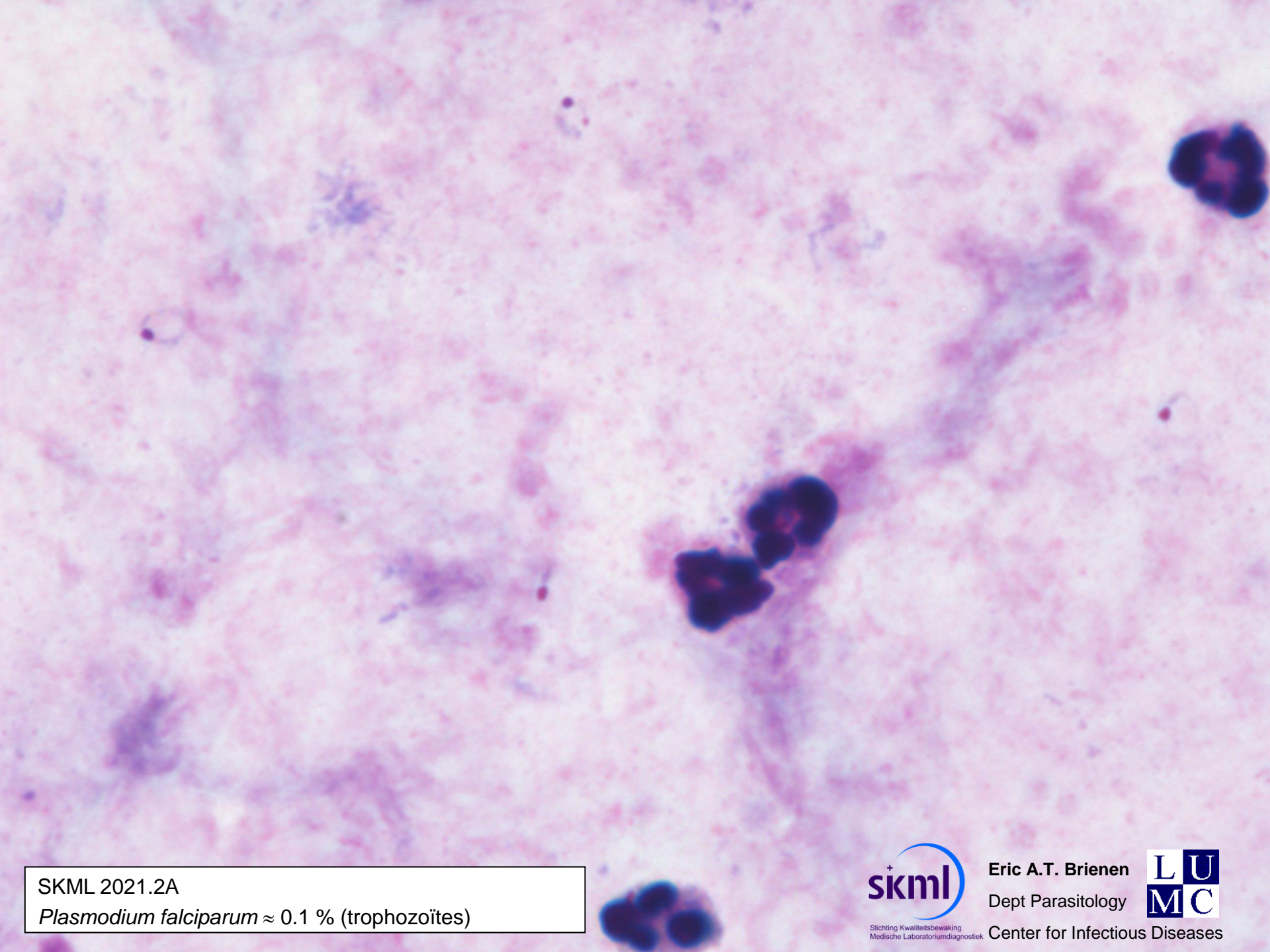
Stichting Kwaliteitsbewaking
Medische Laboratoriumdiagnostiek

Eric A.T. Brien

Dept Parasitology



Center for Infectious Diseases



SKML 2021.2A

Plasmodium falciparum \approx 0.1 % (trophozoïtes)



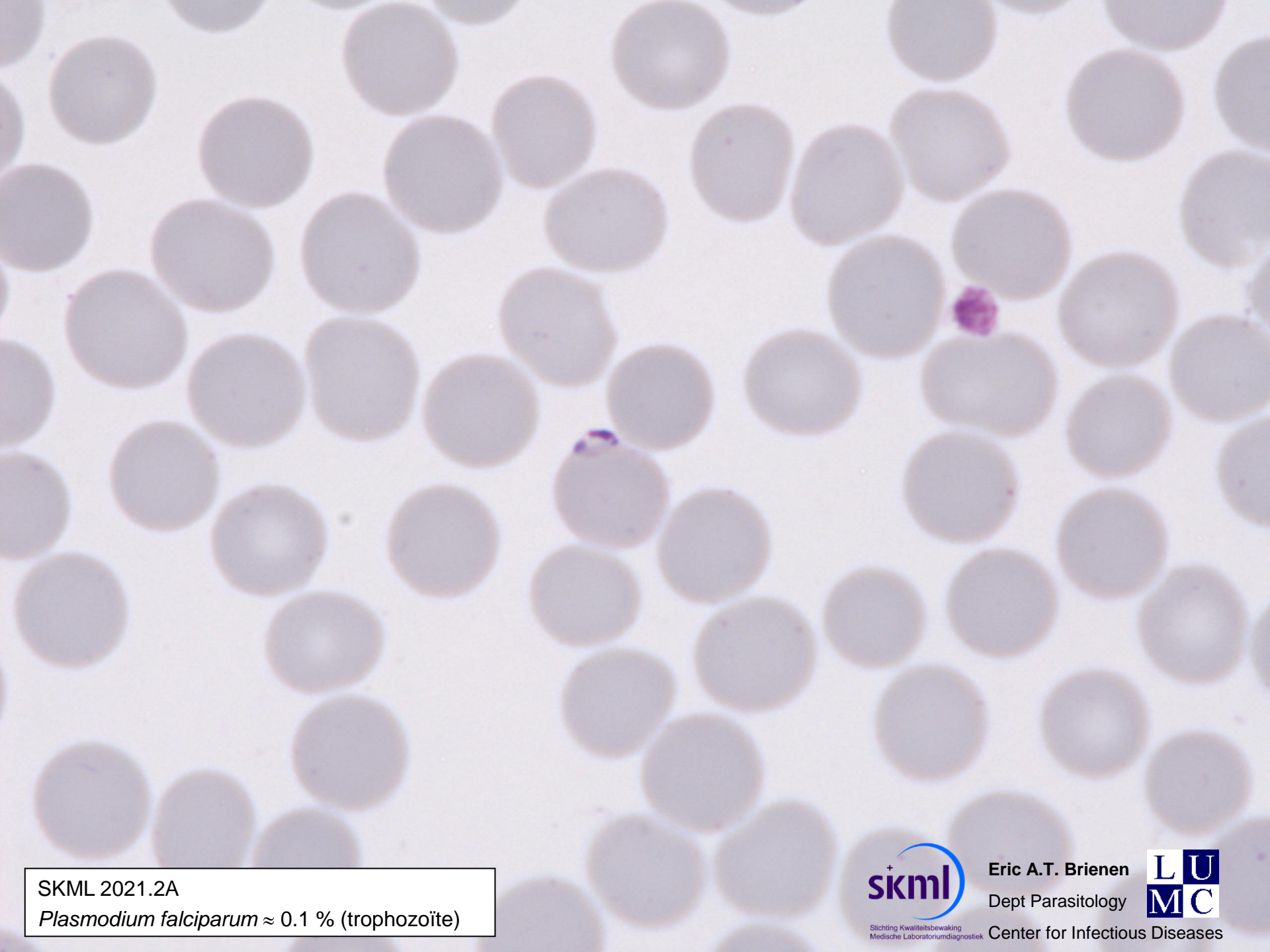Stichting Kwaliteitsbewaking
Medische Laboratoriumdiagnostiek

Eric A.T. Brienens

Dept Parasitology



Center for Infectious Diseases



SKML 2021.2A

Plasmodium falciparum \approx 0.1 % (trophozoïte)



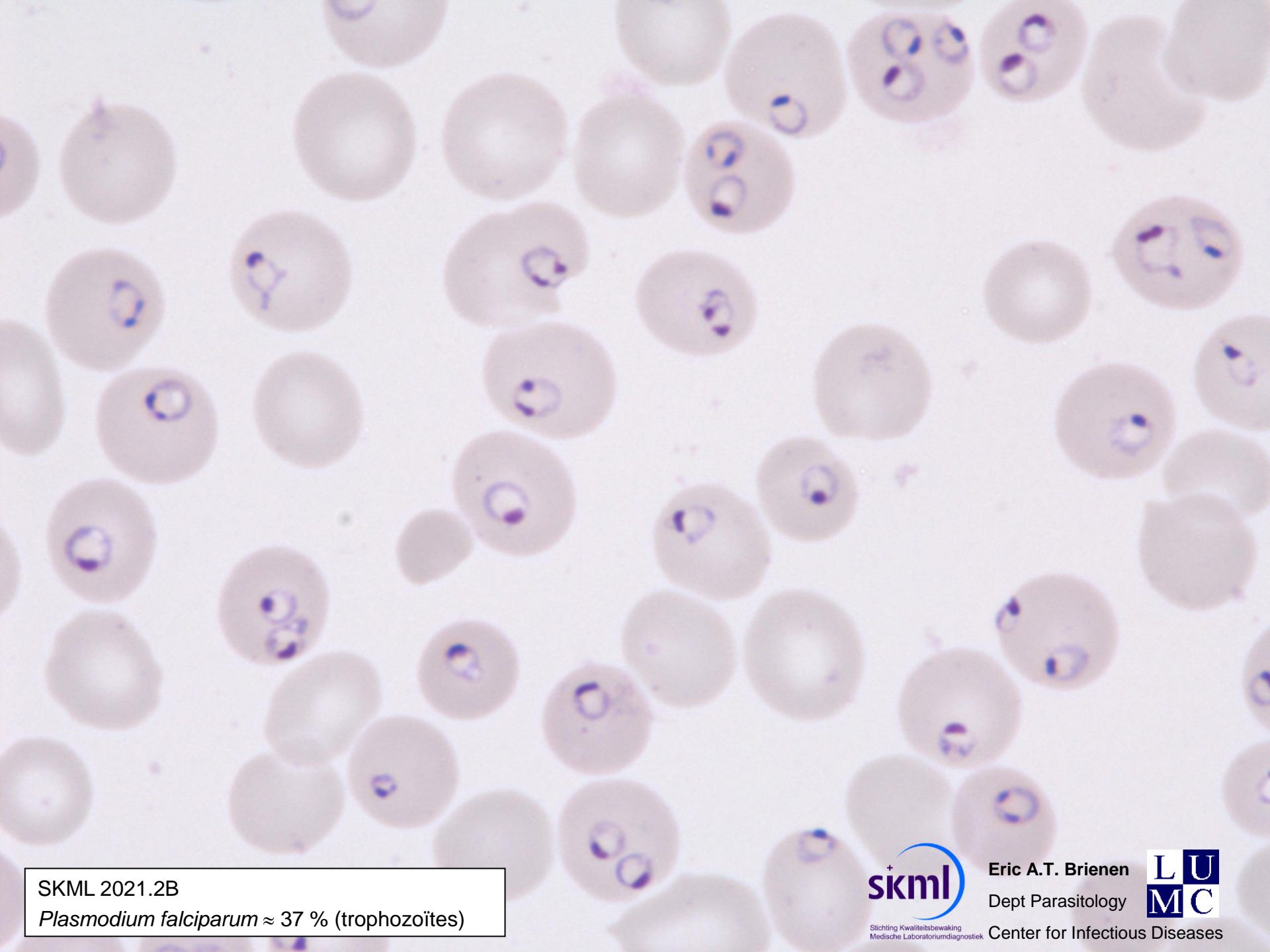
Stichting Kwaliteitsbewaking
Medische Laboratoriumdiagnostiek

Eric A.T. Brienens

Dept Parasitology



Center for Infectious Diseases



SKML 2021.2B

Plasmodium falciparum ≈ 37 % (trophozoïtes)



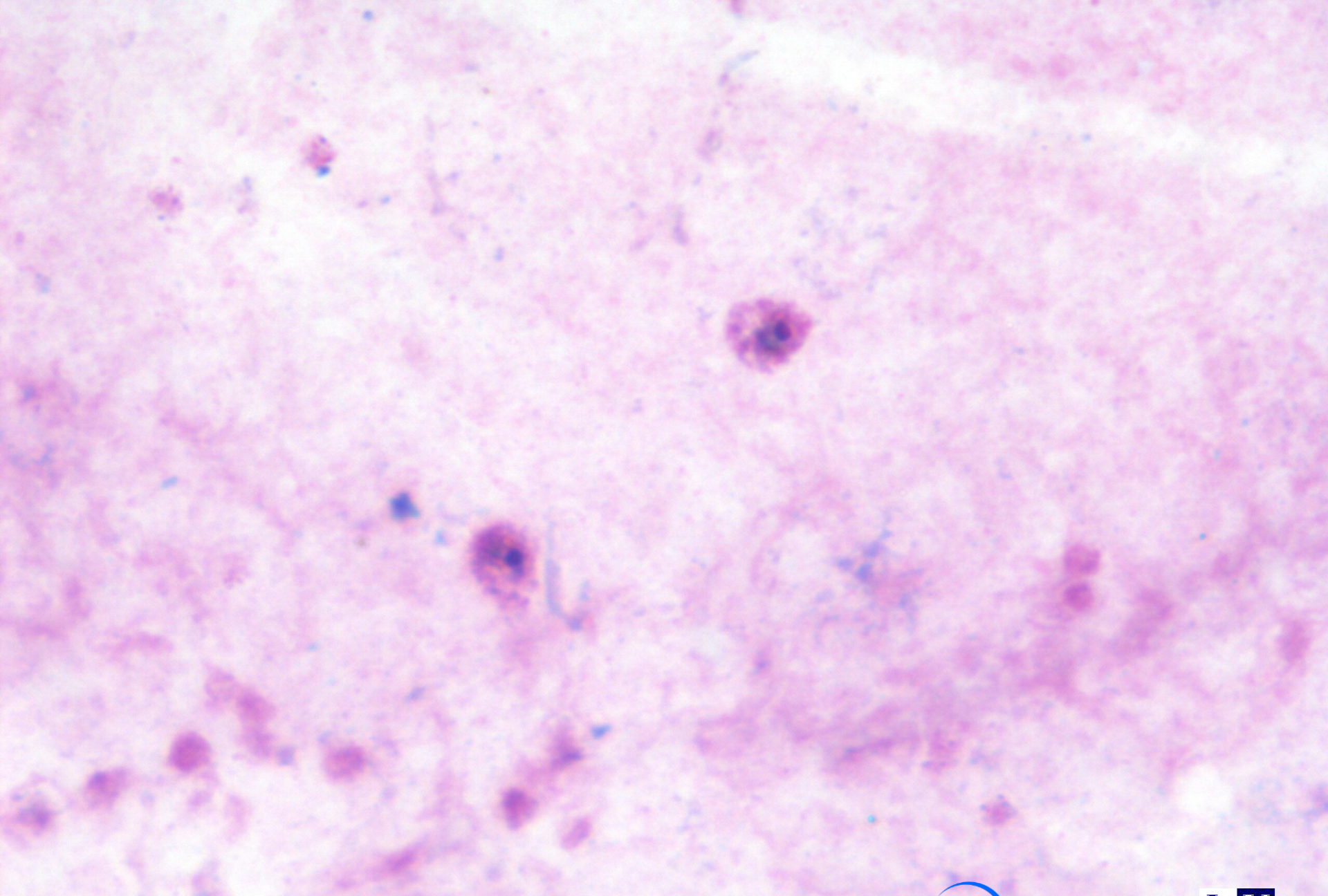
Stichting Kwaliteitsbewaking
Medische Laboratoriumdiagnostiek

Eric A.T. Brienen

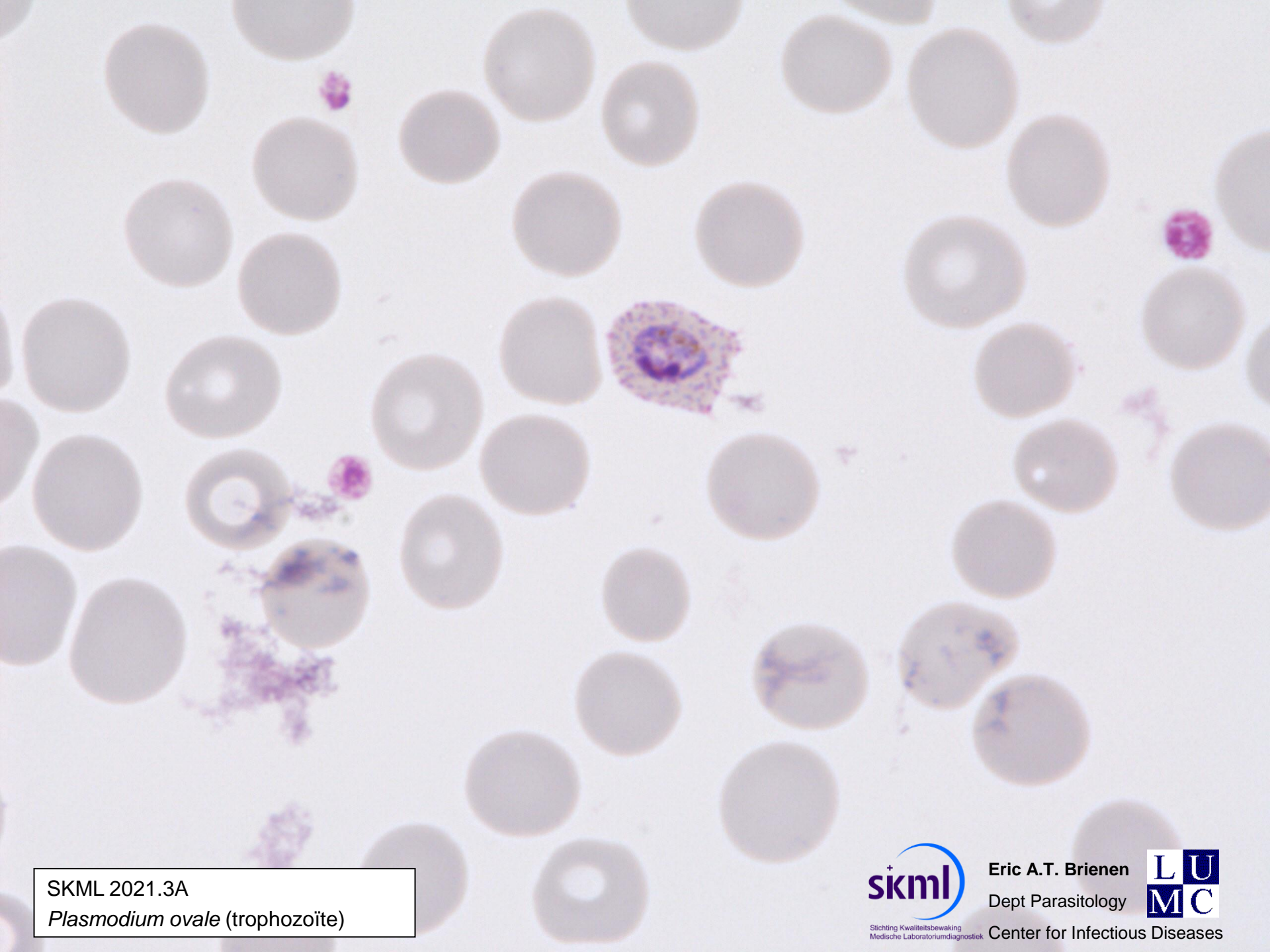
Dept Parasitology



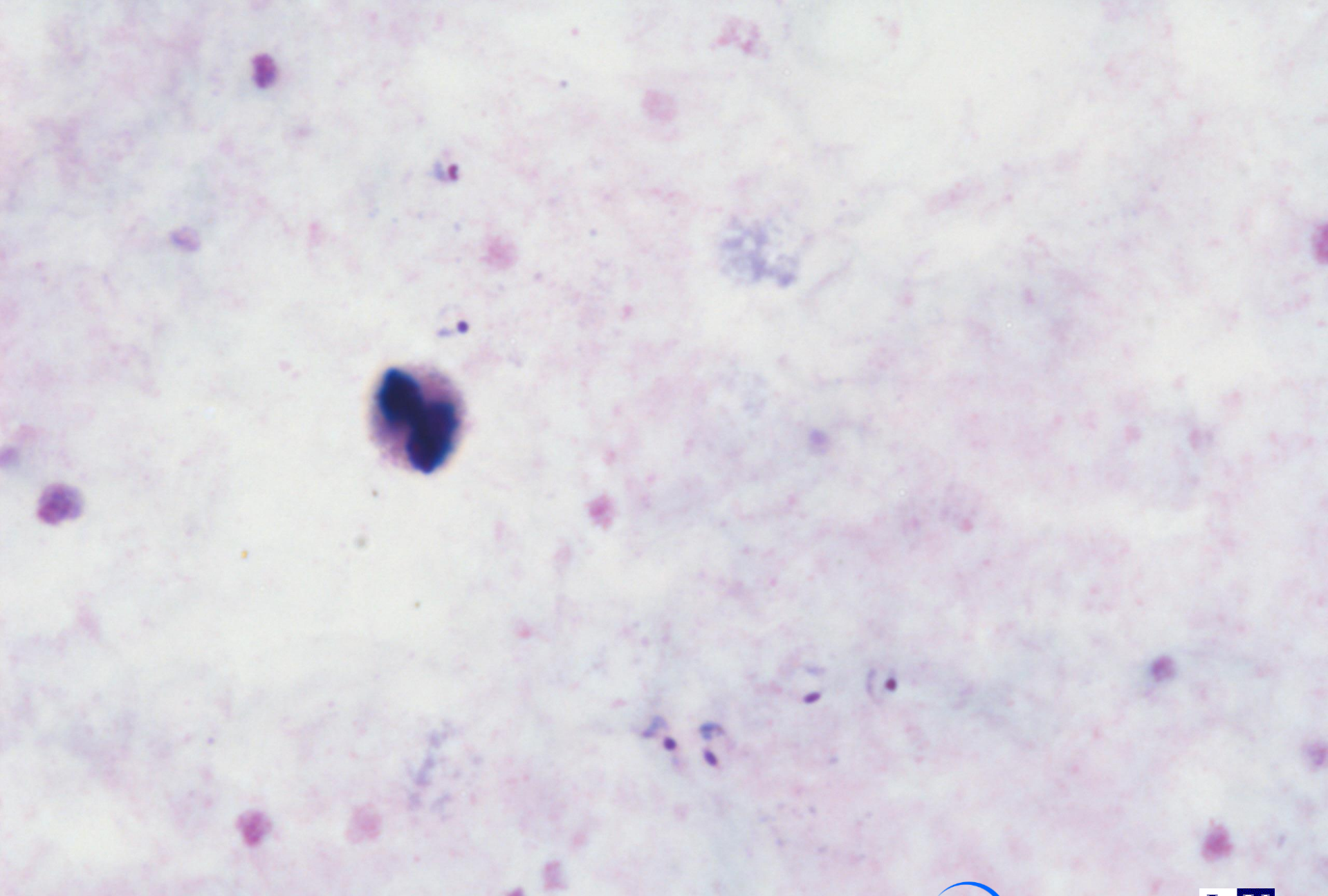
Center for Infectious Diseases



SKML 2021.3A
Plasmodium ovale (2 trophozoïtes)



SKML 2021.3A
Plasmodium ovale (trophozoïte)



SKML 2021.3B

Plasmodium falciparum \approx 1% (trophozoïtes)



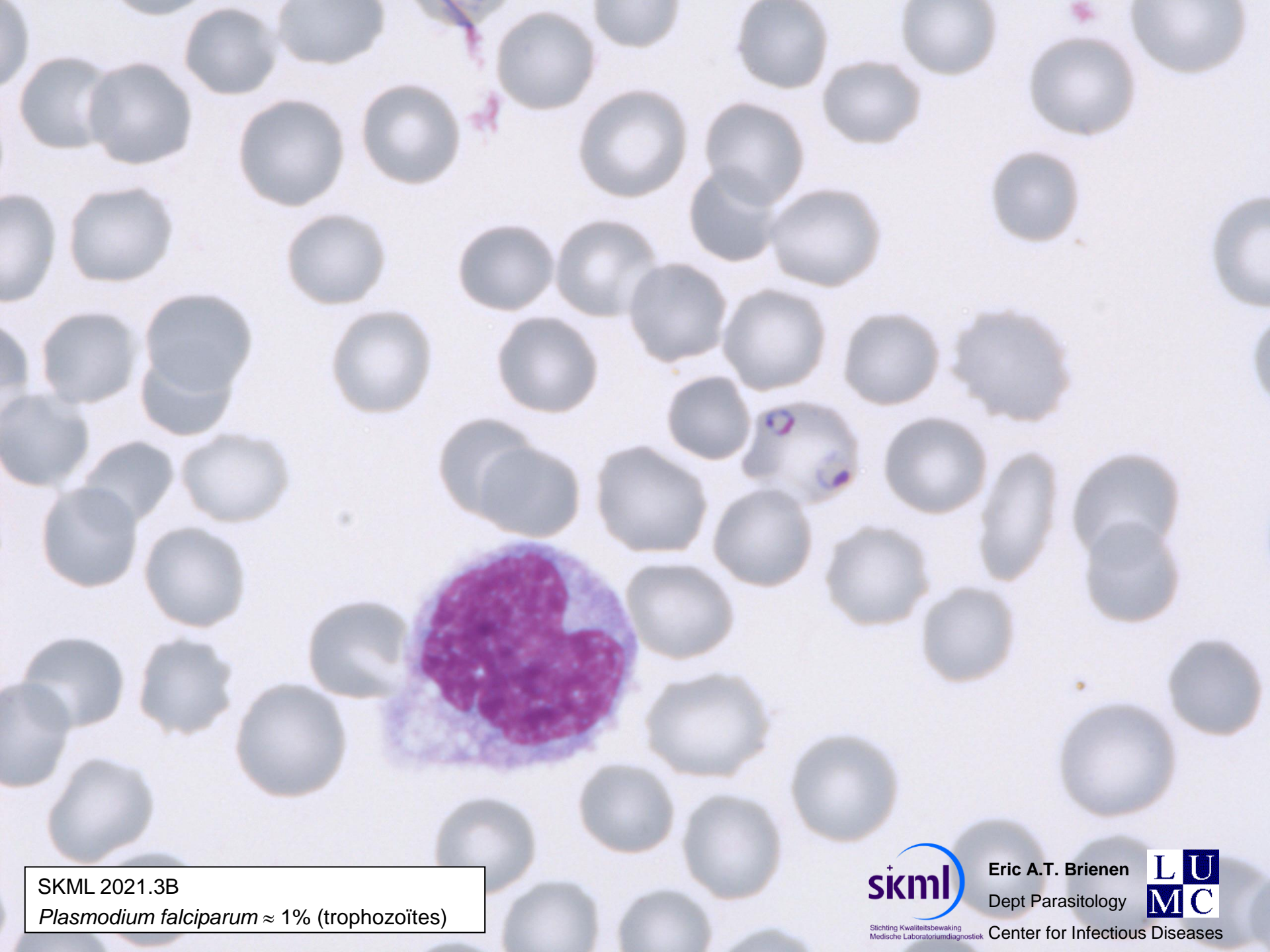
Stichting Kwaliteitsbewaking
Medische Laboratoriumdiagnostiek

Eric A.T. Brien

Dept Parasitology



Center for Infectious Diseases



SKML 2021.3B

Plasmodium falciparum \approx 1% (trophozoïtes)



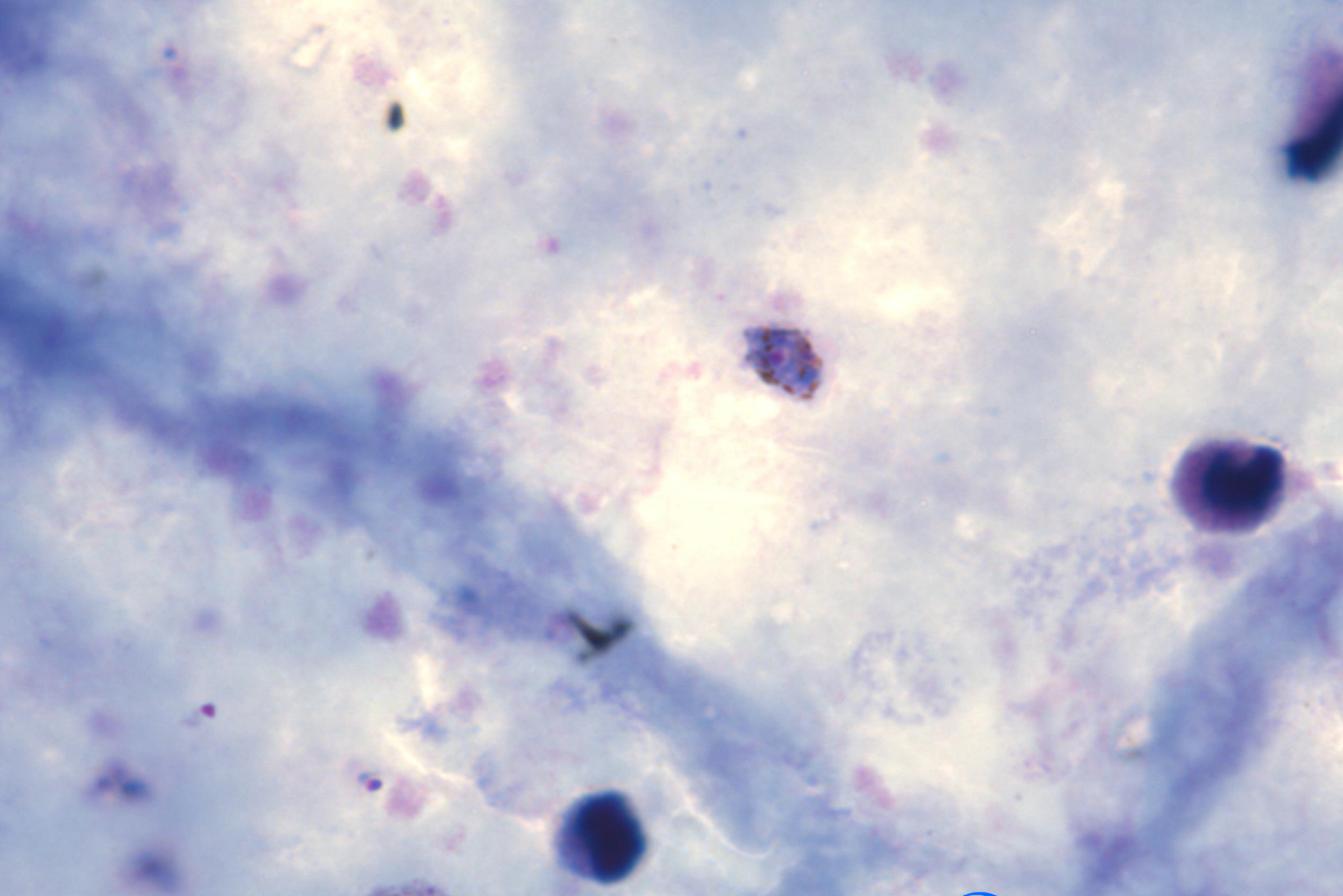
Stichting Kwaliteitsbewaking
Medische Laboratoriumdiagnostiek

Eric A.T. Brien

Dept Parasitology



Center for Infectious Diseases



SKML 2021.4B

Plasmodium falciparum \approx 0,1% (trophozoïtes)

Plasmodium ovale wallikeri (gametocyte)



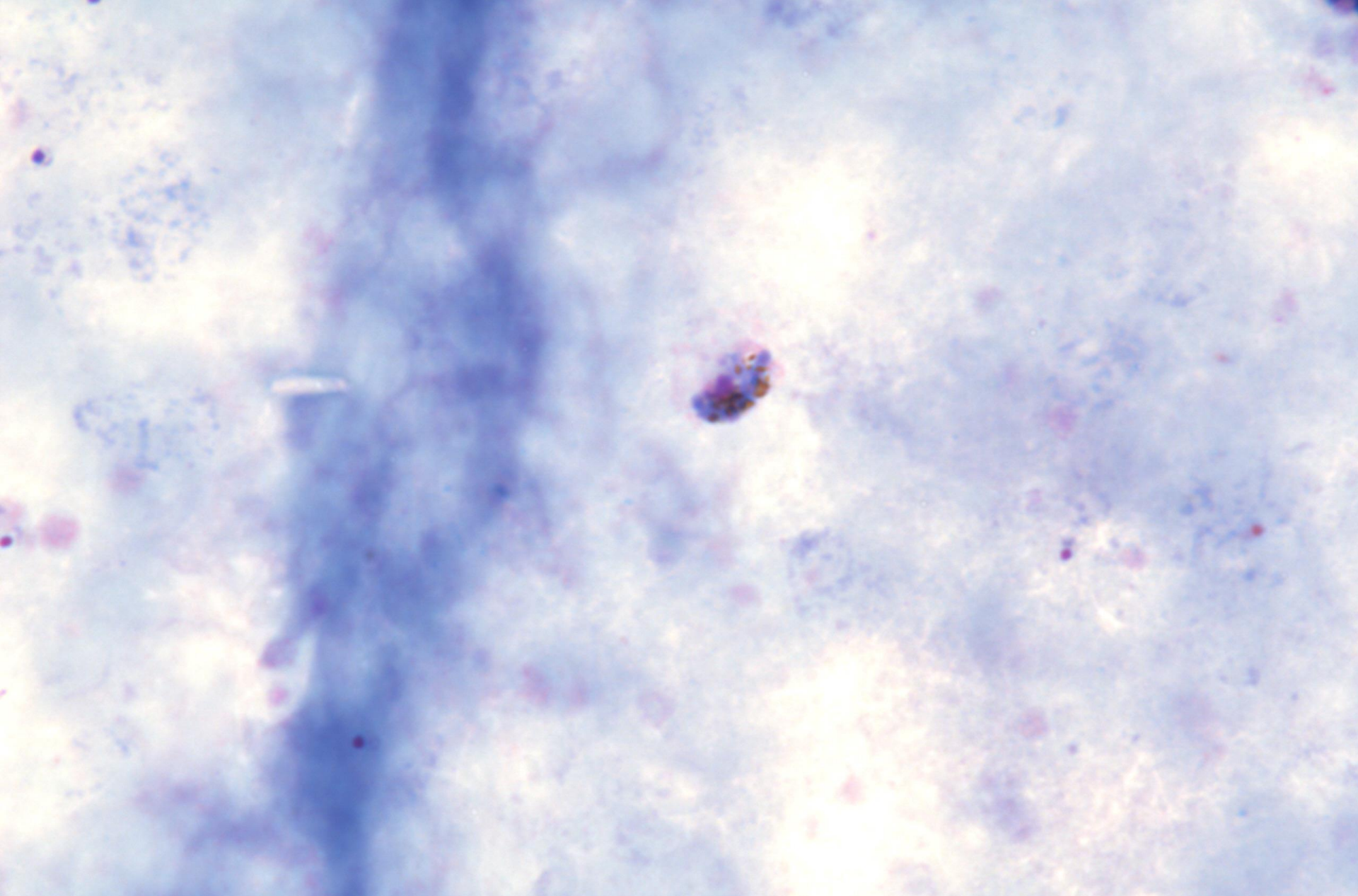
Stichting Kwaliteitsbewaking
Medische Laboratoriumdiagnostiek

Eric A.T. Brien

Dept Parasitology



Center for Infectious Diseases



SKML 2021.4B

Plasmodium falciparum \approx 0,1% (trophozoïtes)

Plasmodium ovale wallikeri (gametocyte)



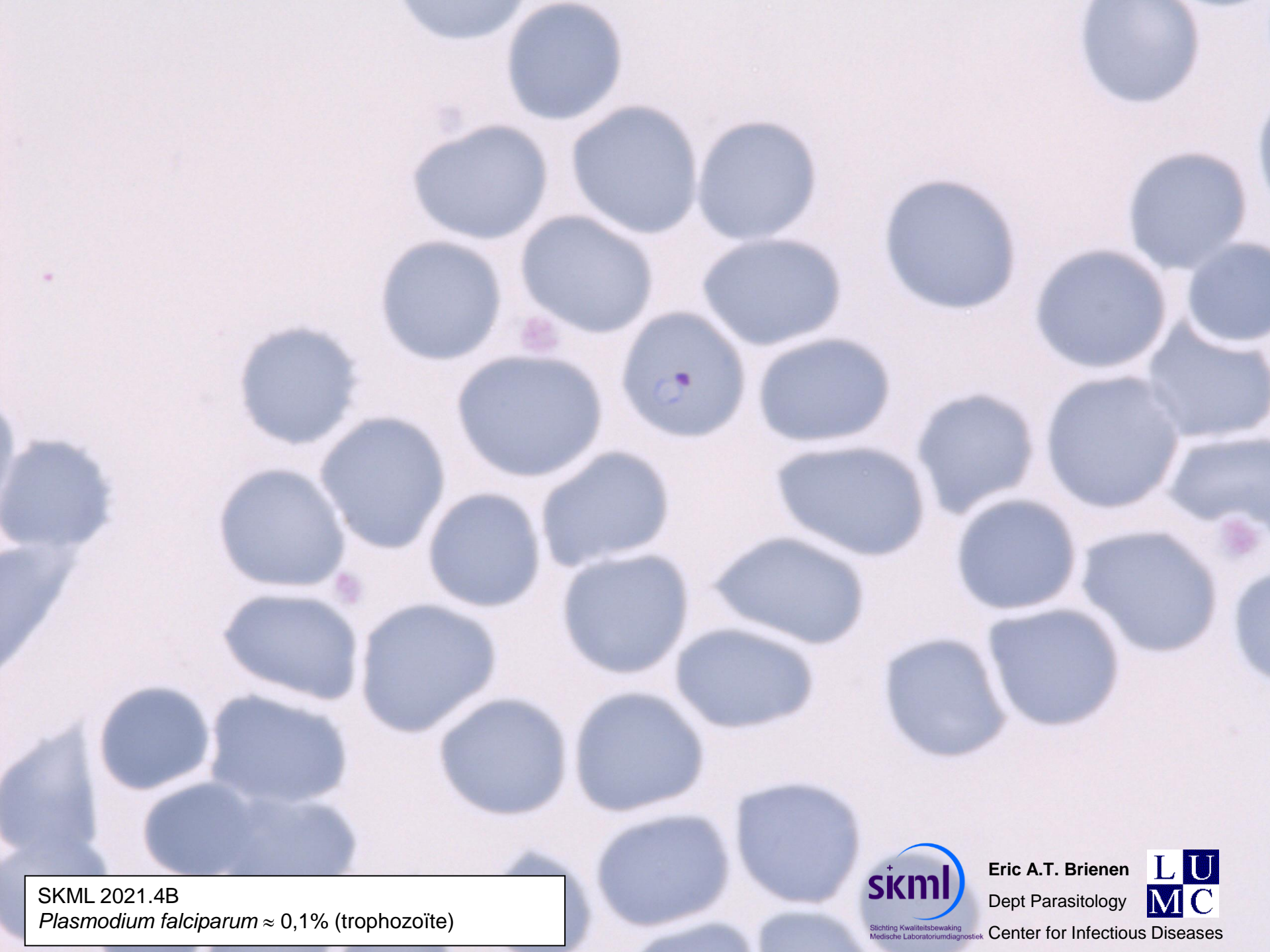
Stichting Kwaliteitsbewaking
Medische Laboratoriumdiagnostiek

Eric A.T. Brien

Dept Parasitology



Center for Infectious Diseases



SKML 2021.4B
Plasmodium falciparum ≈ 0,1% (trophozoïte)



Eric A.T. Brienen
Dept Parasitology



Center for Infectious Diseases



SKML 2021.1A
Giardia lamblia (cyst)

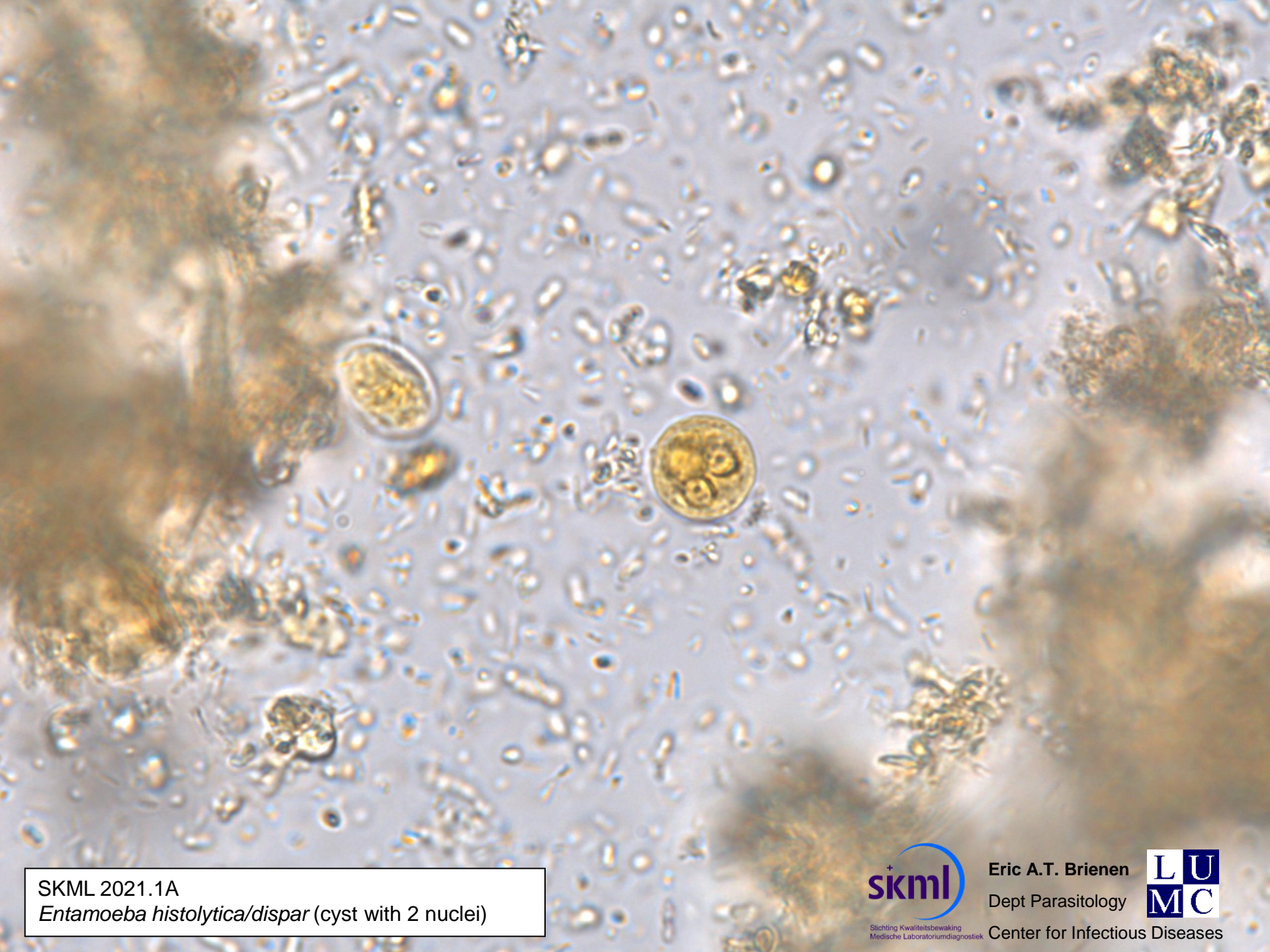


Stichting Kwaliteitsbewaking
Medische Laboratoriumdiagnostiek

Eric A.T. Brienens
Dept Parasitology

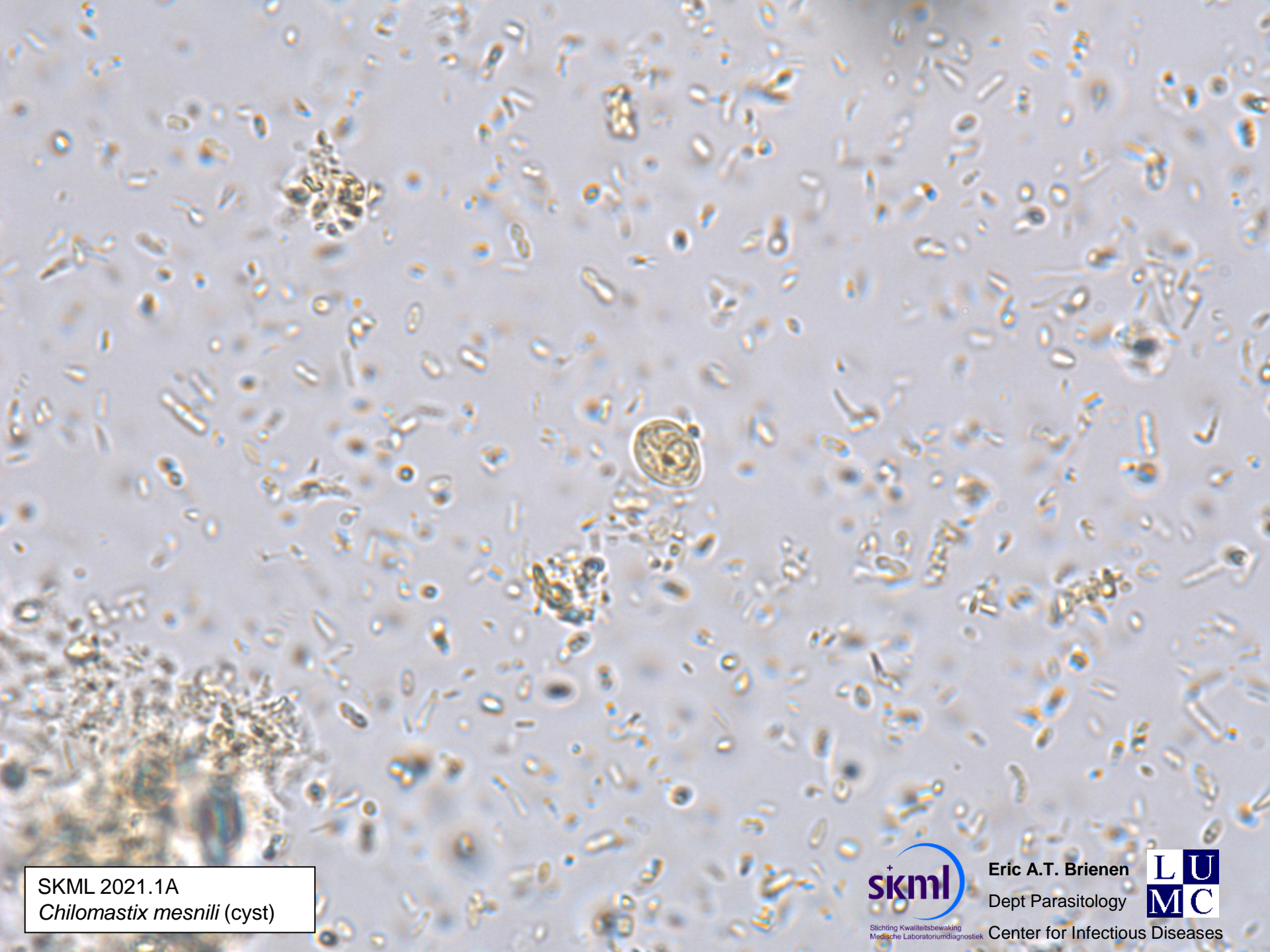


Center for Infectious Diseases



SKML 2021.1A

Entamoeba histolytica/dispar (cyst with 2 nuclei)



SKML 2021.1A
Chilomastix mesnili (cyst)

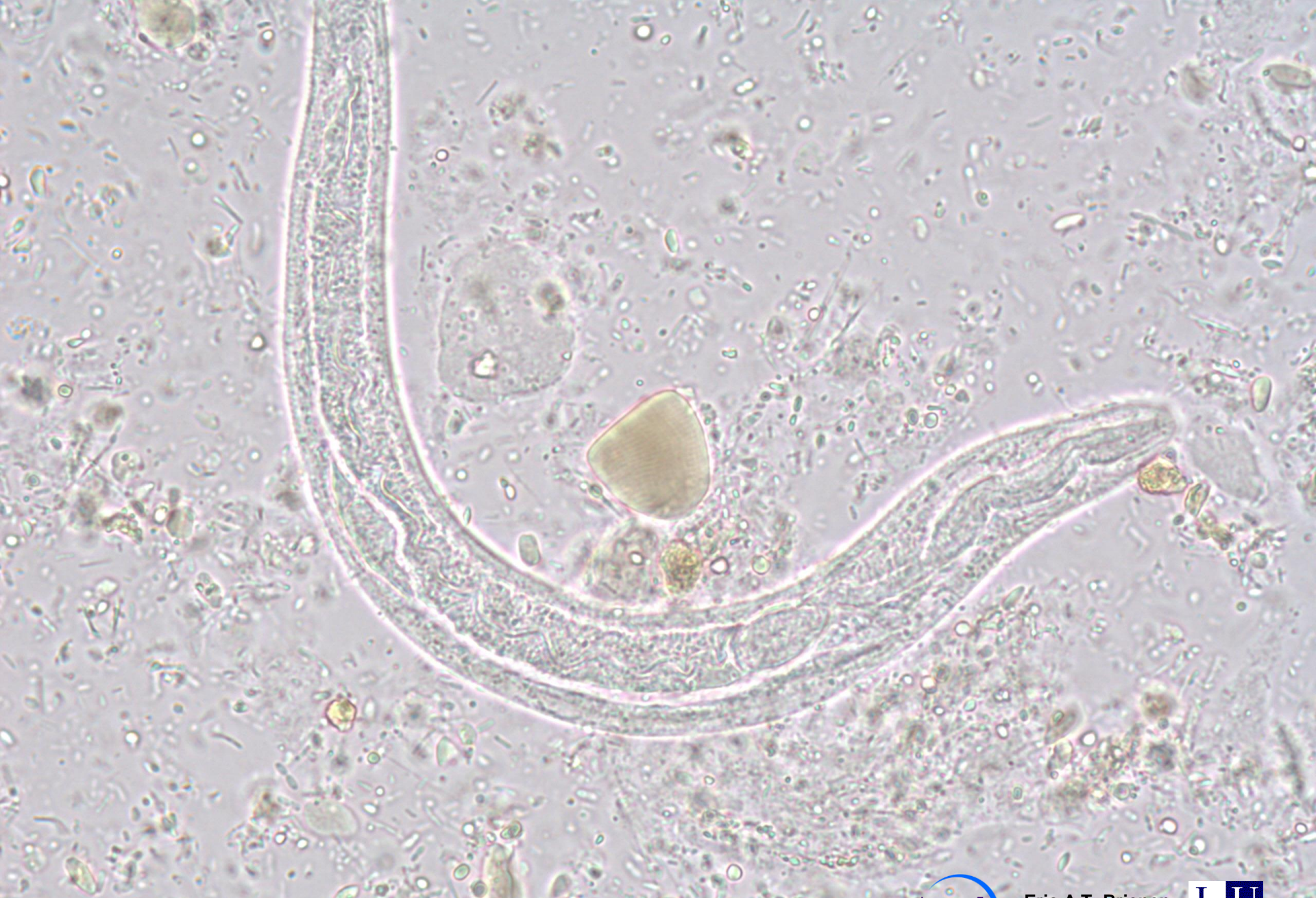

Stichting Kwaliteitsbewaking
Medische Laboratoriumdiagnostiek

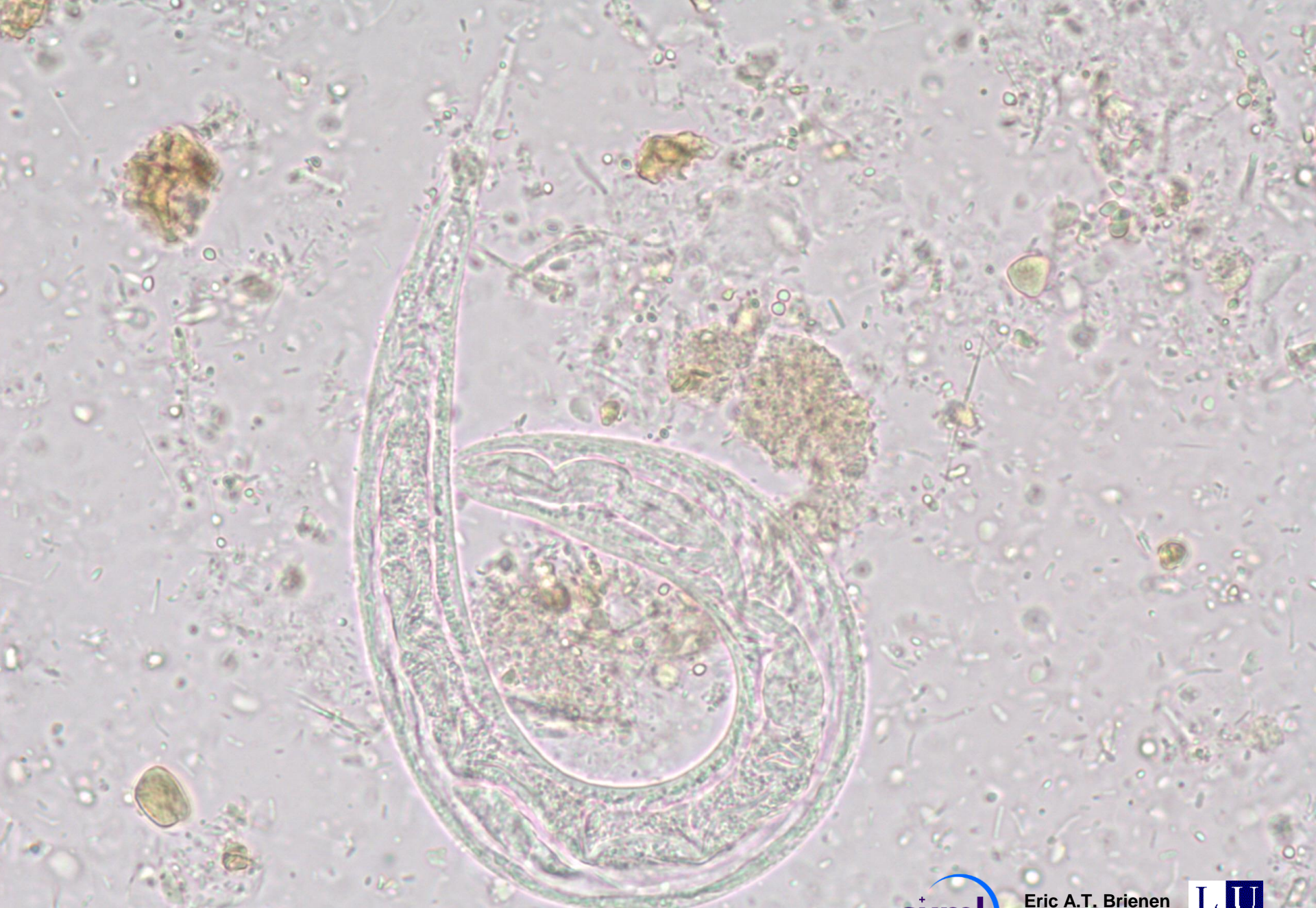Eric A.T. Brienens
Dept Parasitology



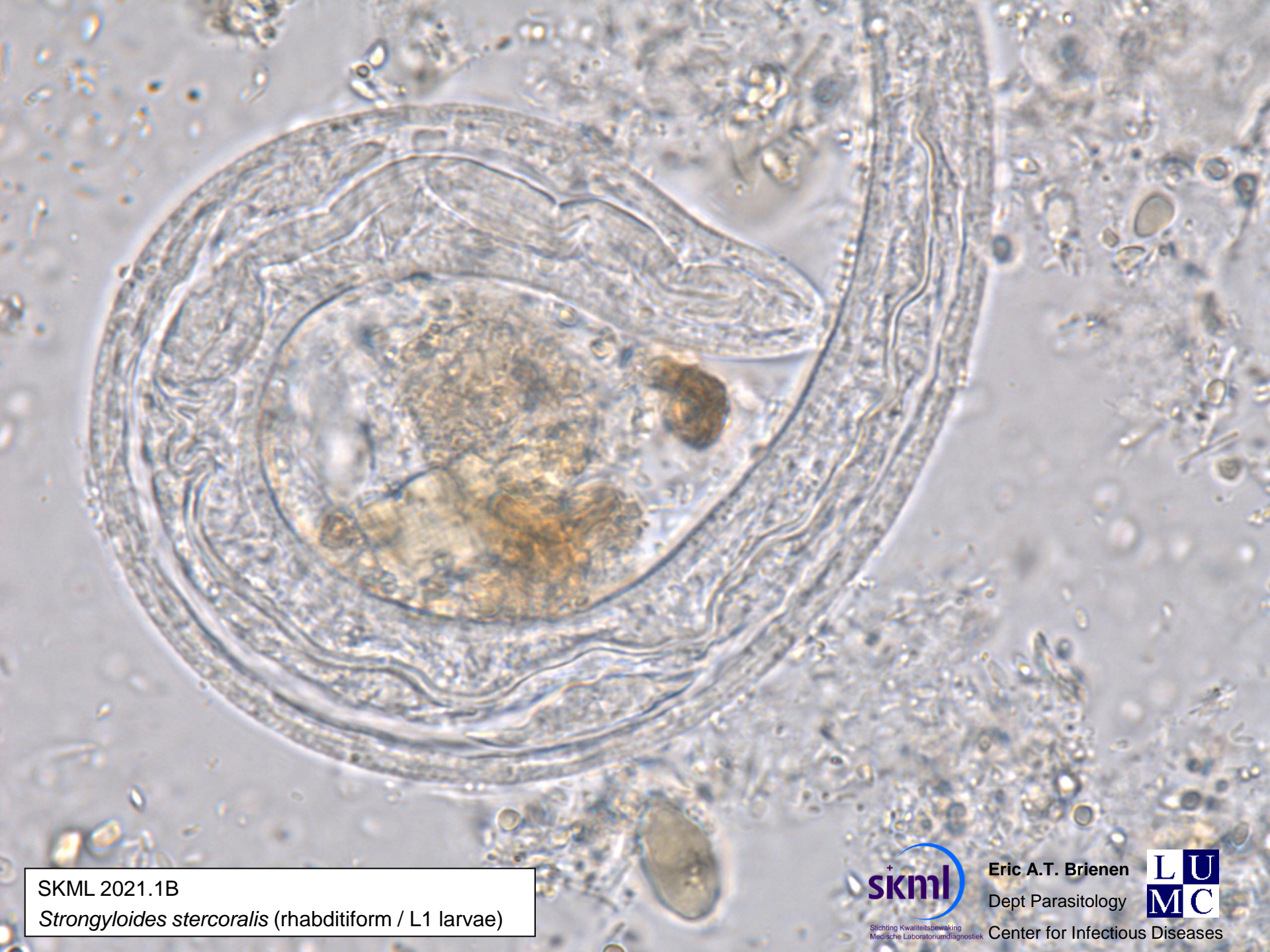Center for Infectious Diseases



SKML 2021.1B
Strongyloides stercoralis (rhabditiform / L1 larvae)



SKML 2021.1B
Strongyloides stercoralis (rhabditiform / L1 larva)



SKML 2021.1B

Strongyloides stercoralis (rhabditiform / L1 larvae)



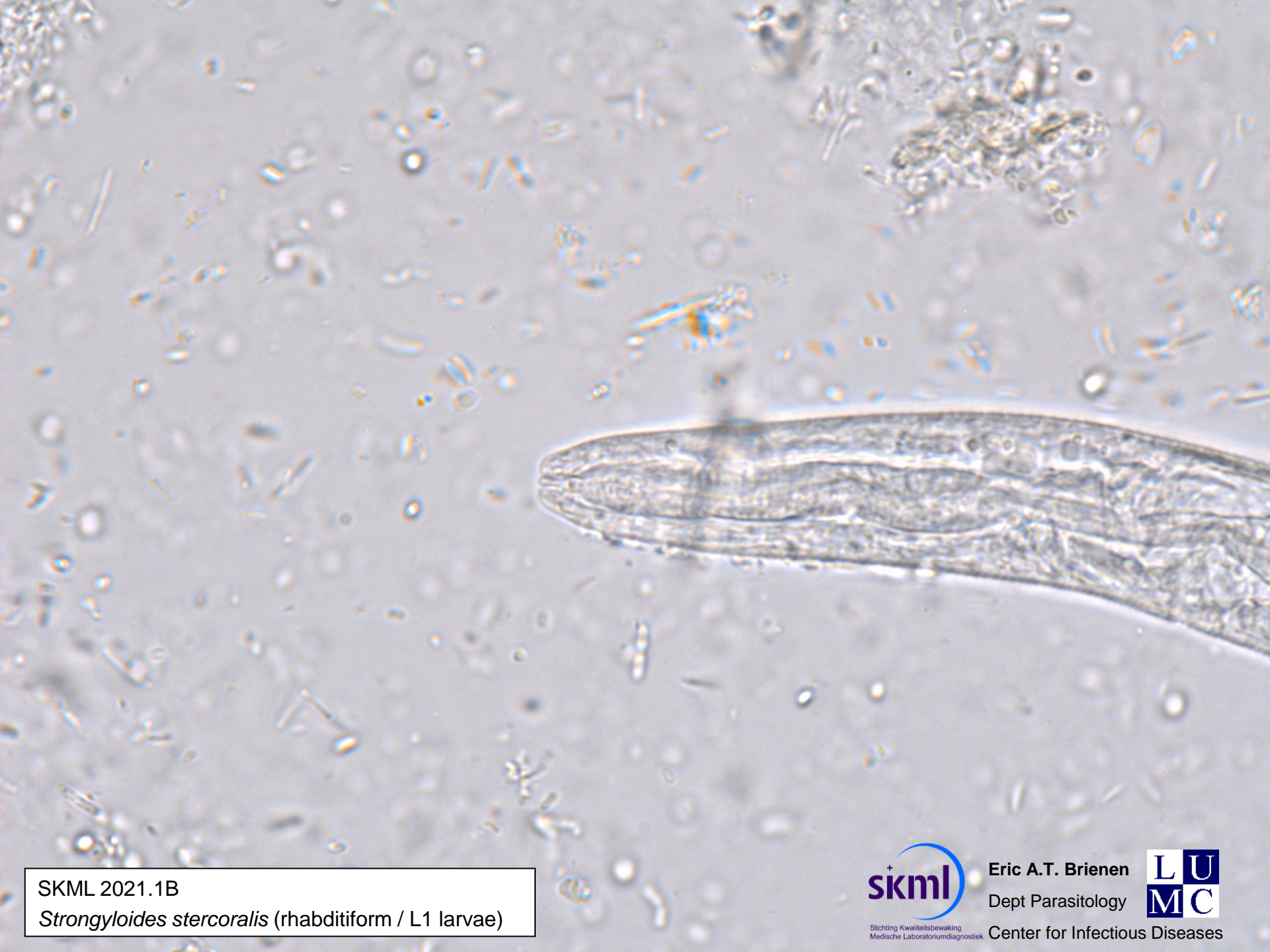Stichting Kwaliteitsbewaking
Medische Laboratoriumdiagnostiek

Eric A.T. Brien

Dept Parasitology



Center for Infectious Diseases



SKML 2021.1B

Strongyloides stercoralis (rhabditiform / L1 larvae)



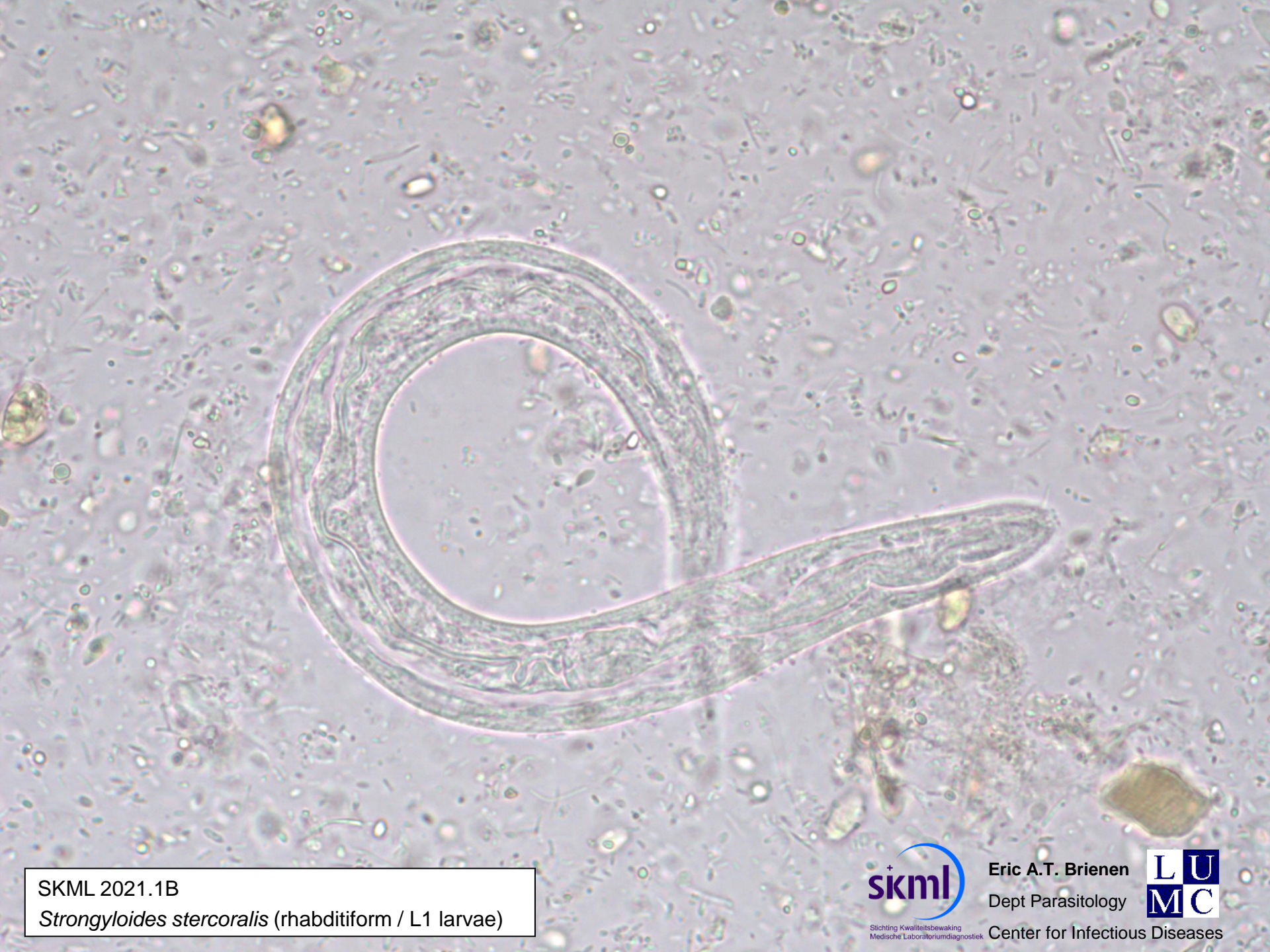Stichting Kwaliteitsbewaking
Medische Laboratoriumdiagnostiek

Eric A.T. Brien

Dept Parasitology



Center for Infectious Diseases



SKML 2021.1B

Strongyloides stercoralis (rhabditiform / L1 larvae)

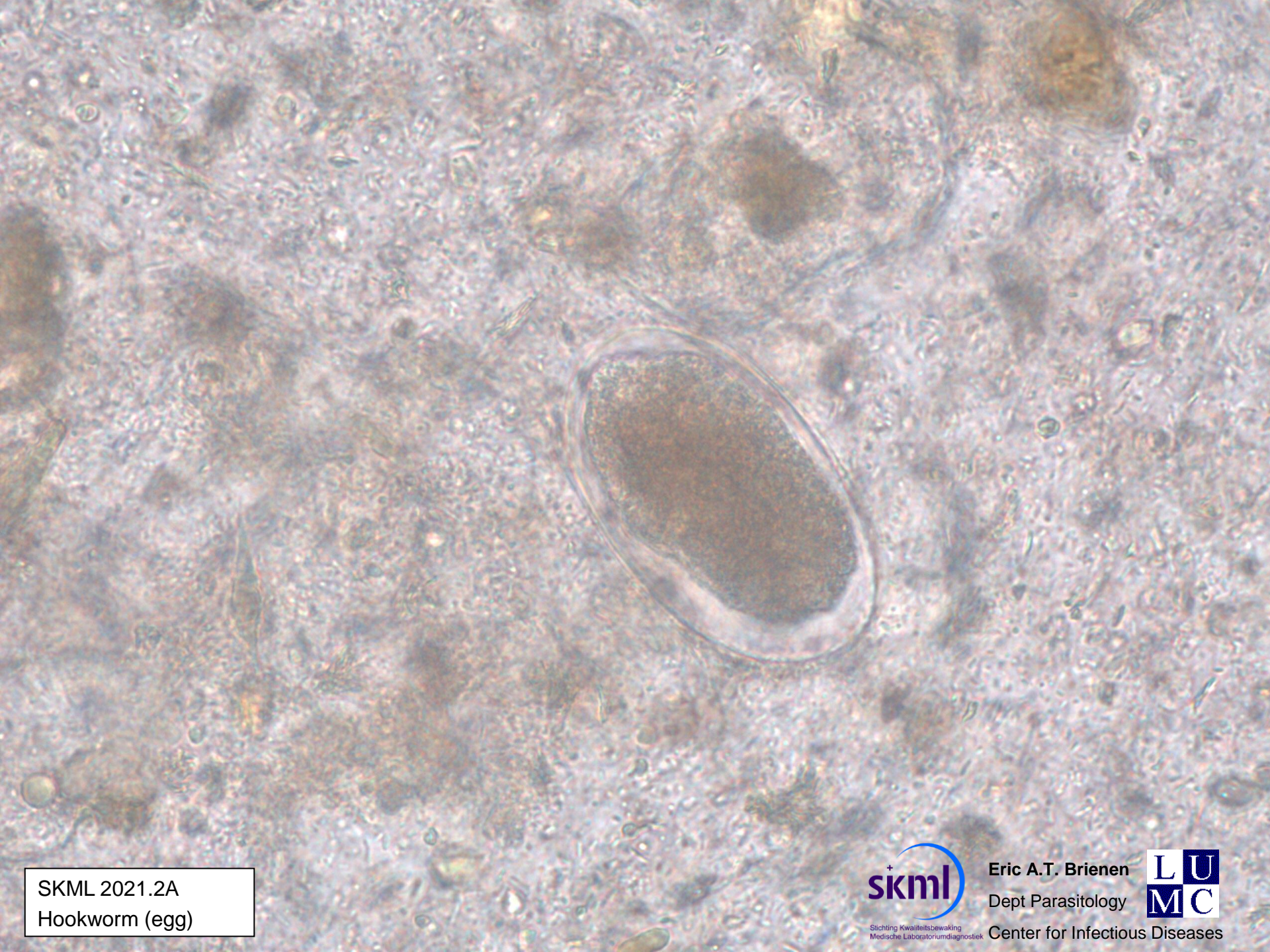


Stichting Kwaliteitsbewaking
Medische Laboratoriumdiagnostiek

Eric A.T. Brienen
Dept Parasitology



Center for Infectious Diseases



SKML 2021.2A
Hookworm (egg)

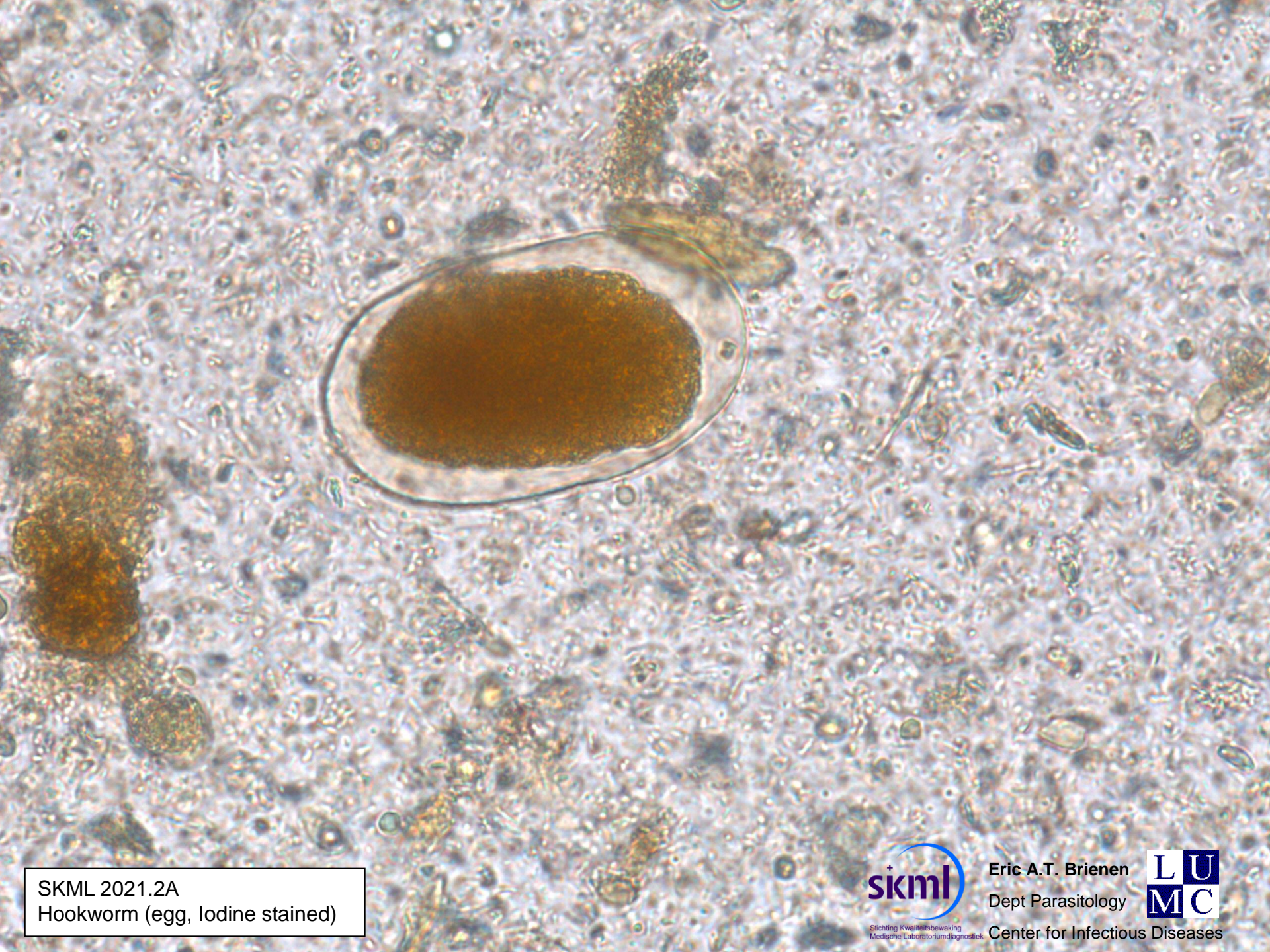


Stichting Kwaliteitsbewaking
Medische Laboratoriumdiagnostiek

Eric A.T. Brienen
Dept Parasitology



Center for Infectious Diseases



SKML 2021.2A
Hookworm (egg, iodine stained)

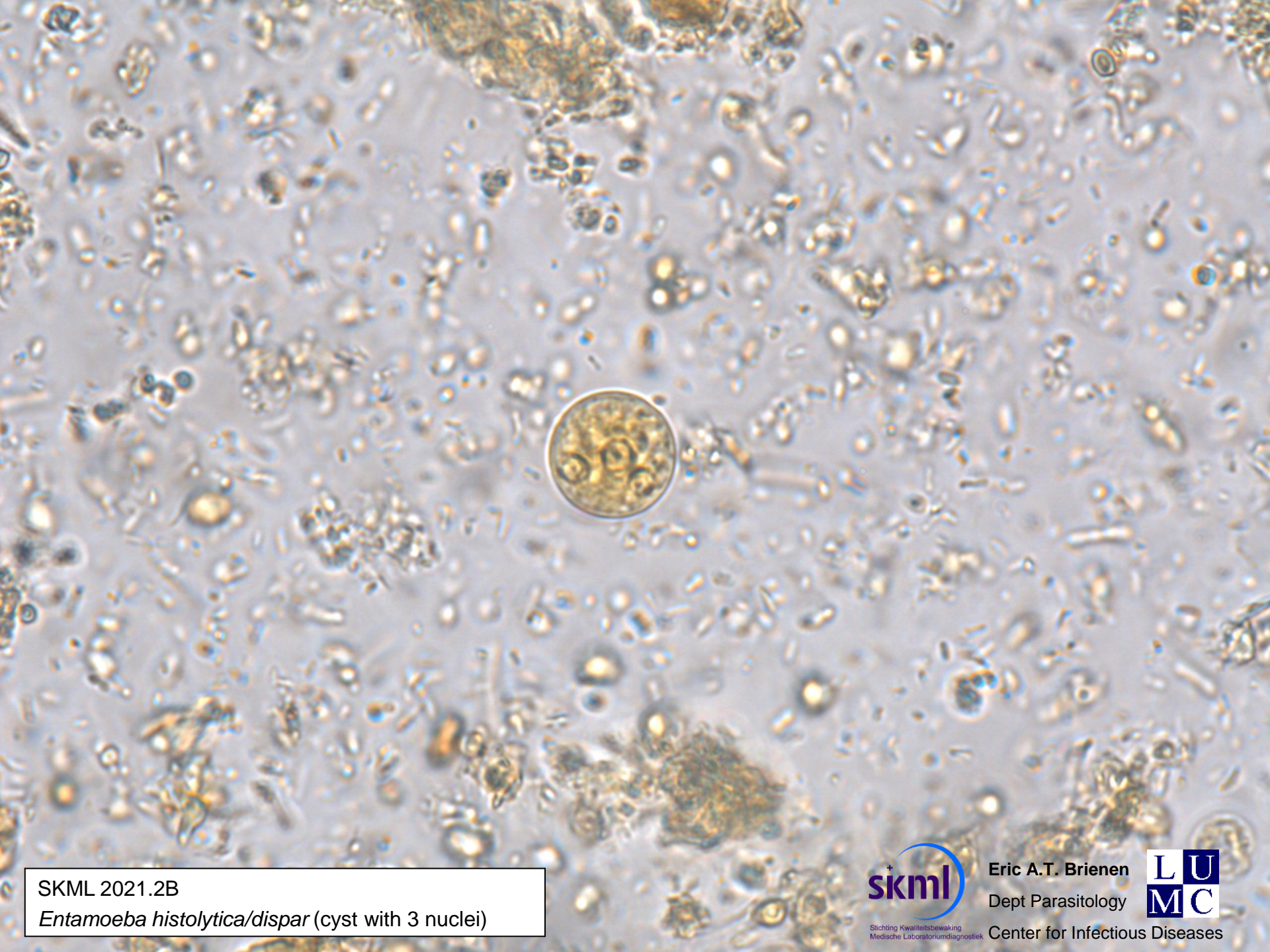


Stichting Kwaliteitsbewaking
Medische Laboratoriumdiagnostiek

Eric A.T. Brienen
Dept Parasitology



Center for Infectious Diseases



SKML 2021.2B

Entamoeba histolytica/dispar (cyst with 3 nuclei)

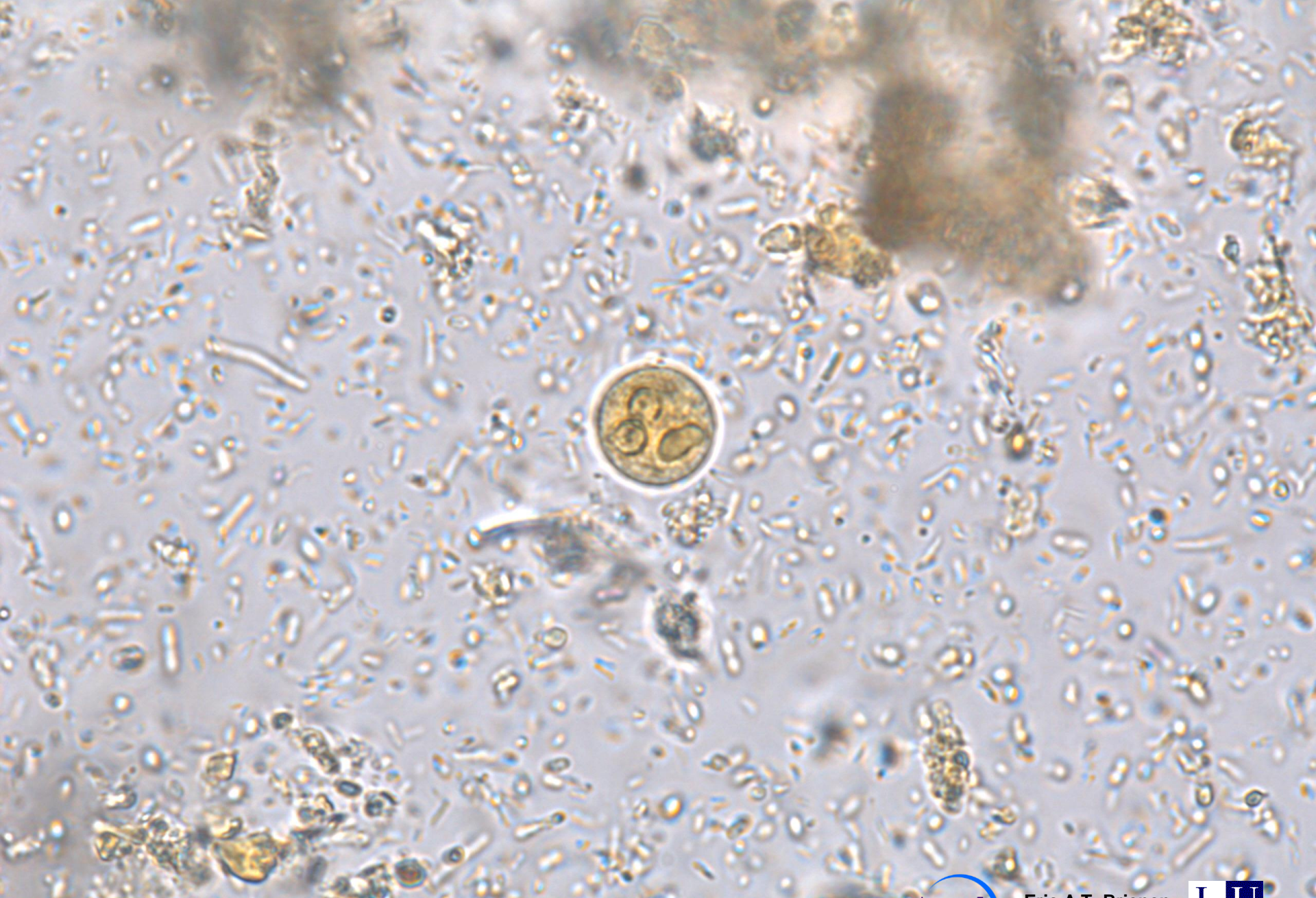


Stichting Kwaliteitsbewaking
Medische Laboratoriumdiagnostiek

Eric A.T. Brienen
Dept Parasitology



Center for Infectious Diseases



SKML 2021.2B

Entamoeba histolytica/dispar (cyst with chromatoid body and 2 nuclei)



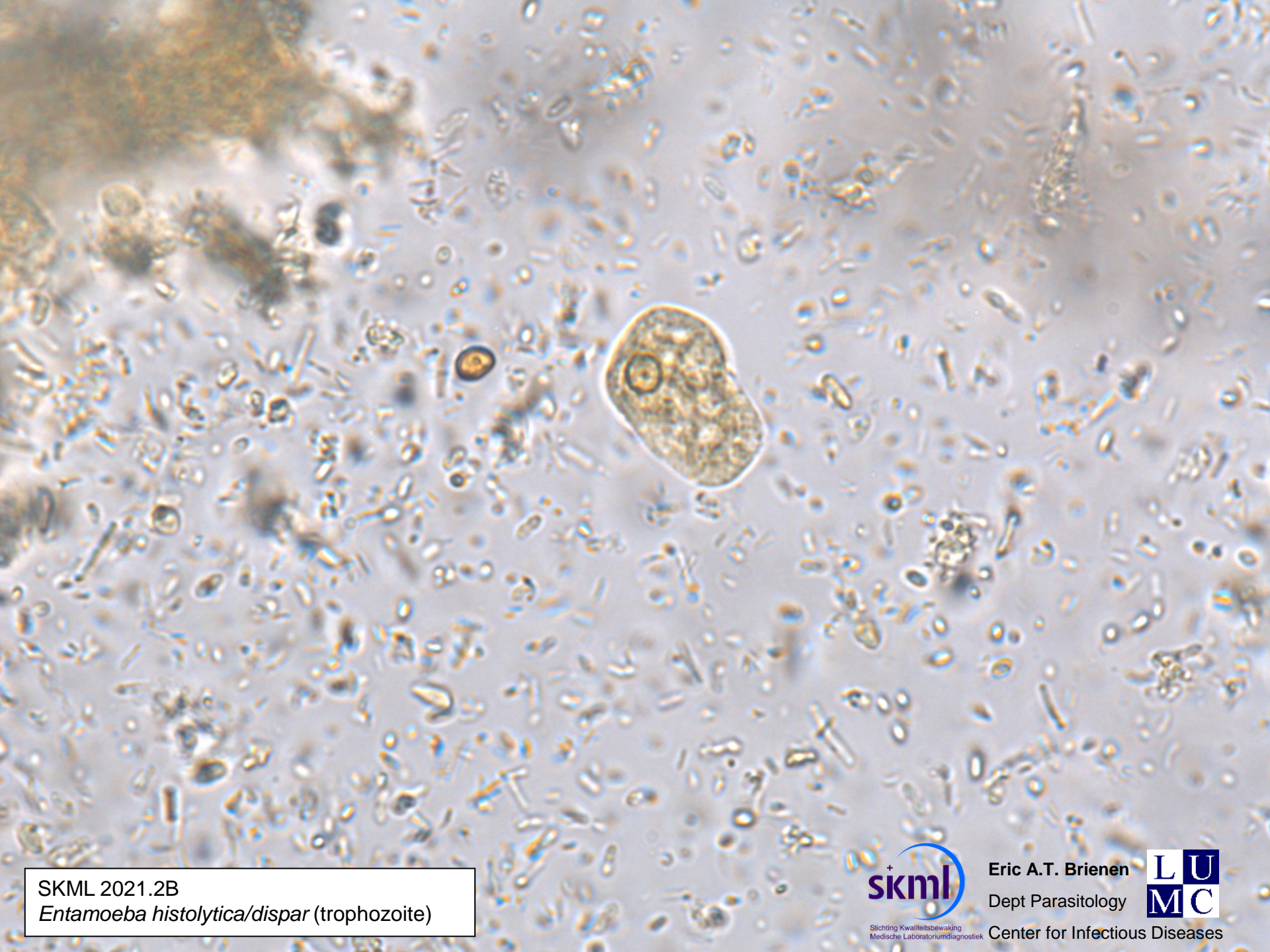Stichting Kwaliteitsbewaking
Medische Laboratoriumdiagnostiek

Eric A.T. Brien

Dept Parasitology



Center for Infectious Diseases



SKML 2021.2B

Entamoeba histolytica/dispar (trophozoite)



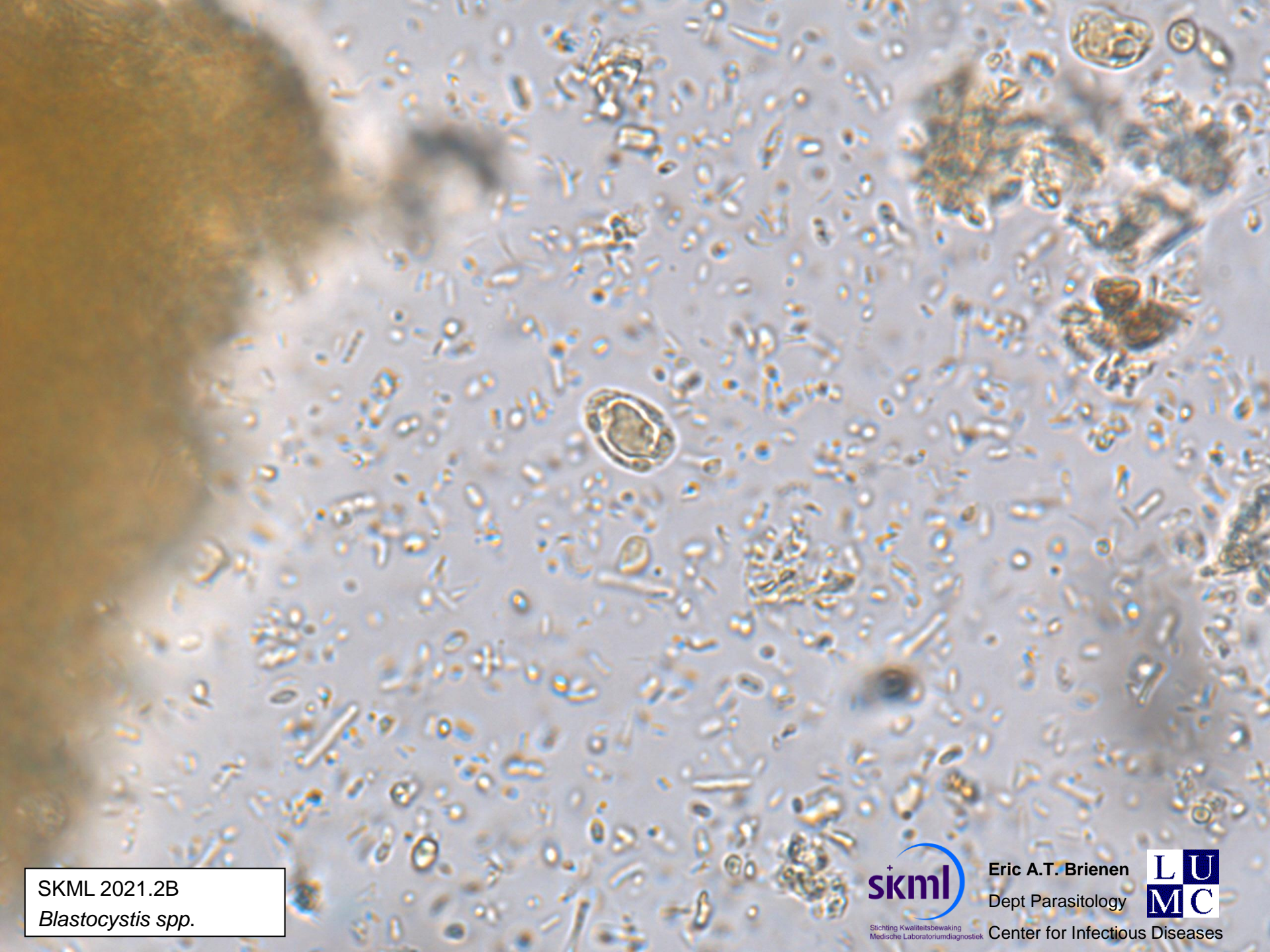
Stichting Kwaliteitsbewaking
Medische Laboratoriumdiagnostiek

Eric A.T. Brienen

Dept Parasitology



Center for Infectious Diseases



SKML 2021.2B
Blastocystis spp.

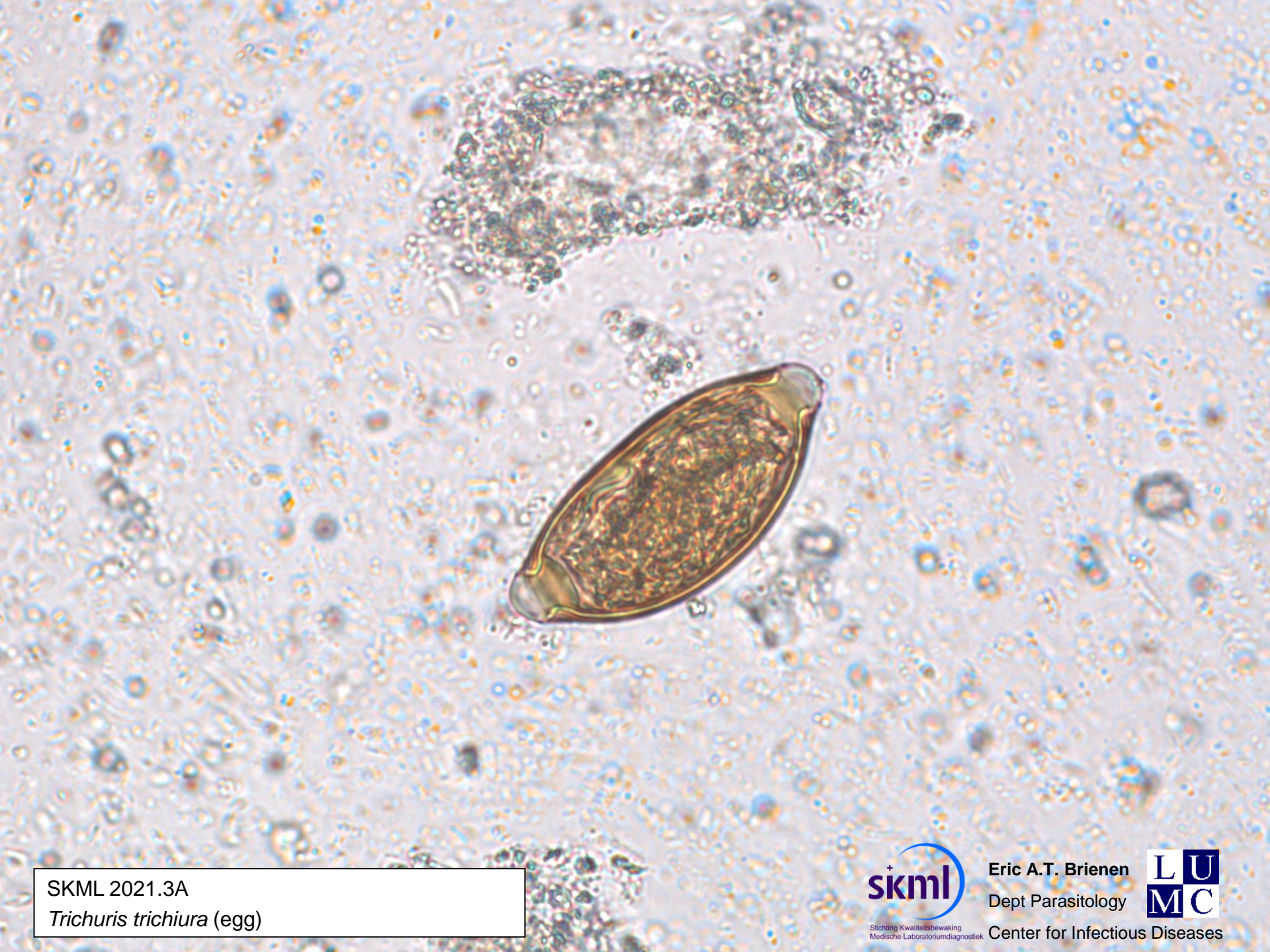


Stichting Kwaliteitsbewaking
Medische Laboratoriumdiagnostiek

Eric A.T. Brienen
Dept Parasitology



Center for Infectious Diseases



SKML 2021.3A

Trichuris trichiura (egg)

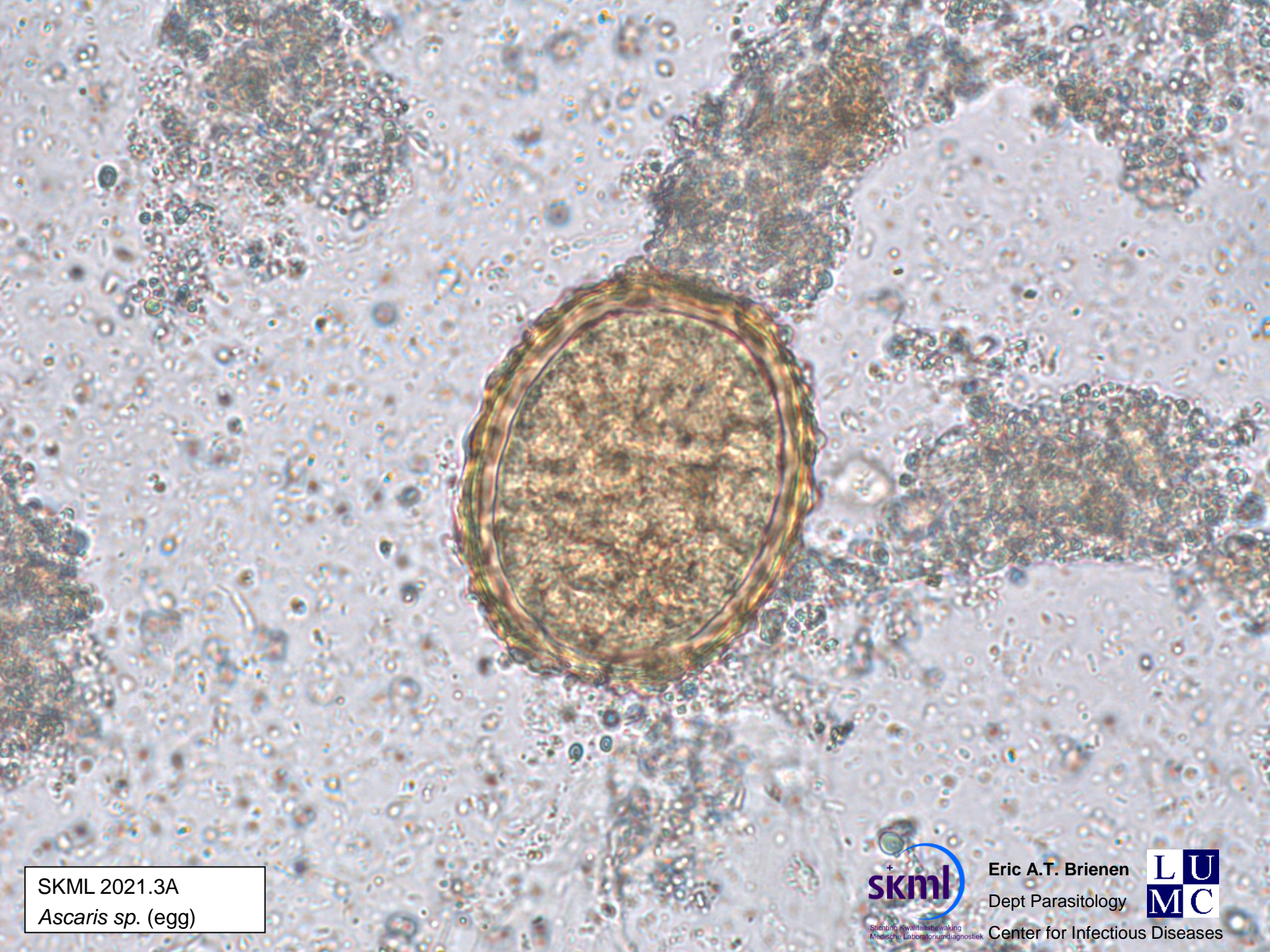


Stichting Kwaliteitsbewaking
Medische Laboratoriumdiagnostiek

Eric A.T. Brienen
Dept Parasitology



Center for Infectious Diseases



SKML 2021.3A
Ascaris sp. (egg)

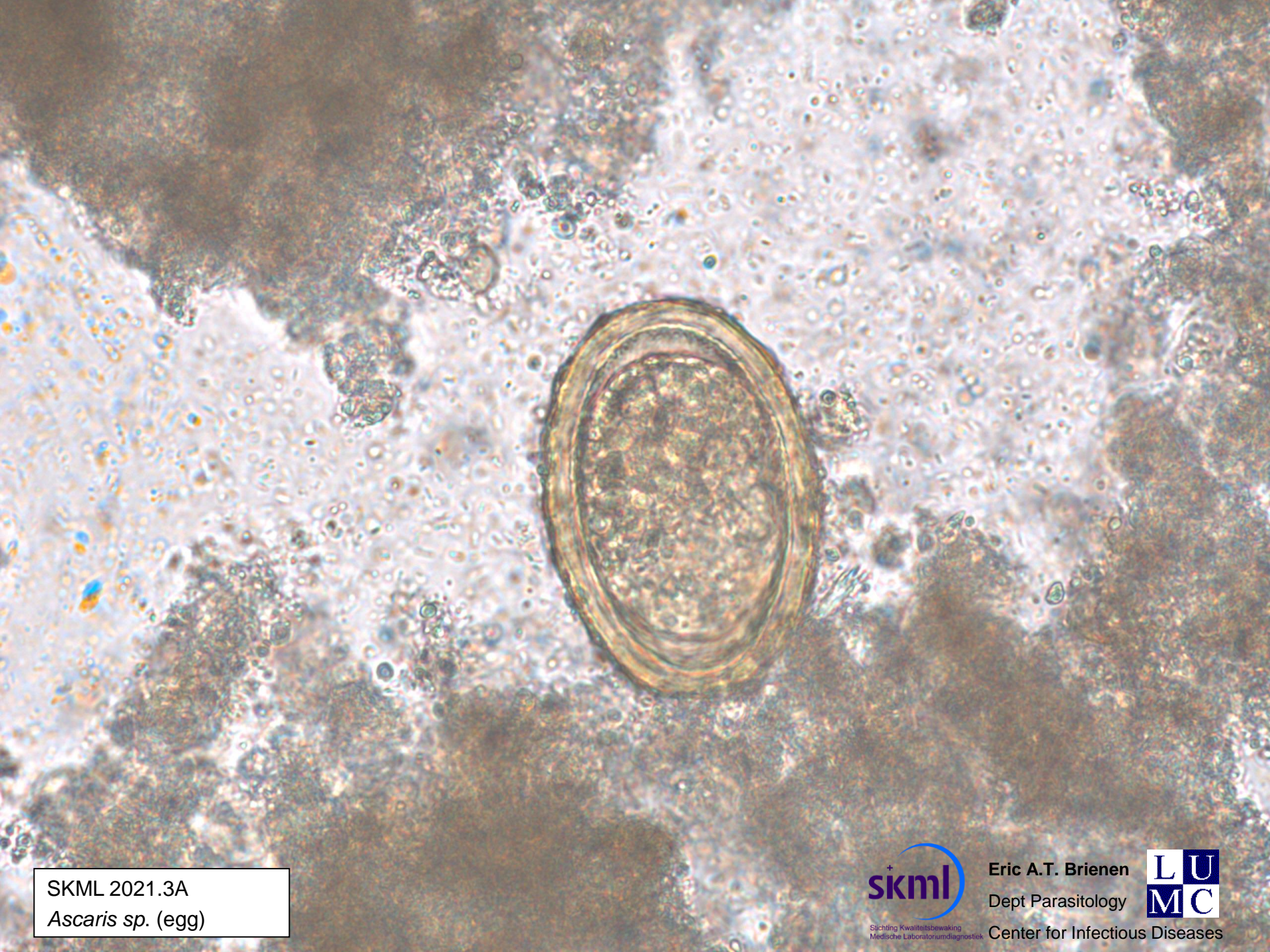


Streeklaboratorium voor
Kwaliteitsbewaking
Medische Laboratoriumdiagnostiek

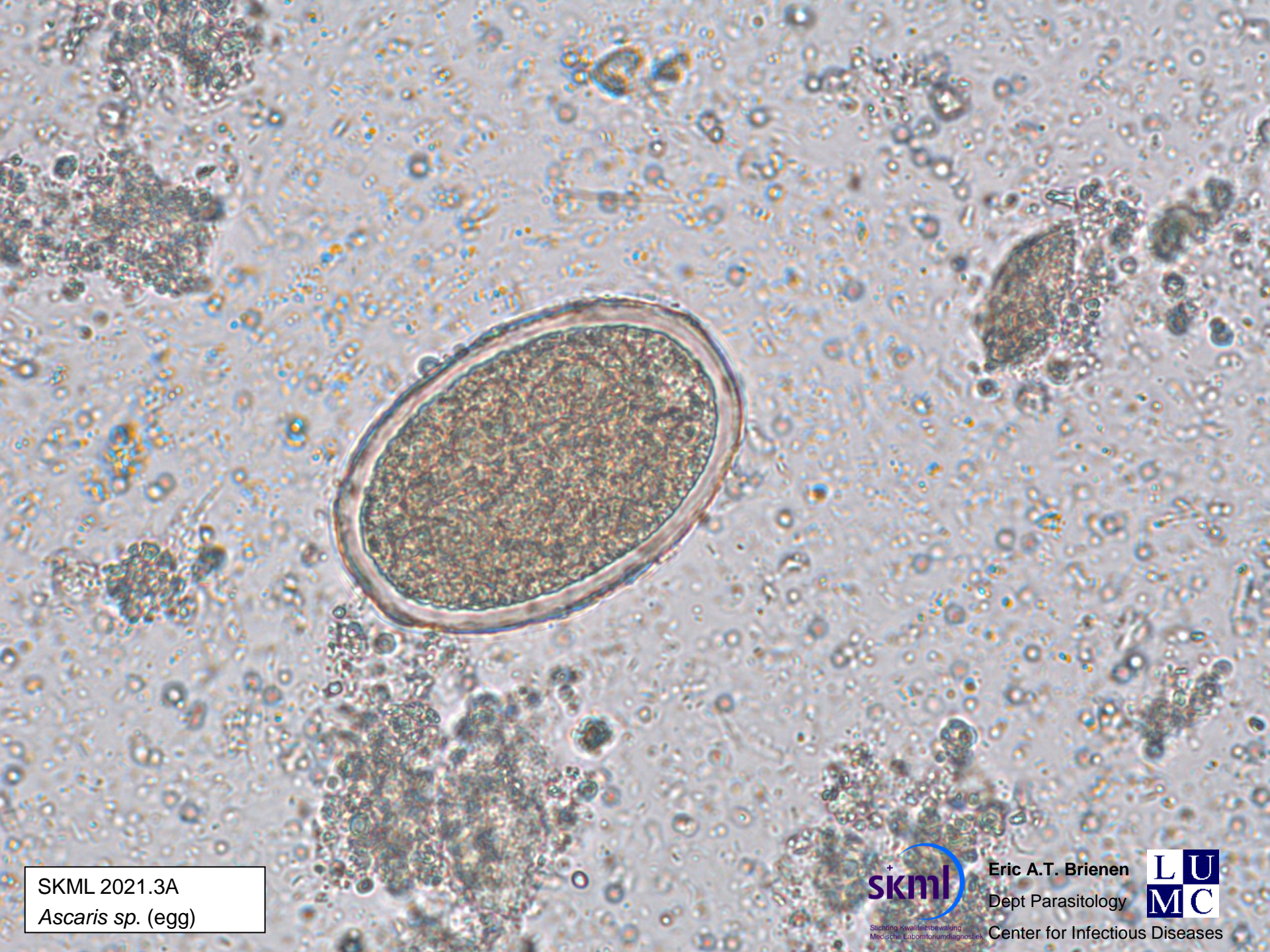Eric A.T. Brienen
Dept Parasitology



Center for Infectious Diseases



SKML 2021.3A
Ascaris sp. (egg)



SKML 2021.3A
Ascaris sp. (egg)

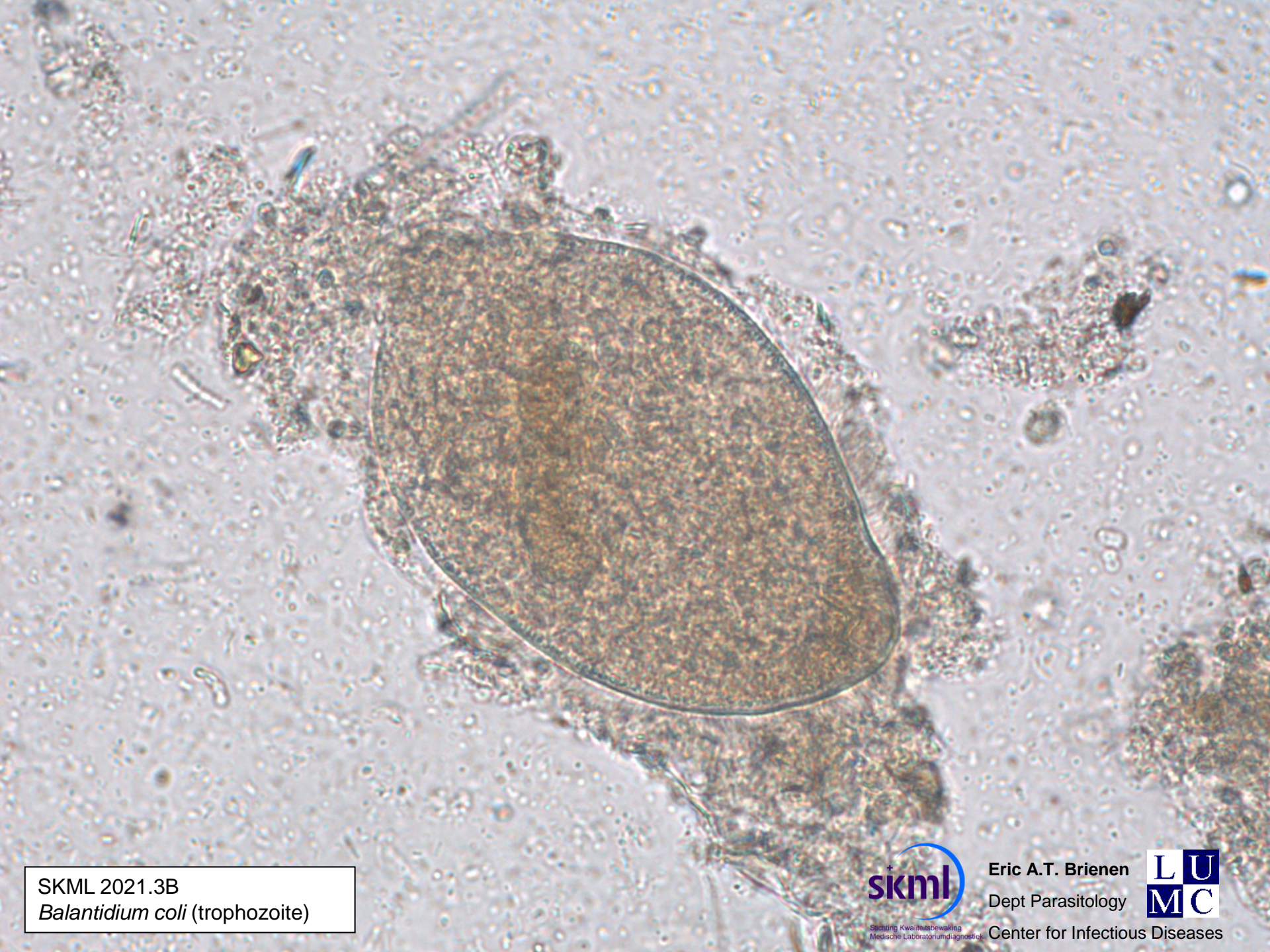


Stichting Kwaliteitsbewaking
Medische Laboratoriumdiagnostiek

Eric A.T. Brienen
Dept Parasitology



Center for Infectious Diseases



SKML 2021.3B
Balantidium coli (trophozoite)

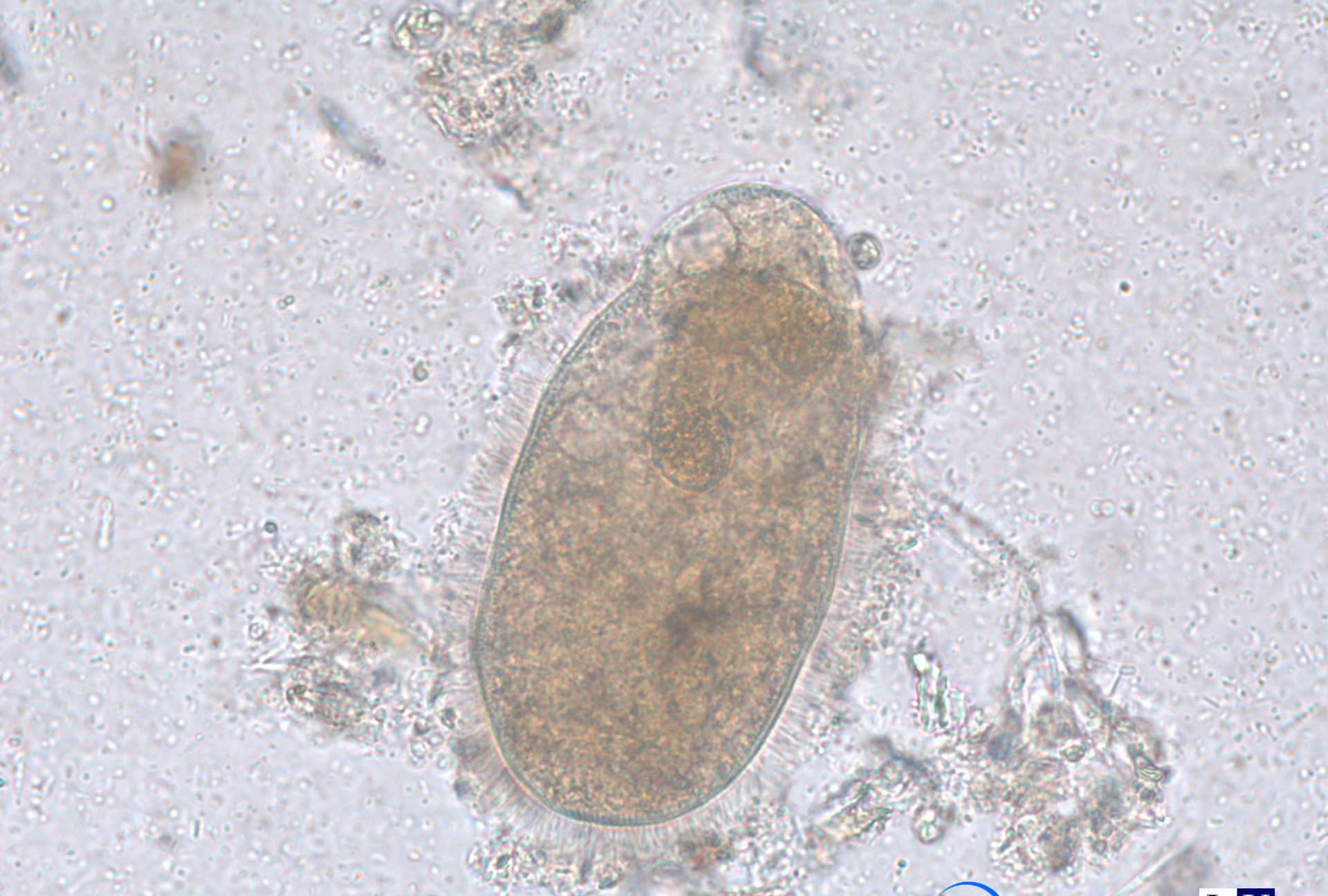

Stichting Kwaliteitsbewaking
Medische Laboratoriumdiagnostiek

Eric A.T. Brien
Dept Parasitology



Center for Infectious Diseases



SKML 2021.3B
Balantidium coli (trophozoite)

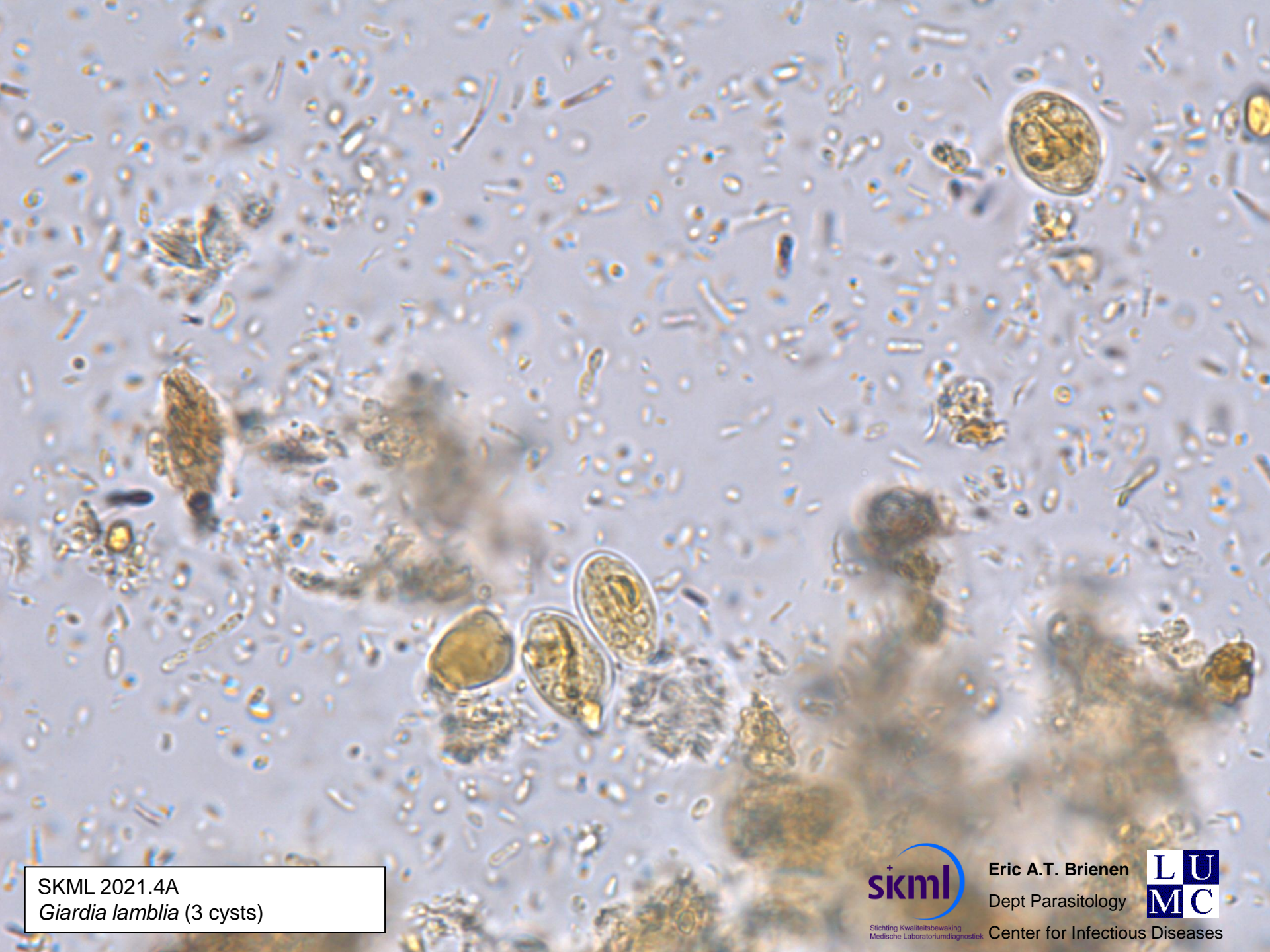


Stichting Kwaliteitsbewaking
Medische Laboratoriumdiagnostiek

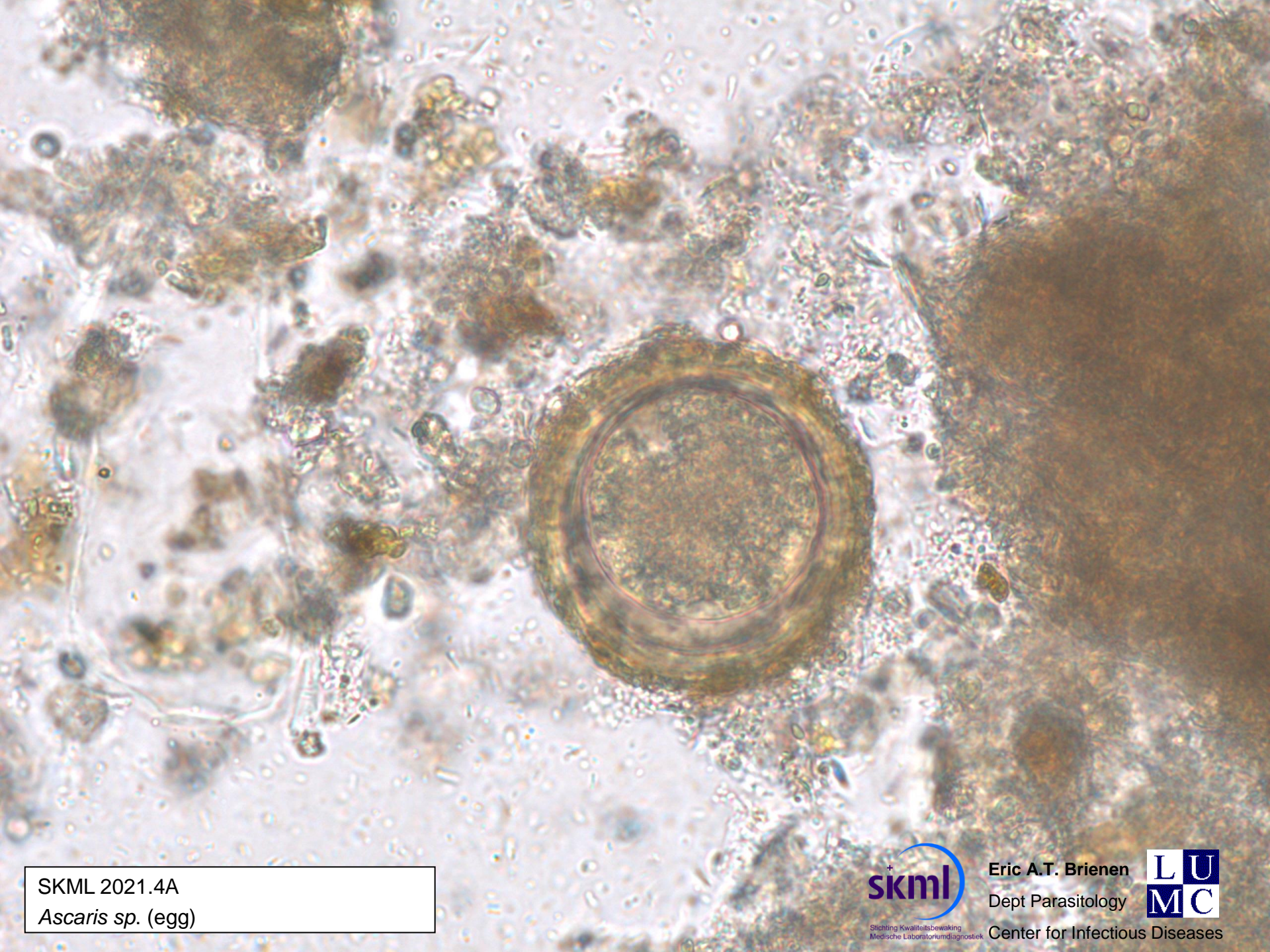
Eric A.T. Brien
Dept Parasitology



Center for Infectious Diseases



SKML 2021.4A
Giardia lamblia (3 cysts)



SKML 2021.4A
Ascaris sp. (egg)

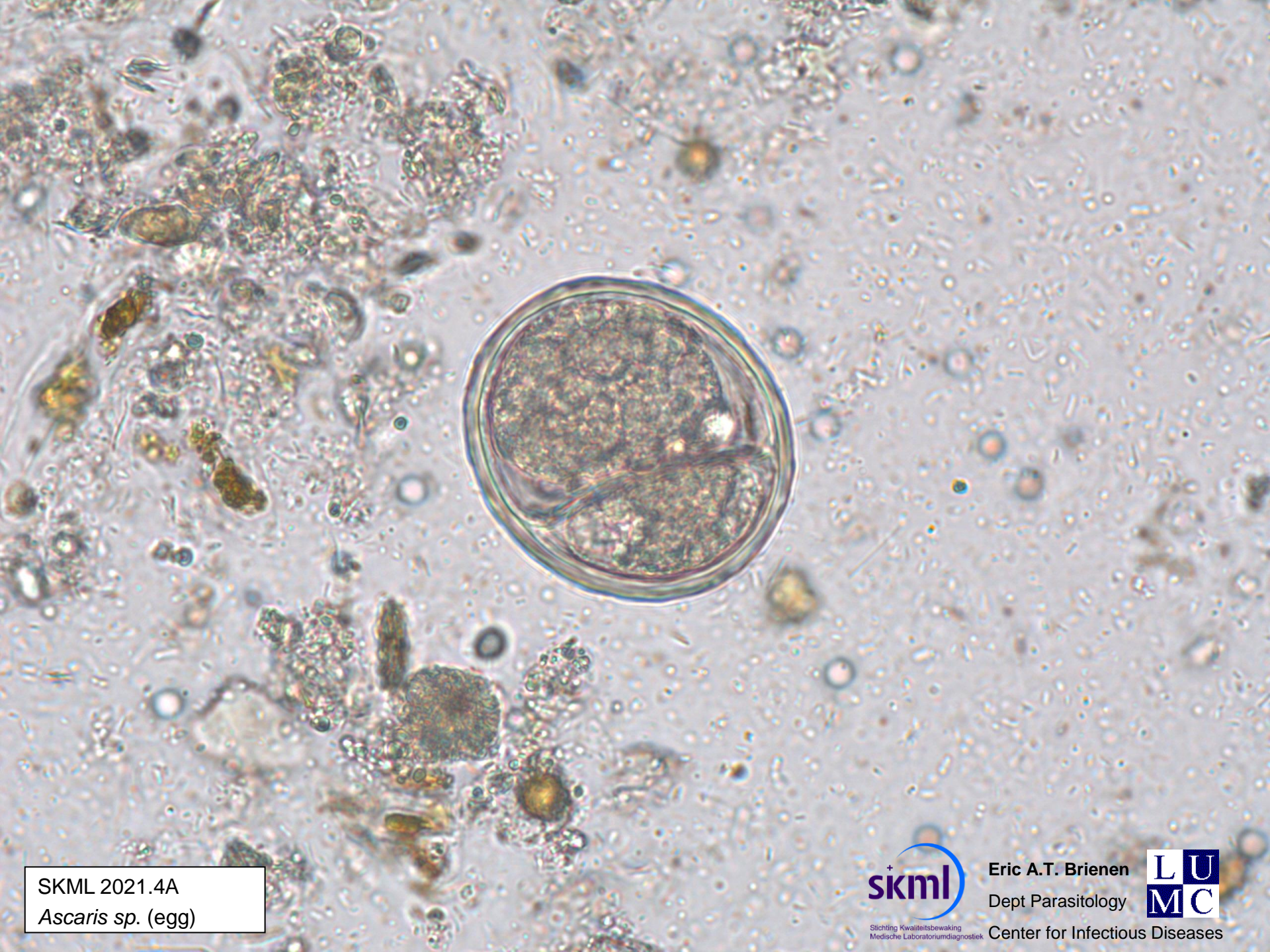

Stichting Kwaliteitsbewaking
Medische Laboratoriumdiagnostiek

Eric A.T. Brienen
Dept Parasitology



Center for Infectious Diseases



SKML 2021.4A
Ascaris sp. (egg)

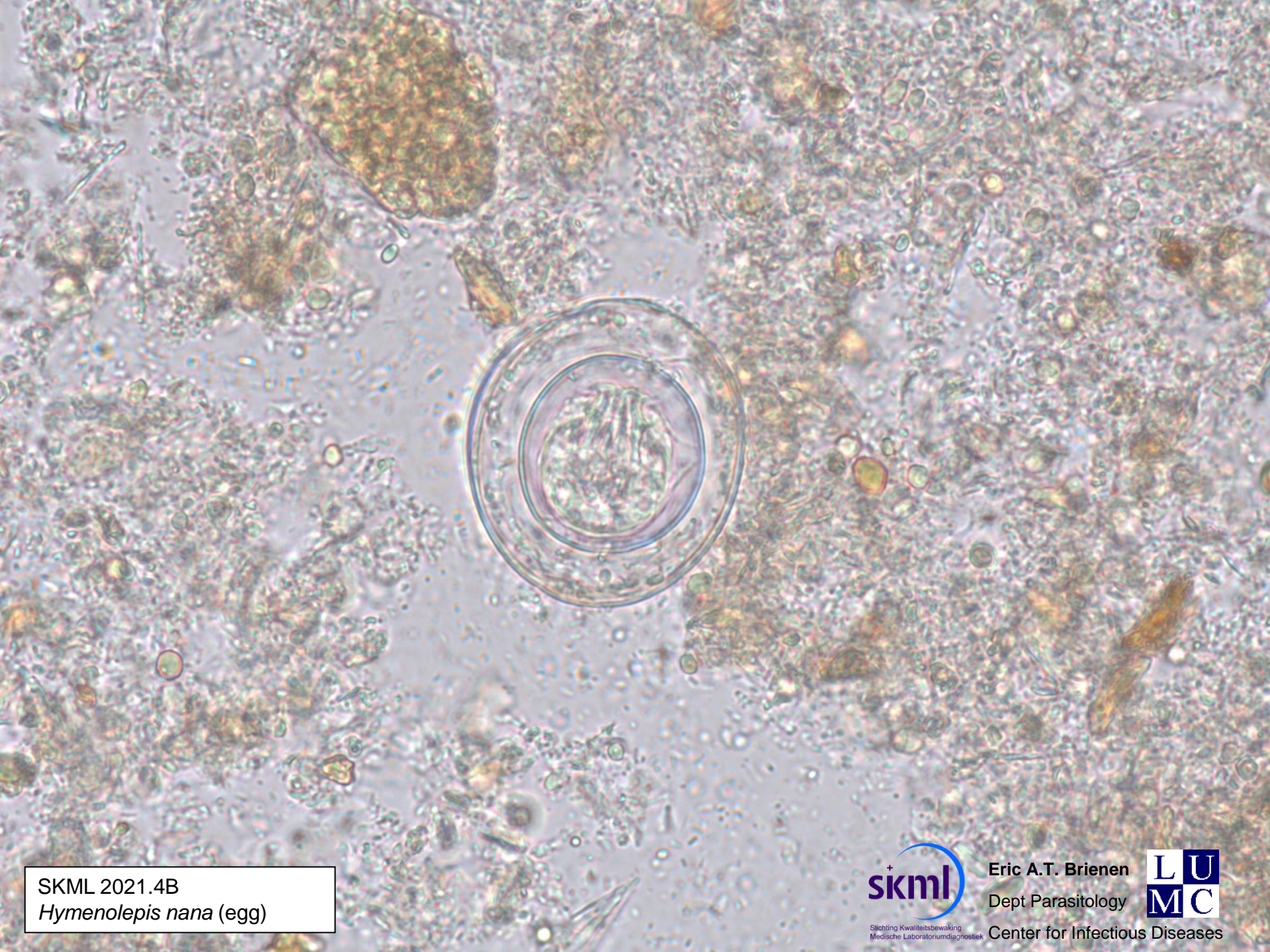


Stichting Kwaliteitsbewaking
Medische Laboratoriumdiagnostiek

Eric A.T. Brien
Dept Parasitology



Center for Infectious Diseases



SKML 2021.4B
Hymenolepis nana (egg)

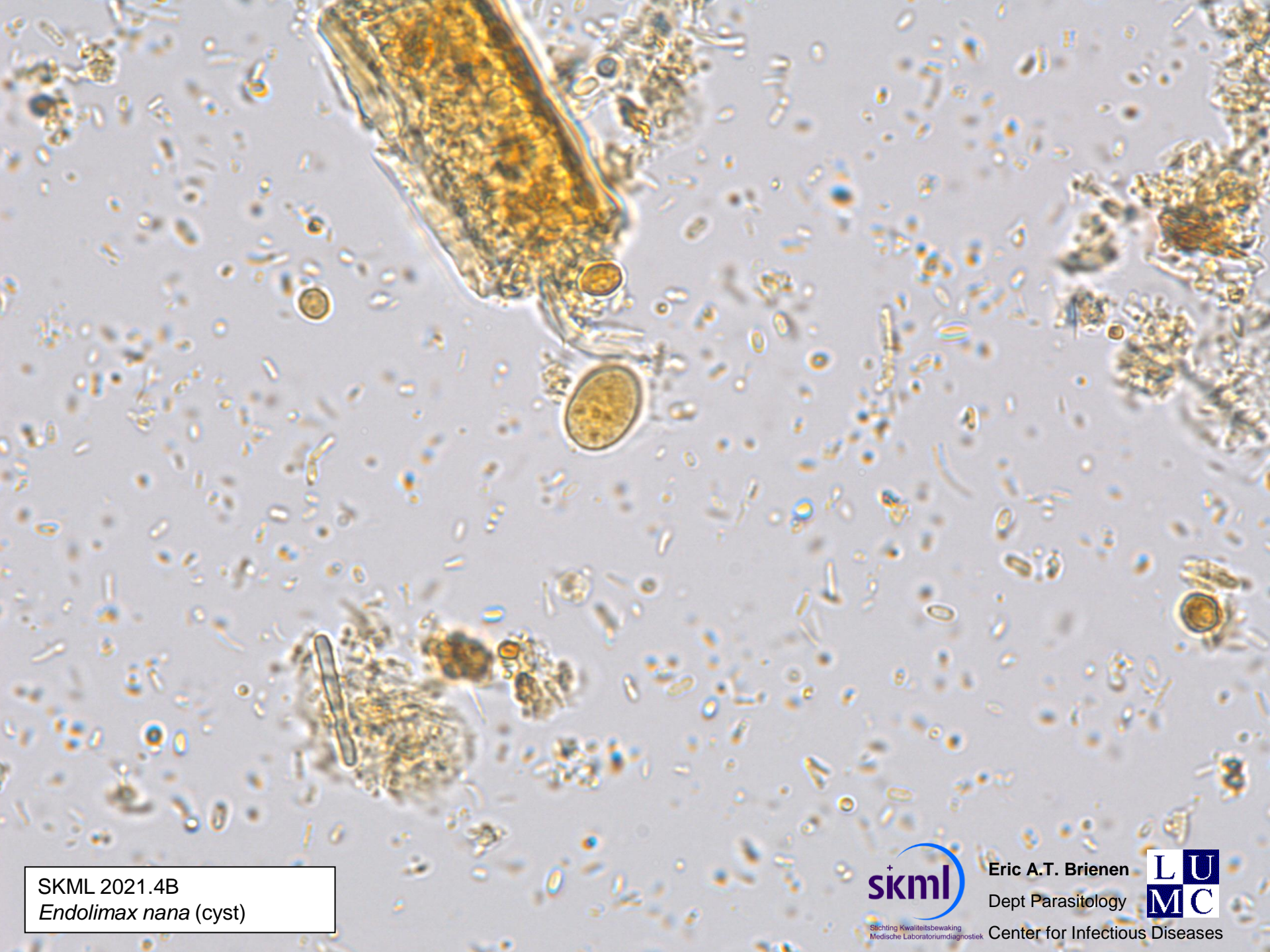


Stichting Kwaliteitsbewaking
Medische Laboratoriumdiagnostiek

Eric A.T. Brienens
Dept Parasitology



Center for Infectious Diseases



SKML 2021.4B
Endolimax nana (cyst)

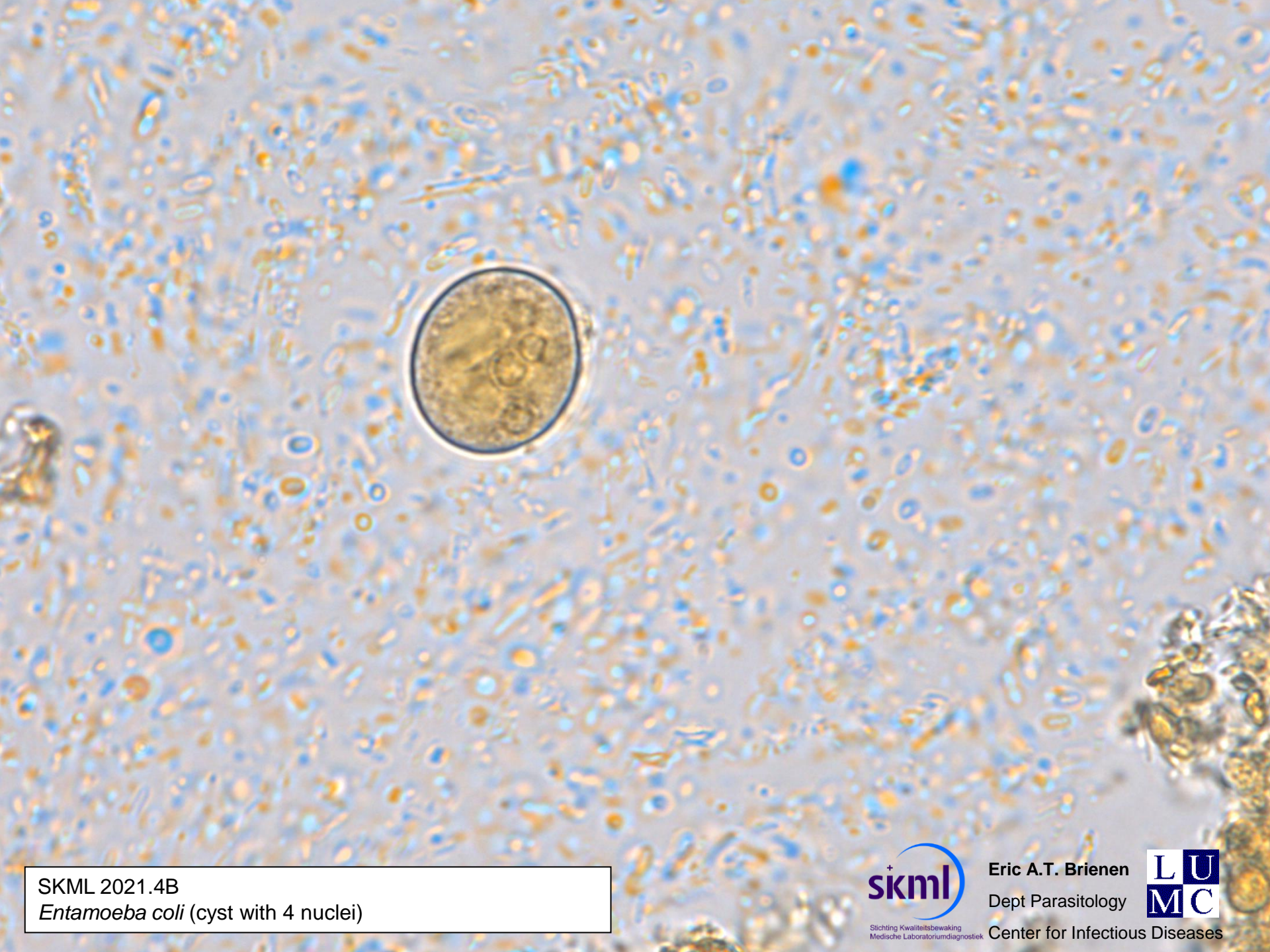


Stichting Kwaliteitsbewaking
Medische Laboratoriumdiagnostiek

Eric A.T. Brienen
Dept Parasitology



Center for Infectious Diseases



SKML 2021.4B
Entamoeba coli (cyst with 4 nuclei)

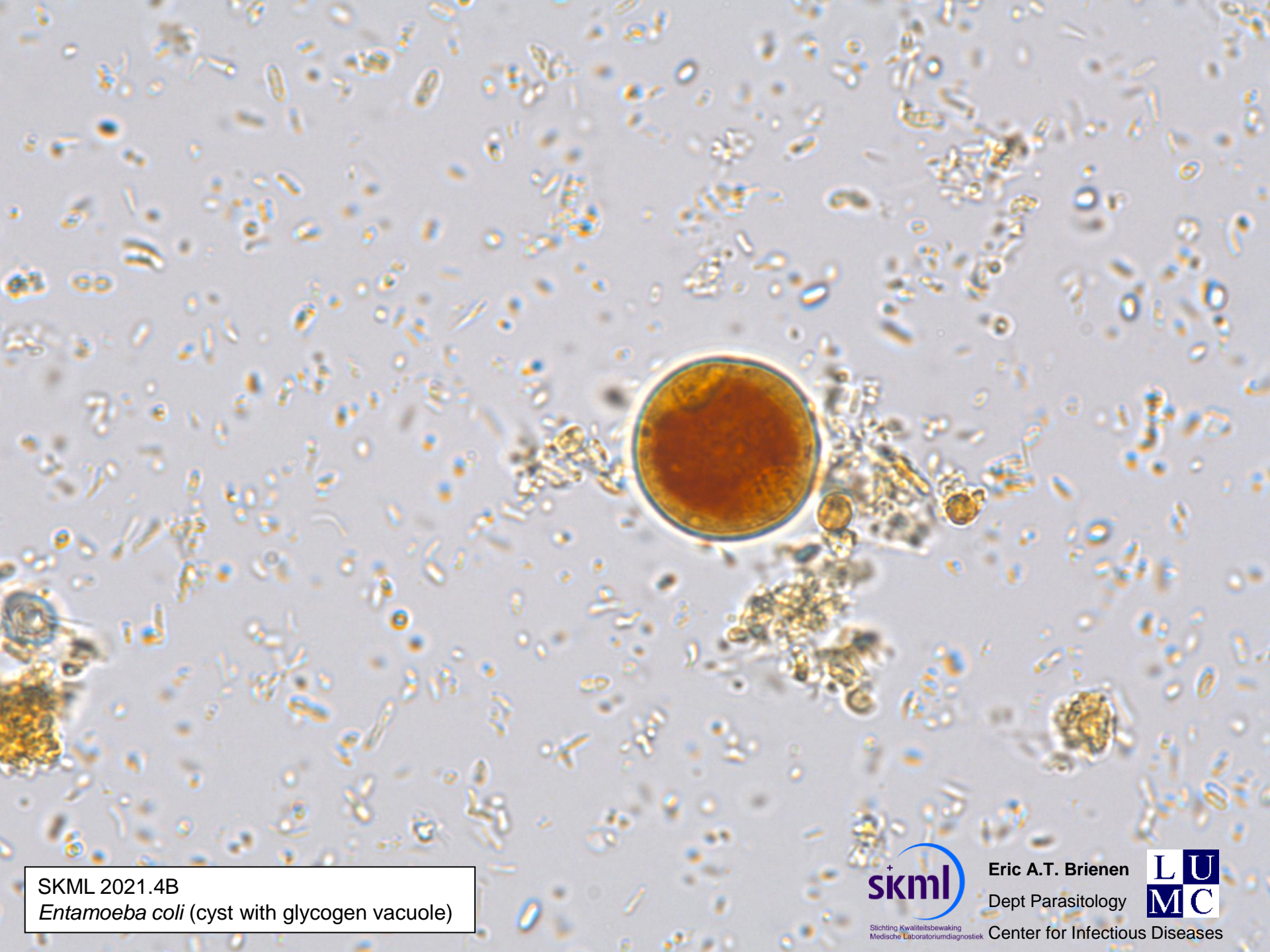


Stichting Kwaliteitsbewaking
Medische Laboratoriumdiagnostiek

Eric A.T. Brien
Dept Parasitology



Center for Infectious Diseases



SKML 2021.4B
Entamoeba coli (cyst with glycogen vacuole)



Stichting Kwaliteitsbewaking
Medische Laboratoriumdiagnostiek

Eric A.T. Brienen
Dept Parasitology



Center for Infectious Diseases

SKML morphology parasitology – explanations

2021.1A *Plasmodium vivax*

2021.1B *Plasmodium falciparum* ≈ 0.2 %

2021.2A *Plasmodium falciparum* ≈ 0.1 %

2021.2B *Plasmodium falciparum* ≈ 37 %

2021.3A *Plasmodium ovale*

2021.3B *Plasmodium falciparum* ≈ 1%

2021.4A Negative

2021.4B *Plasmodium falciparum* ≈ 0,1% + sporadic *Plasmodium ovale wallikeri*

2021.1A *Entamoeba histolytica/dispar* (trophozoites and cysts) + *Giardia lamblia*
(trophozoites and cysts) + sporadic some other protozoa

2021.1B *Strongyloides stercoralis* (rhabditiform / L1 larvae)

2021.2A Hookworm (eggs)

2021.2B *Entamoeba histolytica/dispar* (trophozoites and cysts) + *Blastocystis spp.*

2021.3A *Ascaris sp.* (eggs) + *Trichuris trichiura* (eggs)

2021.3B *Balantidium coli* (trophozoites and cysts)

2021.4A *Giardia lamblia* (trophozoites and cysts) + *Ascaris sp.* (eggs)

2021.4B *Hymenolepis nana* (eggs) + sporadic some protozoa