

SKML overview of EQAS

Morphology External Quality Assessment Scheme

- Part 1: blood parasites
- Part 2: faecal and tissue parasites
- Last slide: names and details of parasites

(C) SKML section parasitology

For training and education purpose only

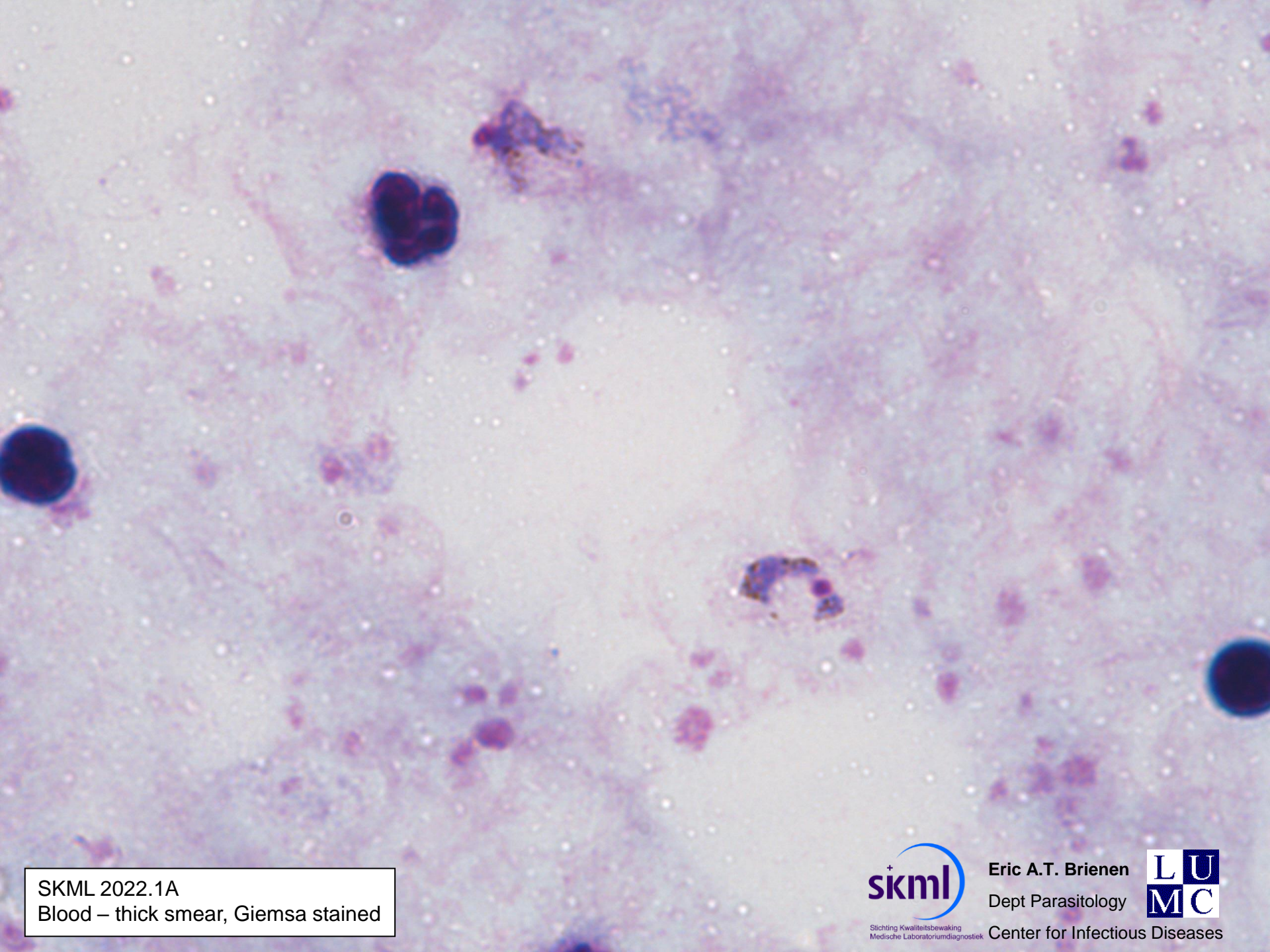
Please acknowledge:



Eric A.T. Brienen
Dept Parasitology
Center for Infectious Diseases



NB: a separate file is provided with the name of the parasite depicted on each slide



SKML 2022.1A
Blood – thick smear, Giemsa stained

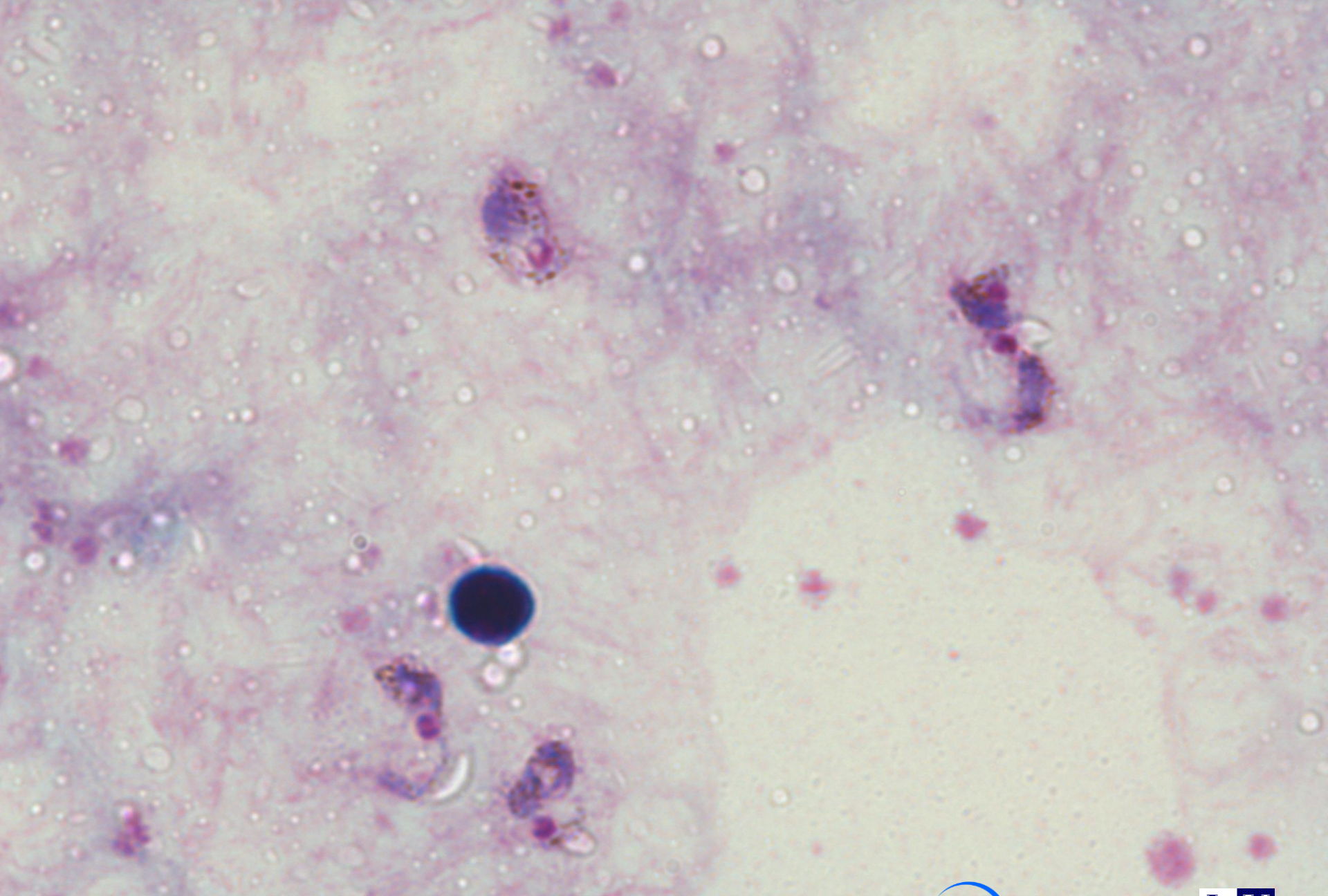


Stichting Kwaliteitsbewaking
Medische Laboratoriumdiagnostiek

Eric A.T. Brienens
Dept Parasitology



Center for Infectious Diseases



SKML 2022.1A
Blood – thick smear, Giemsa stained

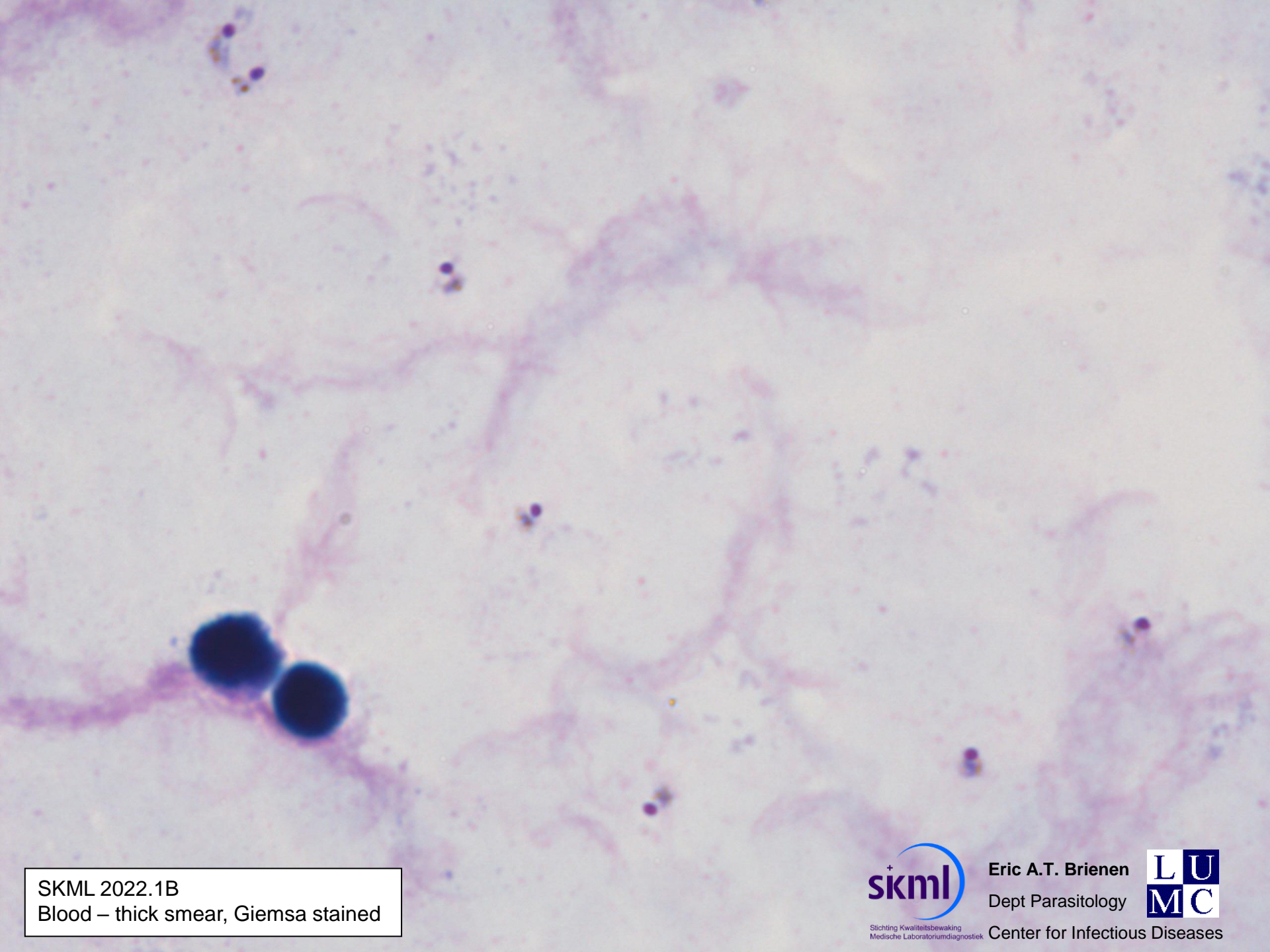


Stichting Kwaliteitsbewaking
Medische Laboratoriumdiagnostiek

Eric A.T. Brienen
Dept Parasitology



Center for Infectious Diseases



SKML 2022.1B
Blood – thick smear, Giemsa stained

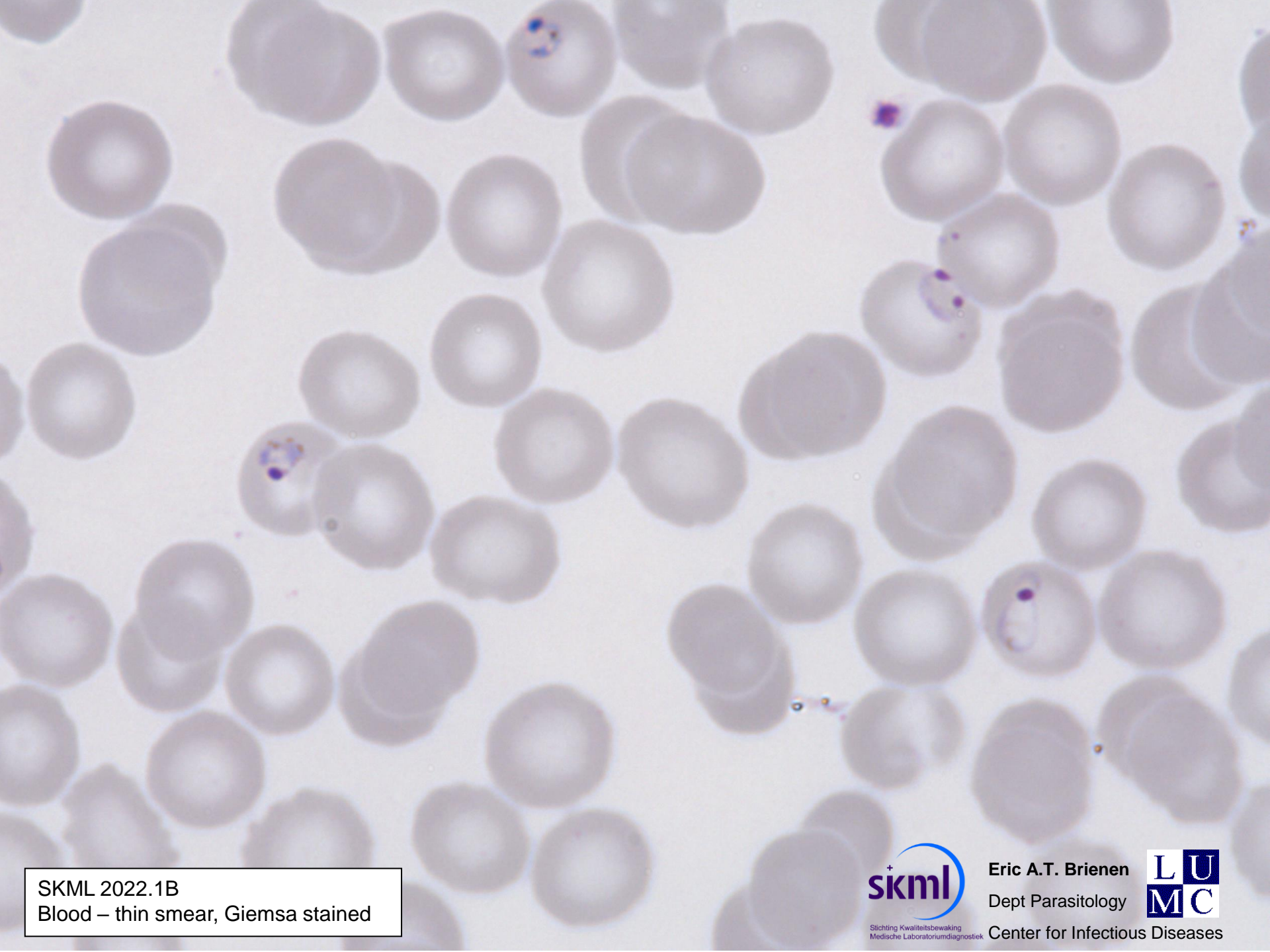


Stichting Kwaliteitsbewaking
Medische Laboratoriumdiagnostiek

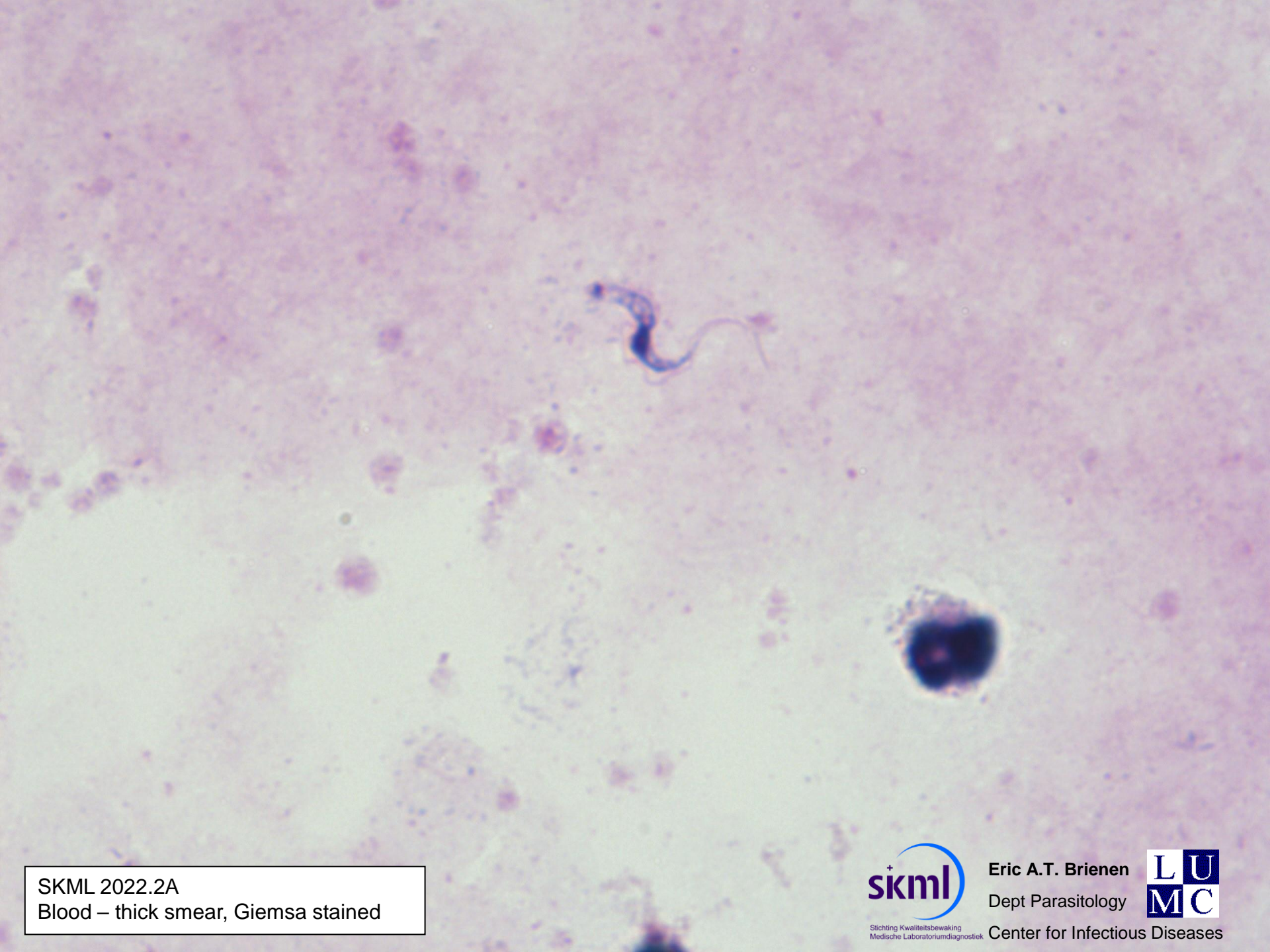
Eric A.T. Brienens
Dept Parasitology



Center for Infectious Diseases



SKML 2022.1B
Blood – thin smear, Giemsa stained



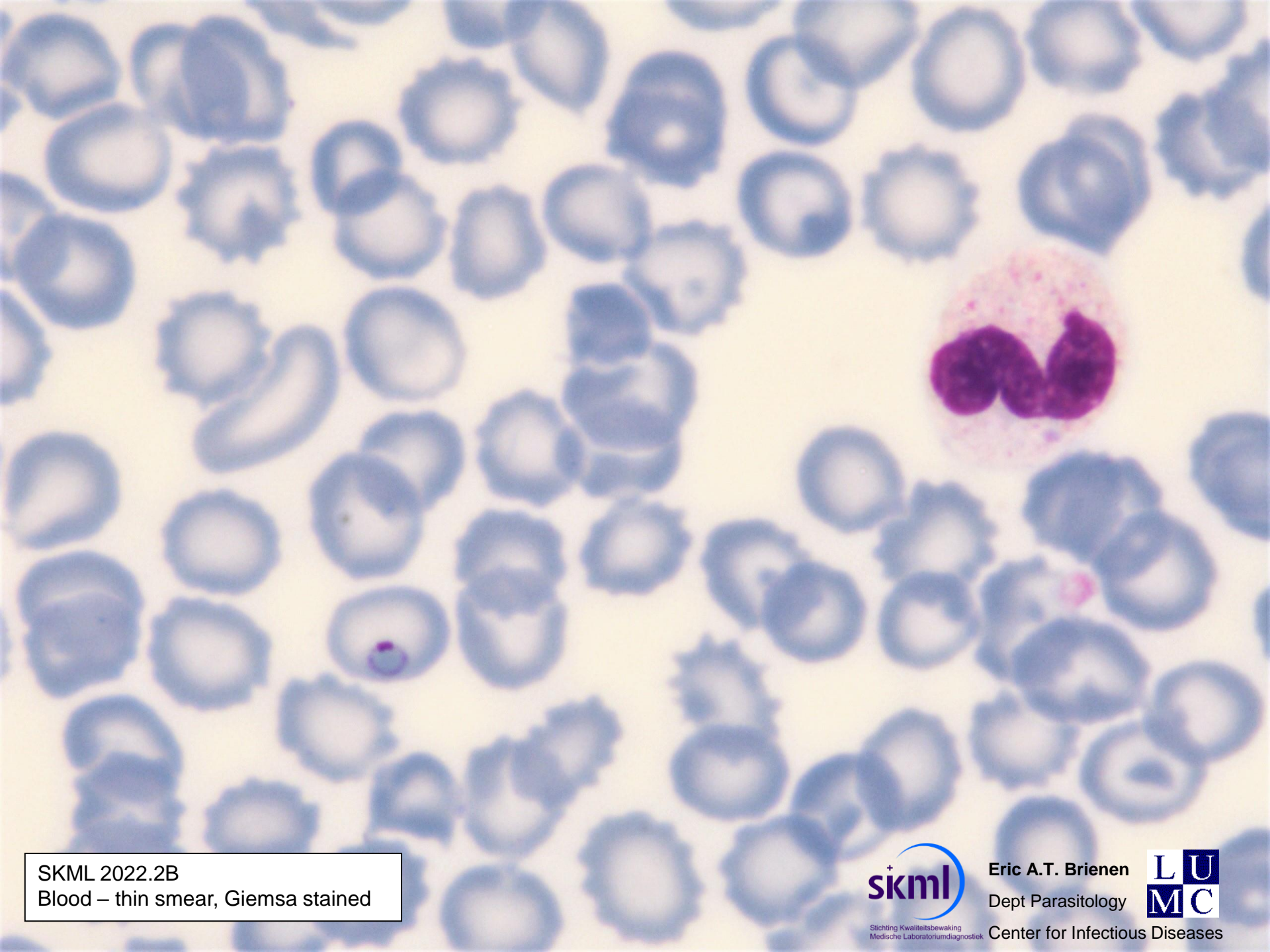
SKML 2022.2A
Blood – thick smear, Giemsa stained



Eric A.T. Brien
Dept Parasitology



Center for Infectious Diseases



SKML 2022.2B
Blood – thin smear, Giemsa stained

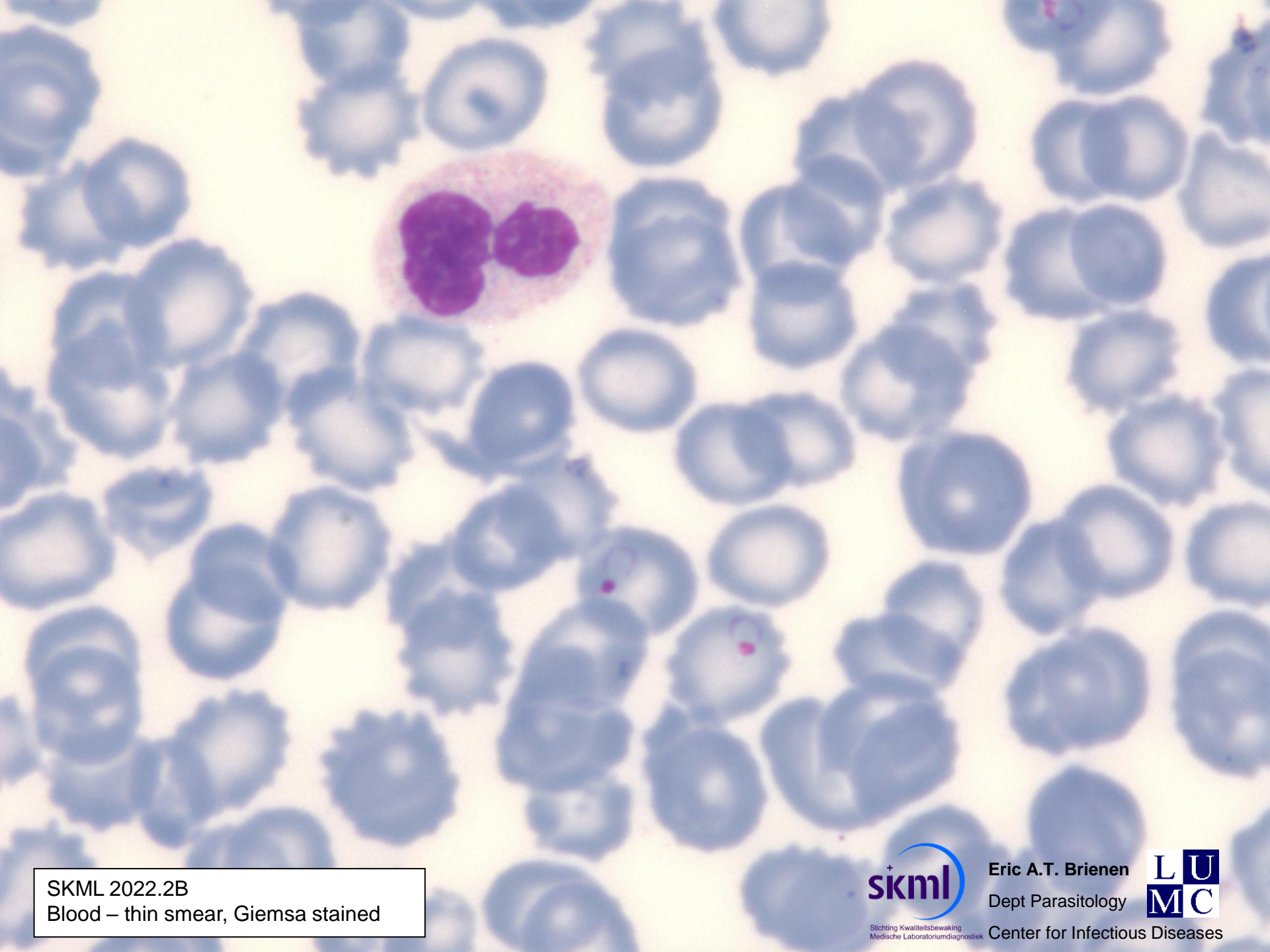


Stichting Kwaliteitsbewaking
Medische Laboratoriumdiagnostiek

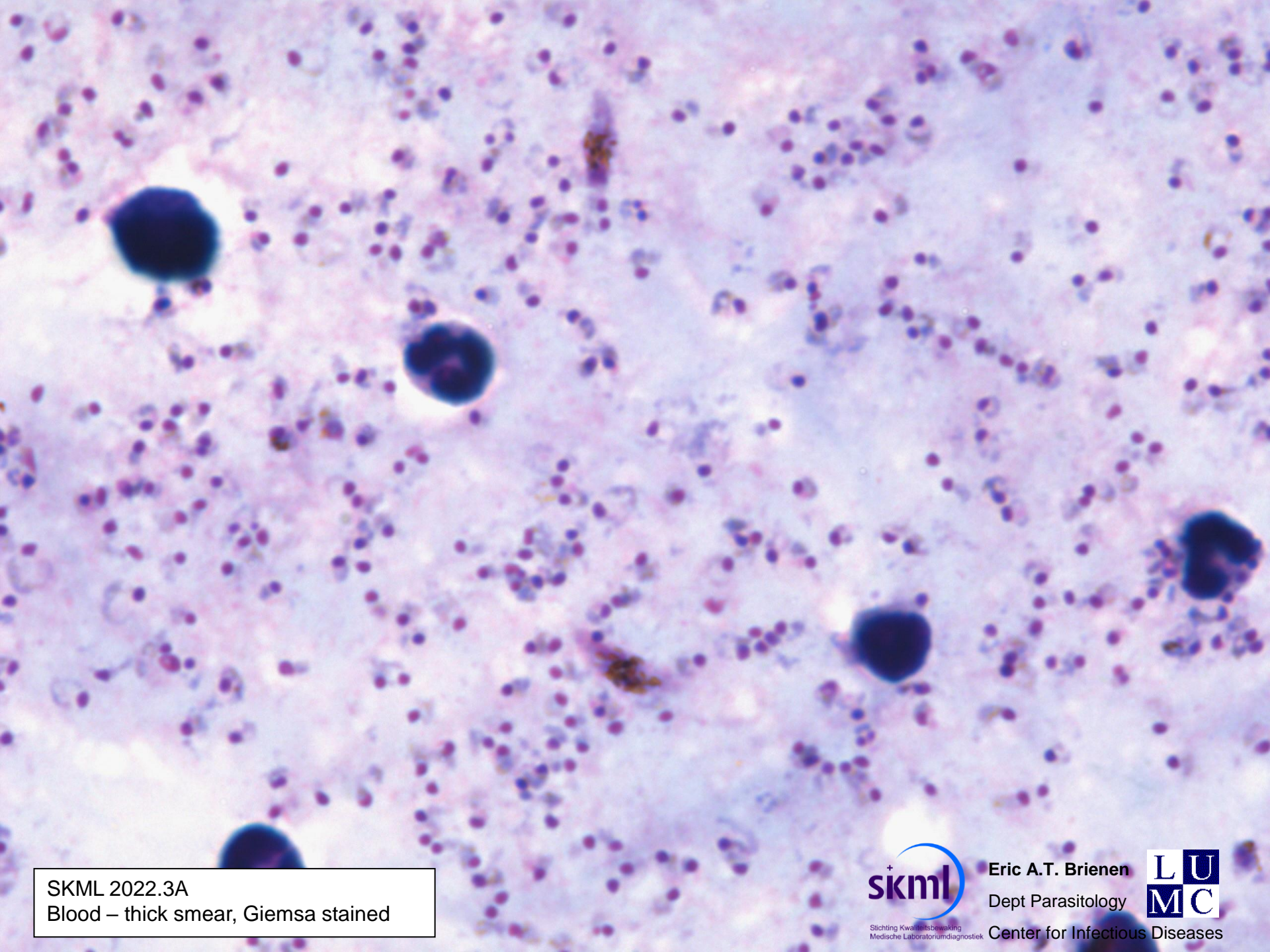
Eric A.T. Brien
Dept Parasitology



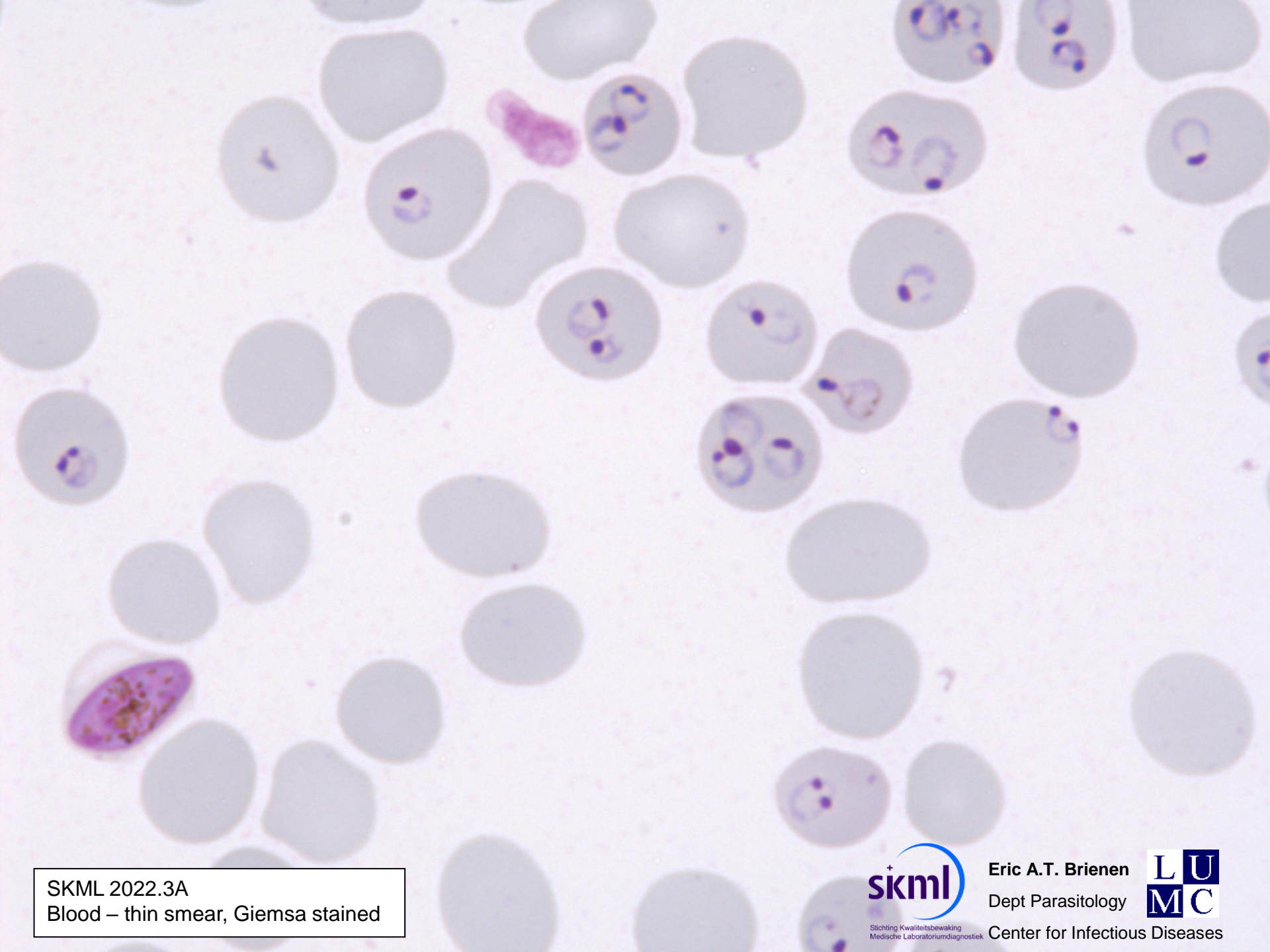
Center for Infectious Diseases



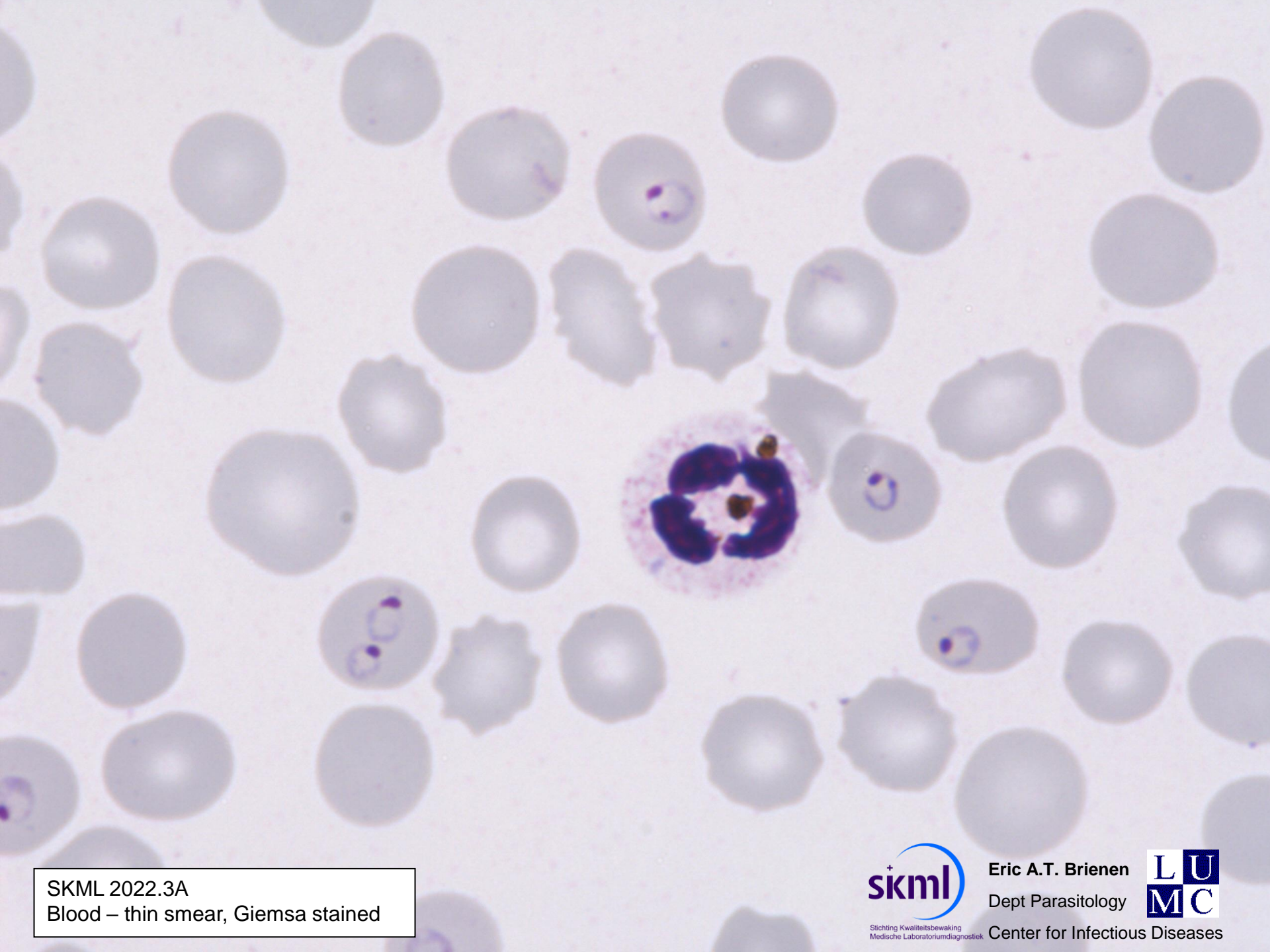
SKML 2022.2B
Blood – thin smear, Giemsa stained



SKML 2022.3A
Blood – thick smear, Giemsa stained



SKML 2022.3A
Blood – thin smear, Giemsa stained

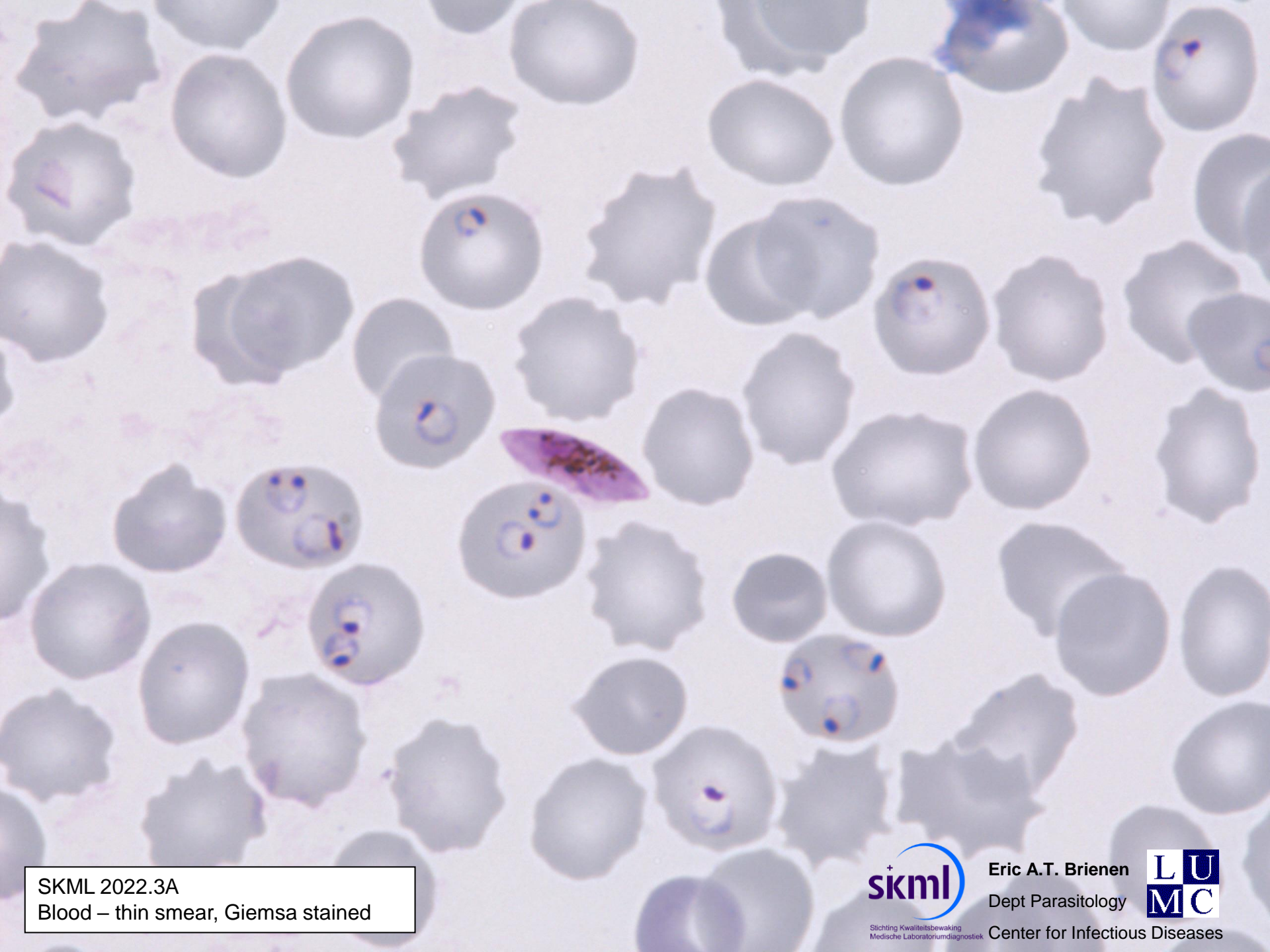

SKML 2022.3A
Blood – thin smear, Giemsa stained

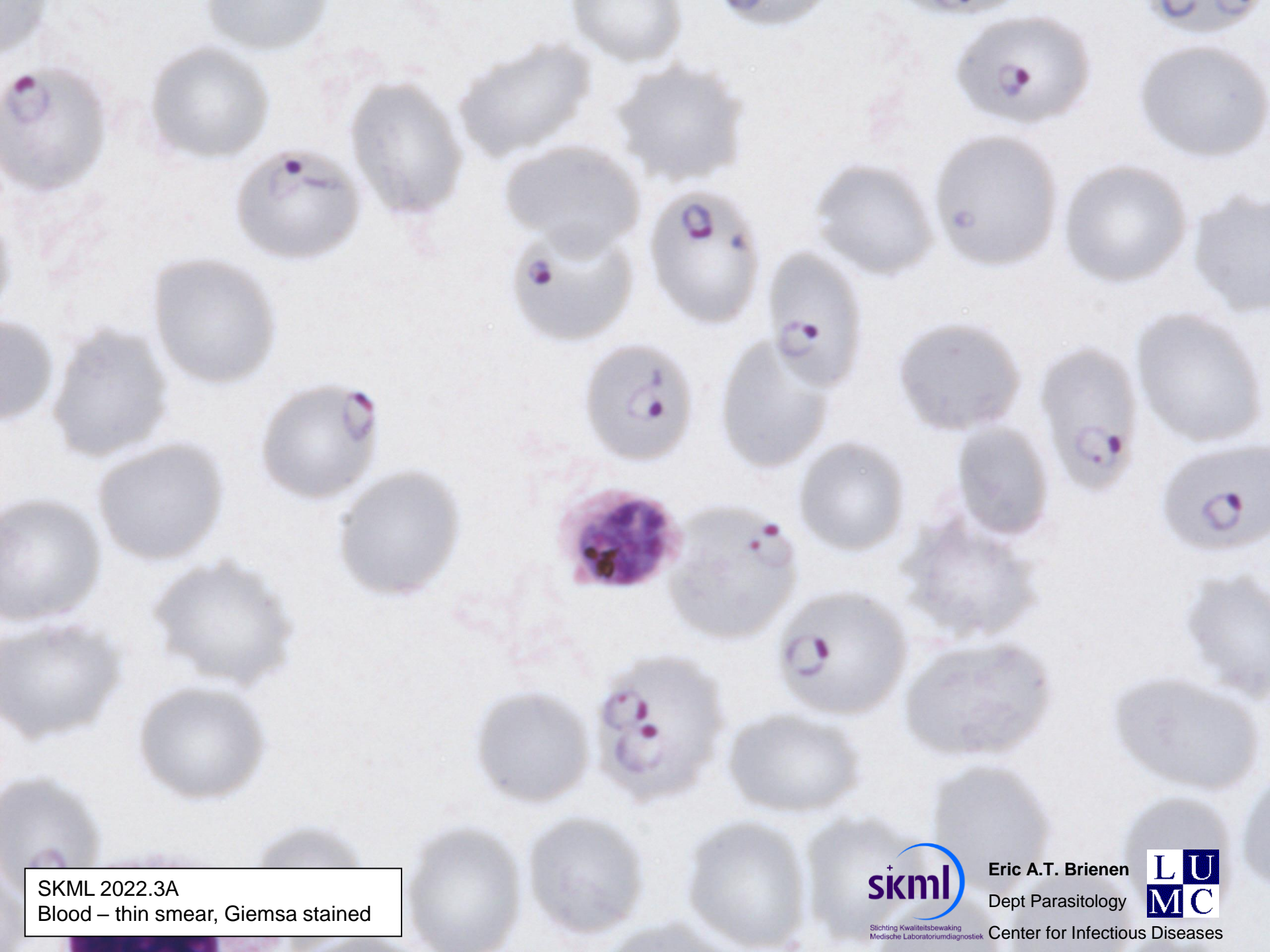


Eric A.T. Brienens
Dept Parasitology
Center for Infectious Diseases

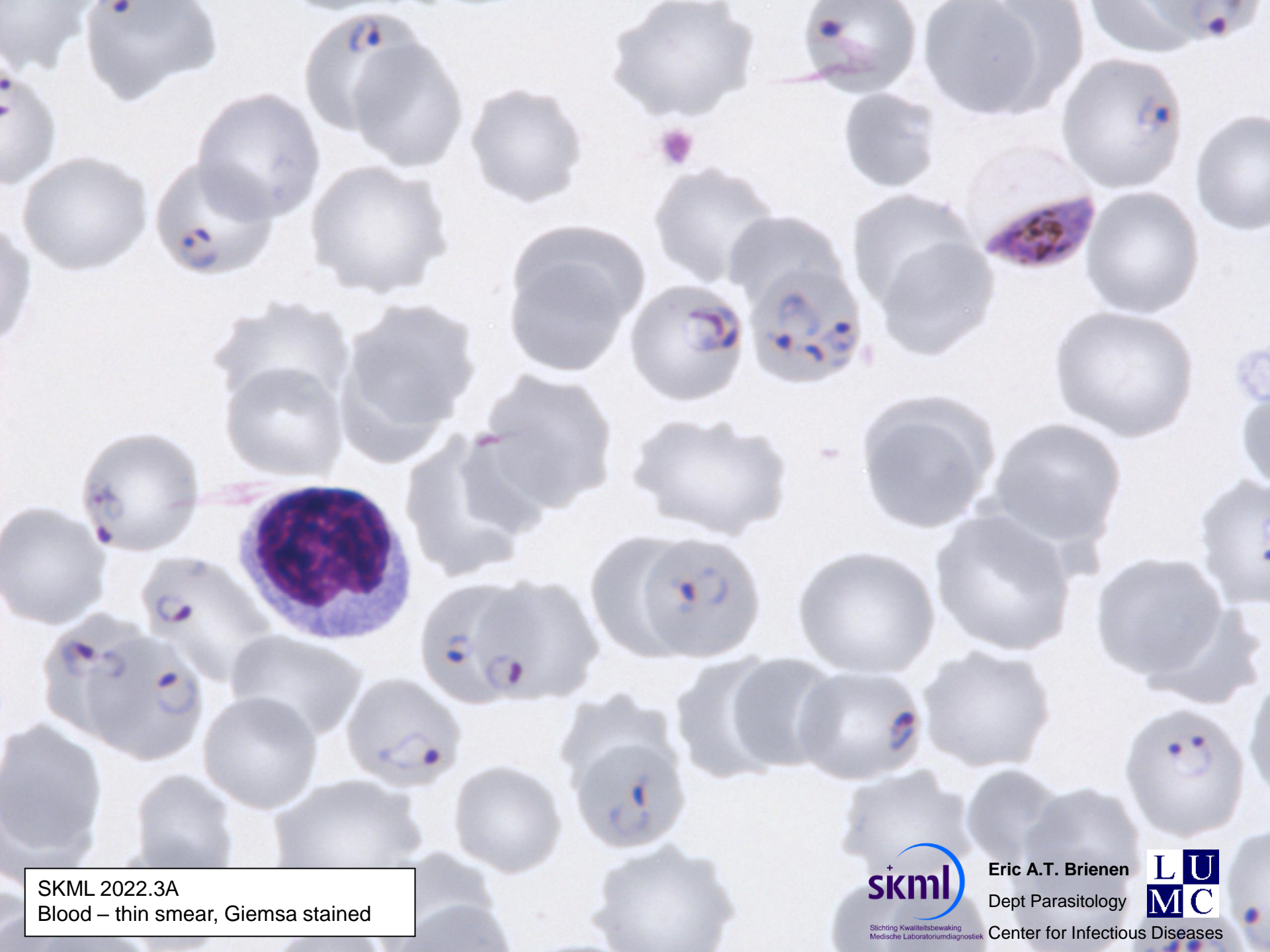




SKML 2022.3A
Blood – thin smear, Giemsa stained



SKML 2022.3A
Blood – thin smear, Giemsa stained



SKML 2022.3A
Blood – thin smear, Giemsa stained

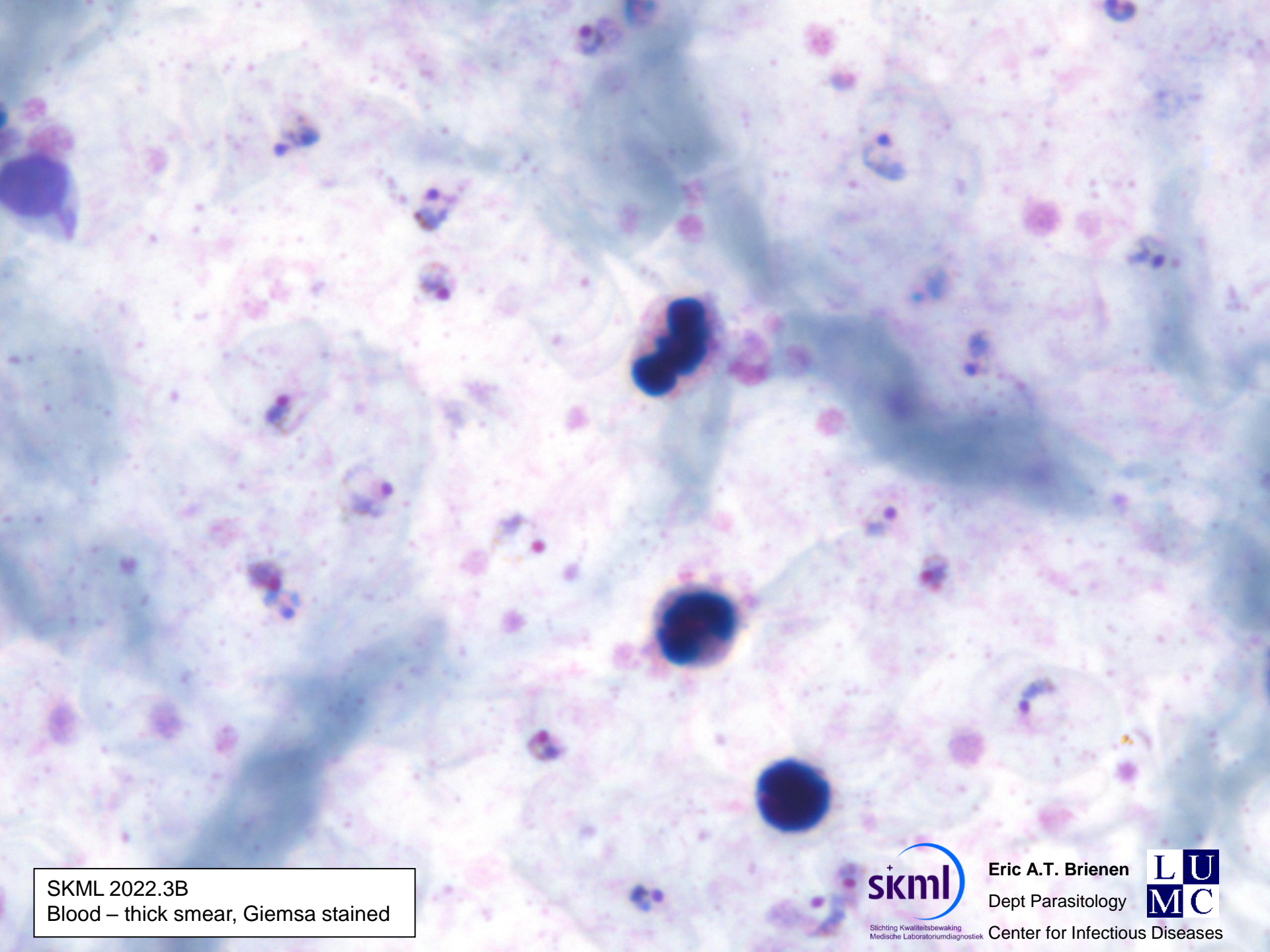


Stichting Kwaliteitsbewaking
Medische Laboratoriumdiagnostiek

Eric A.T. Brienen
Dept Parasitology



Center for Infectious Diseases



SKML 2022.3B
Blood – thick smear, Giemsa stained

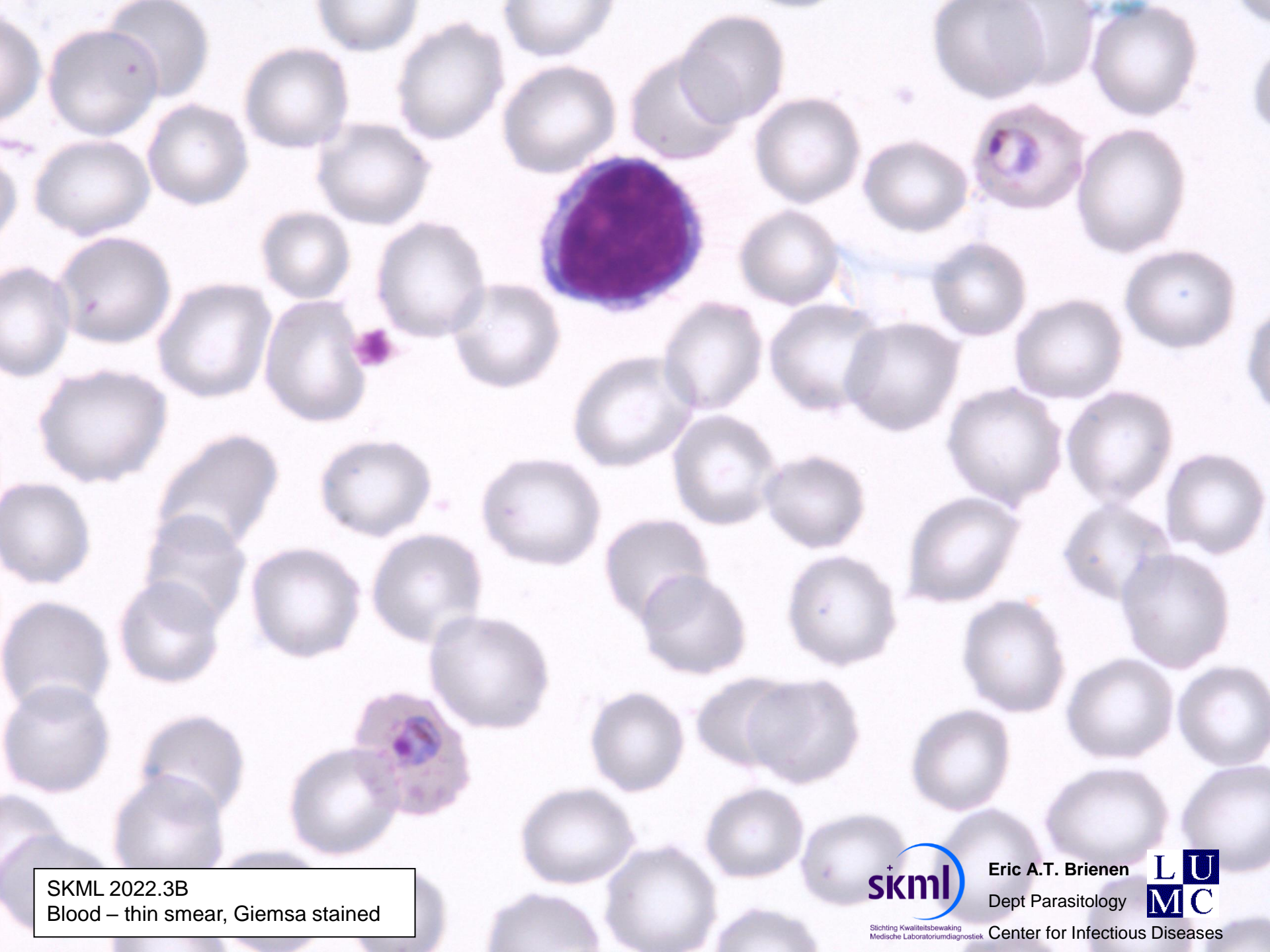


Stichting Kwaliteitsbewaking
Medische Laboratoriumdiagnostiek

Eric A.T. Brienen
Dept Parasitology



Center for Infectious Diseases



SKML 2022.3B
Blood – thin smear, Giemsa stained

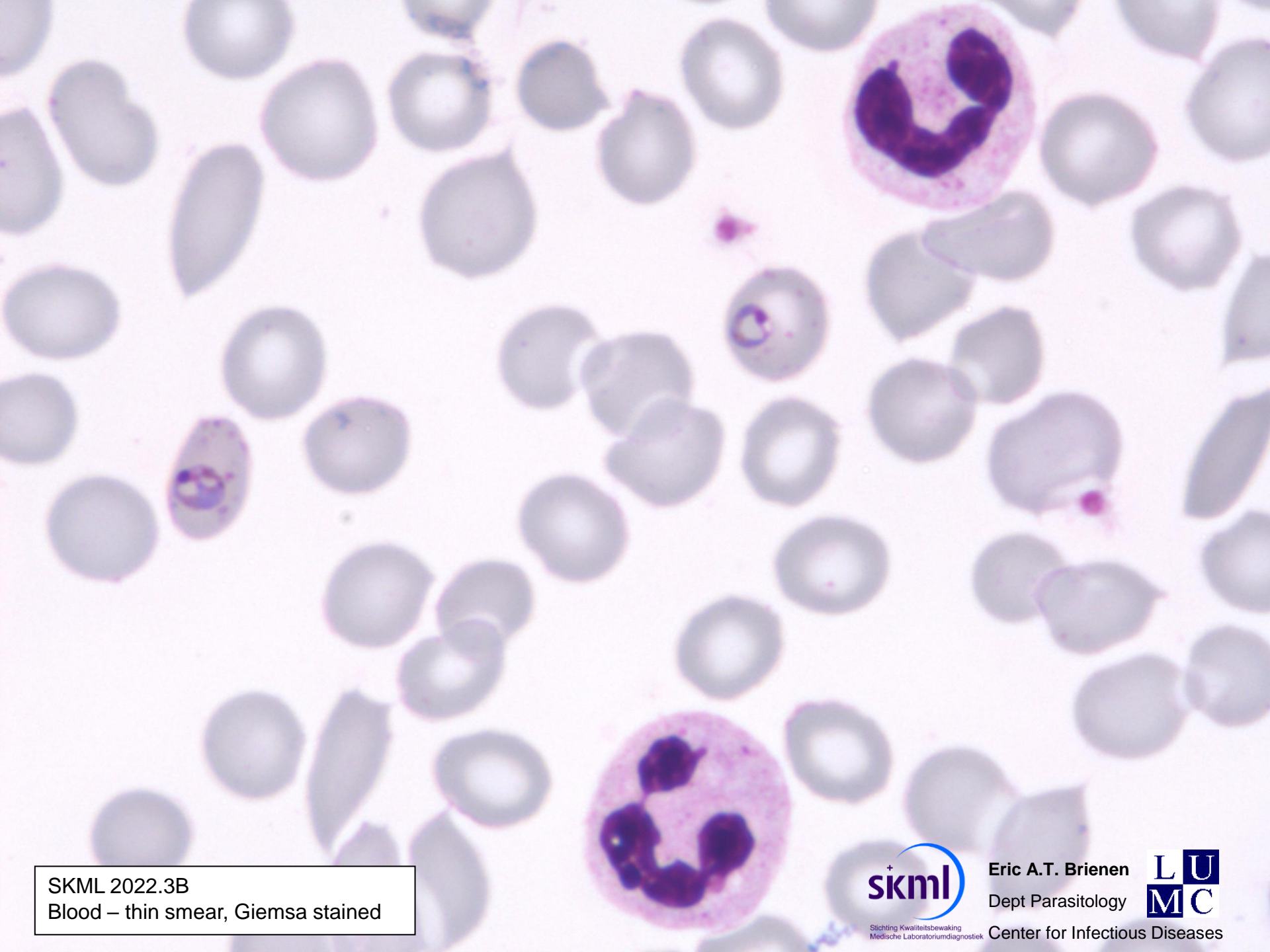


Stichting Kwaliteitsbewaking
Medische Laboratoriumdiagnostiek

Eric A.T. Brienen
Dept Parasitology



Center for Infectious Diseases



SKML 2022.3B
Blood – thin smear, Giemsa stained

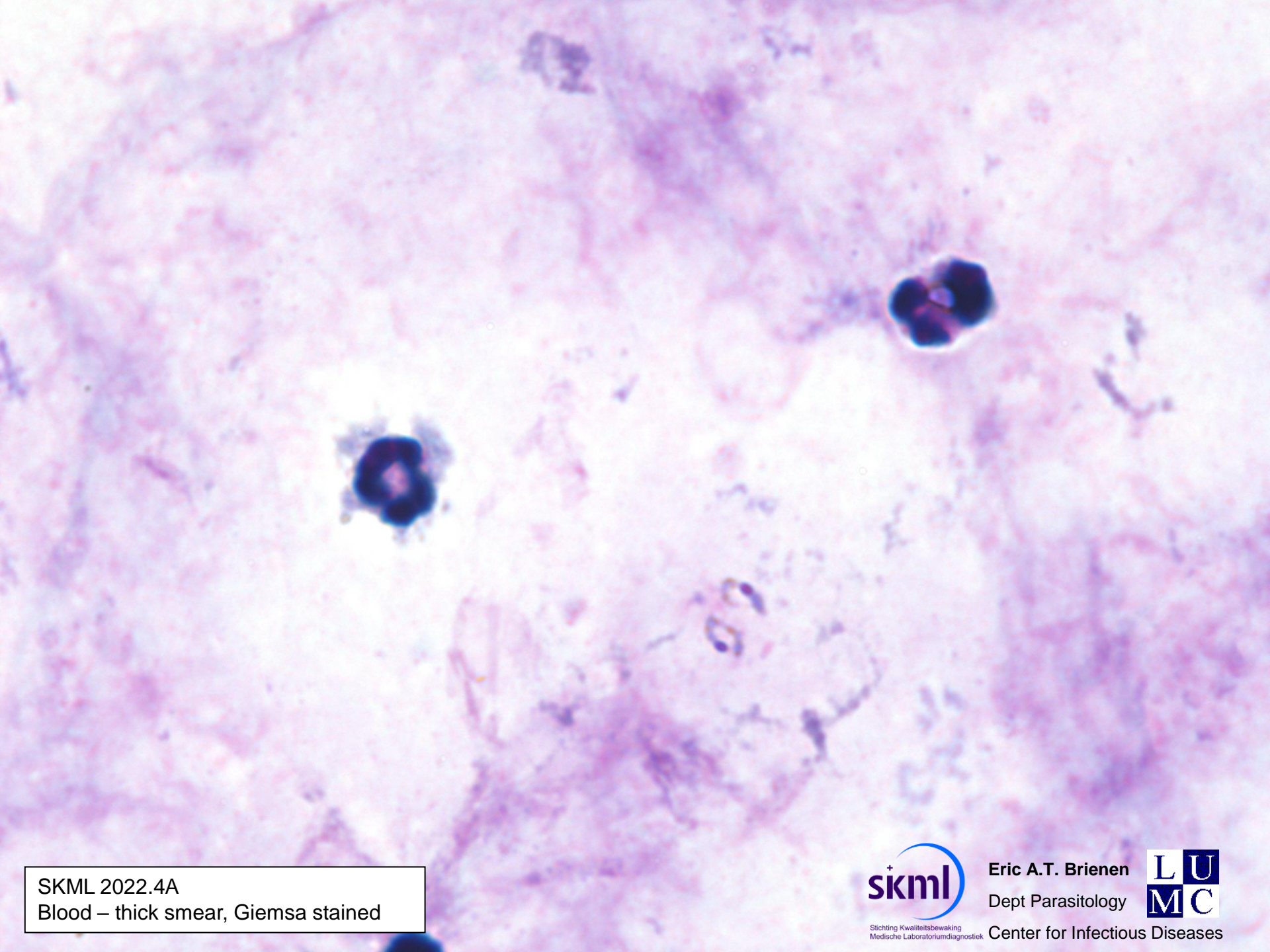


Stichting Kwaliteitsbewaking
Medische Laboratoriumdiagnostiek

Eric A.T. Brienen
Dept Parasitology



Center for Infectious Diseases



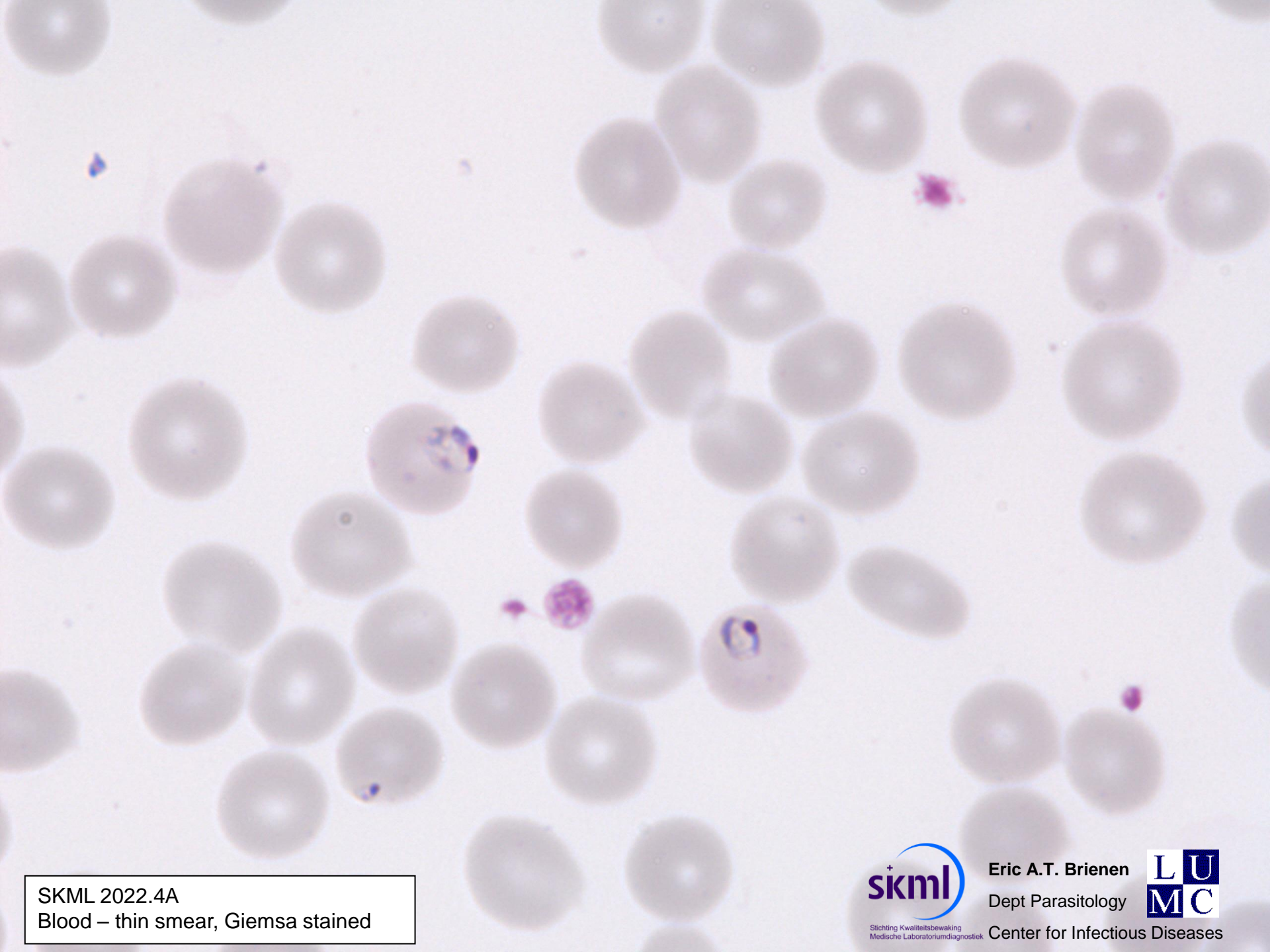SKML 2022.4A
Blood – thick smear, Giemsa stained



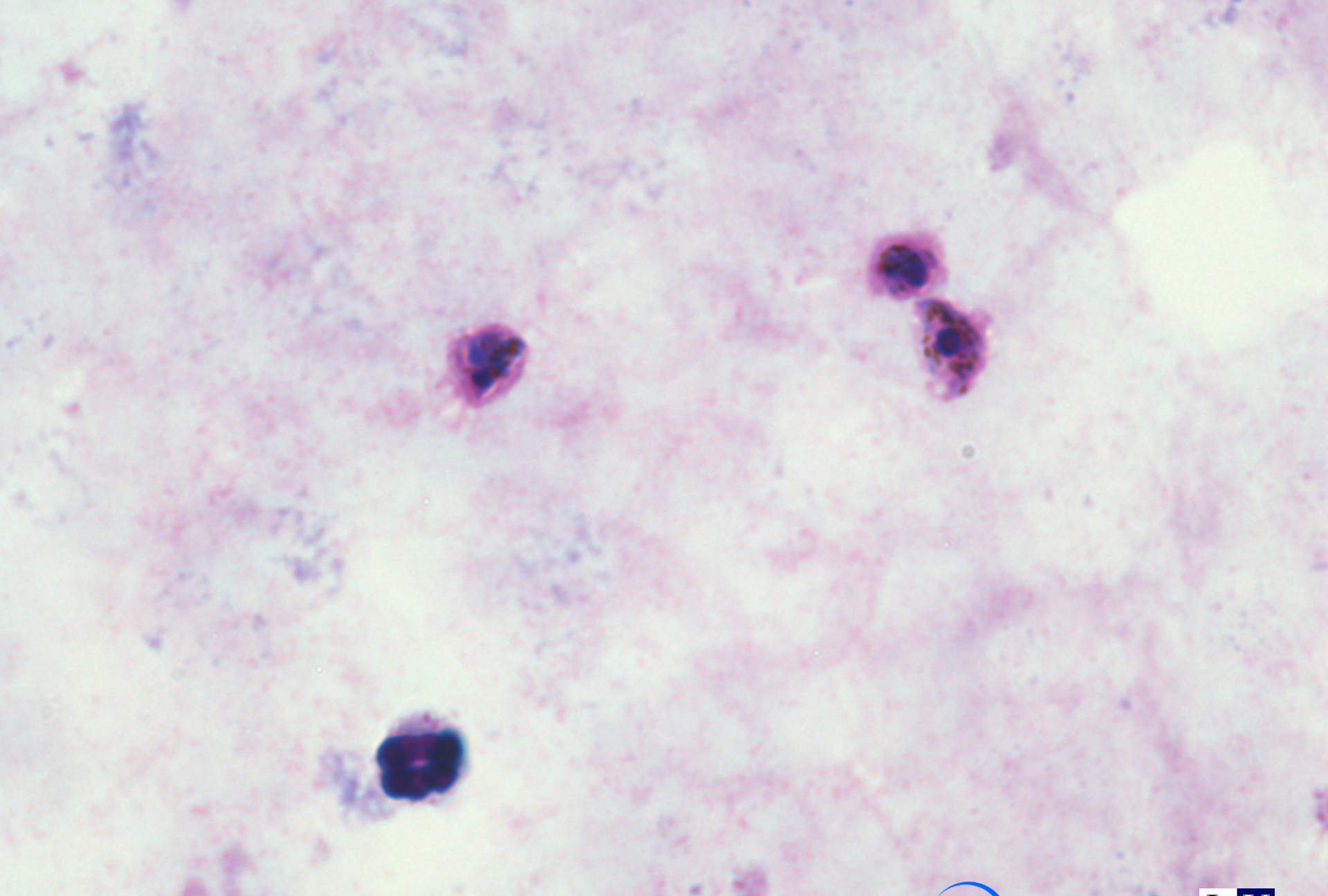
Eric A.T. Brienens
Dept Parasitology



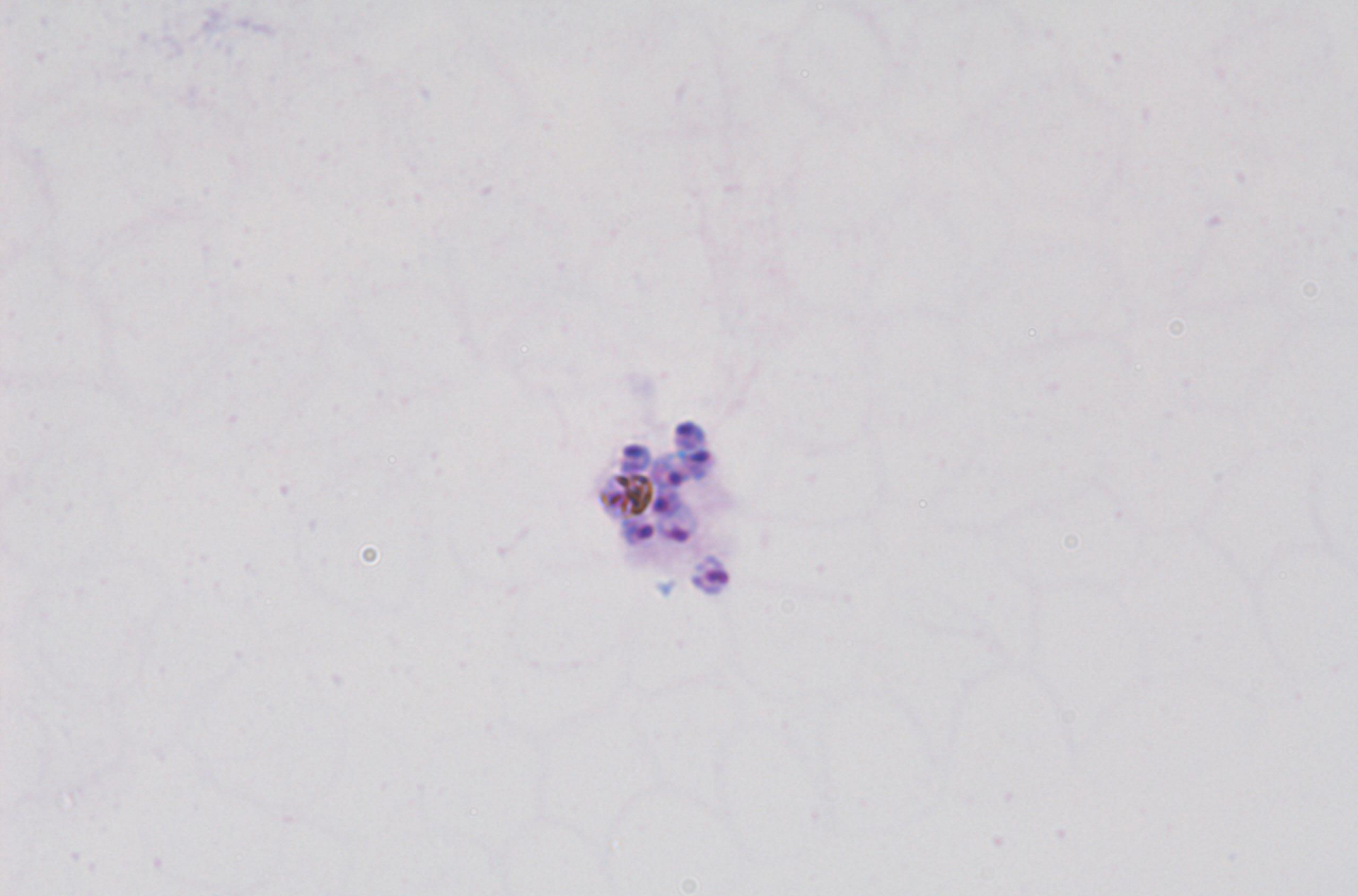
Center for Infectious Diseases



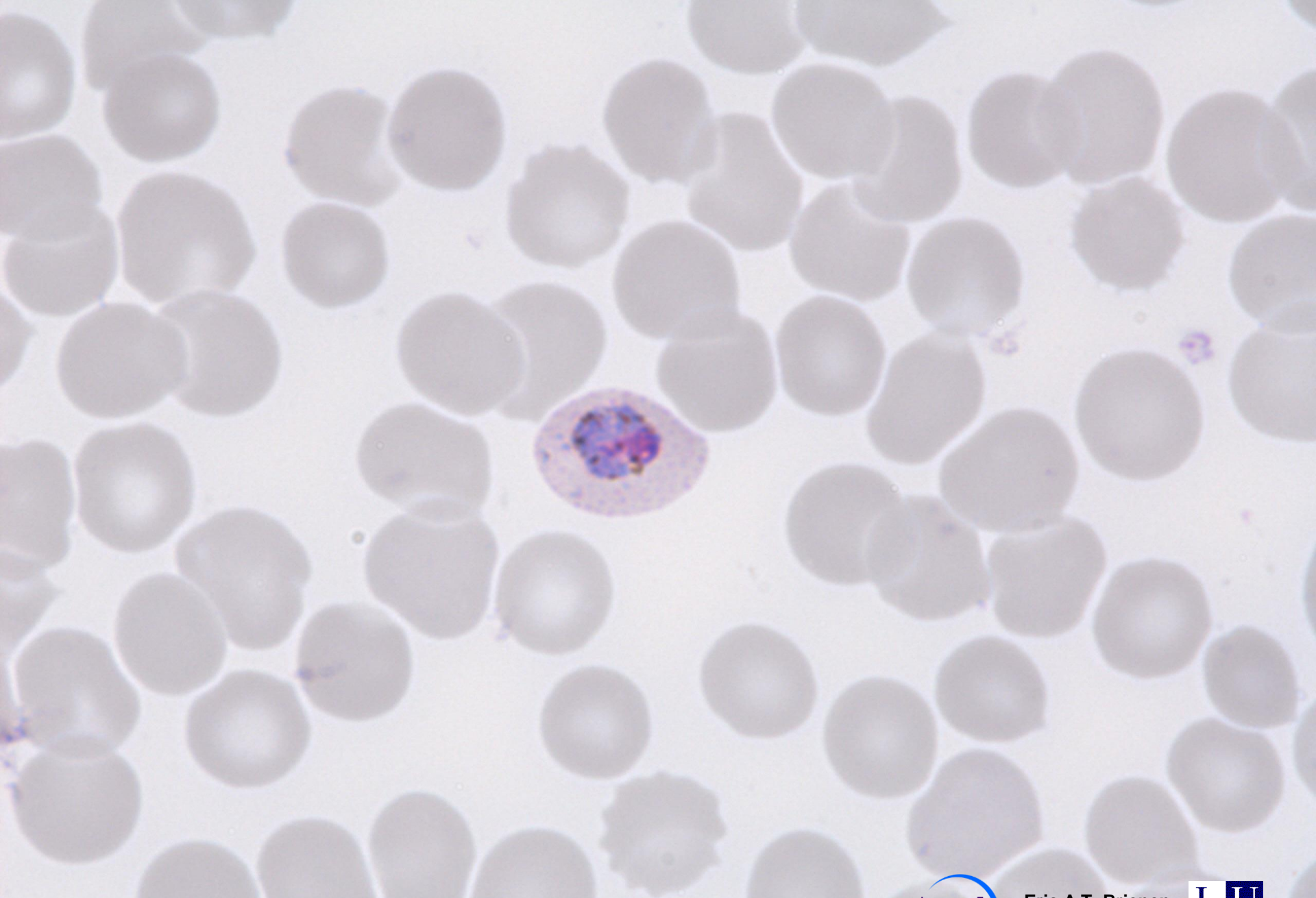
SKML 2022.4A
Blood – thin smear, Giemsa stained



SKML 2022.4B
Blood – thick smear, Giemsa stained



SKML 2022.4B
Blood – thick smear, Giemsa stained



SKML 2022.4B
Blood – thin smear, Giemsa stained

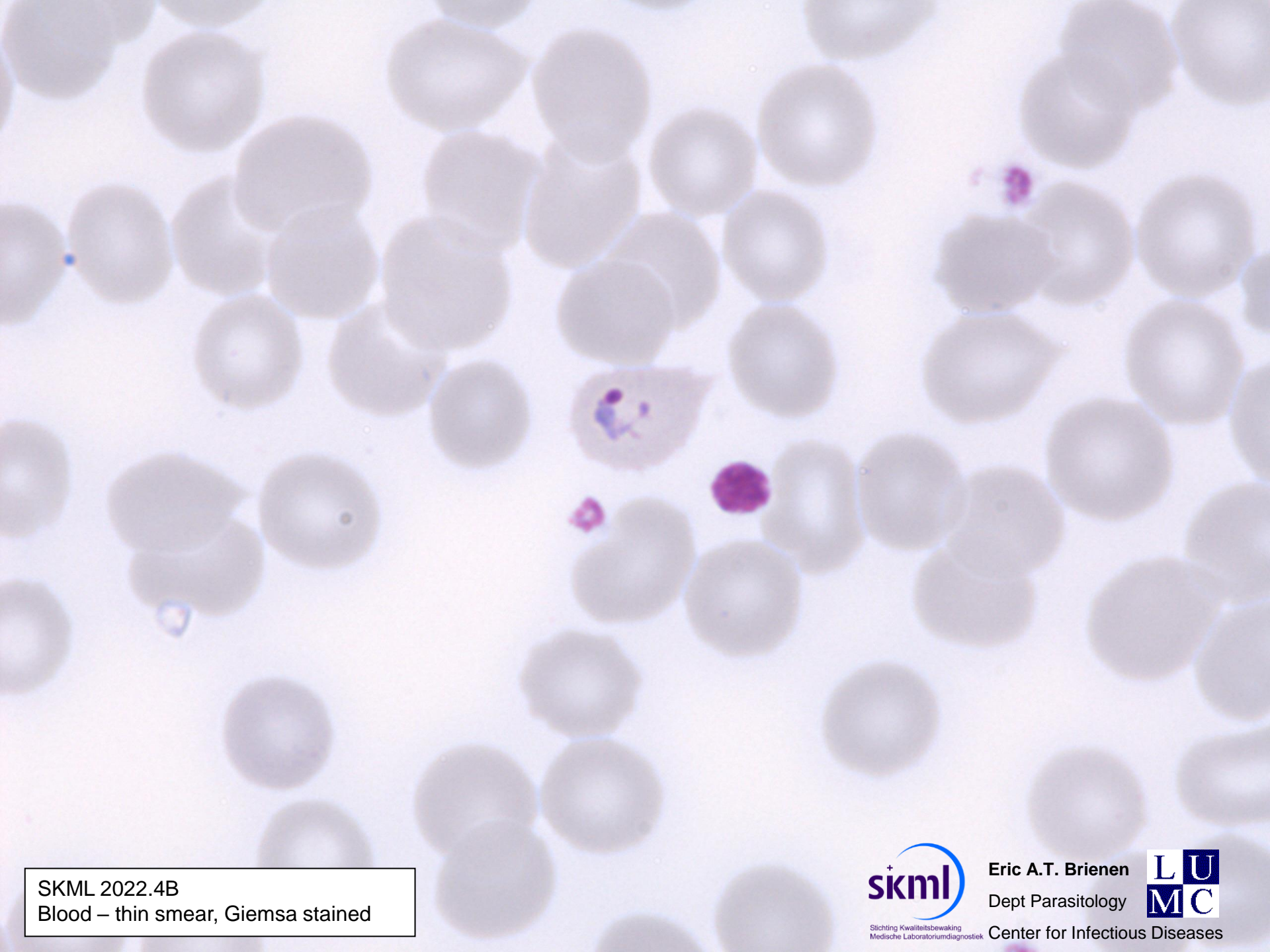


Stichting Kwaliteitsbewaking
Medische Laboratoriumdiagnostiek

Eric A.T. Brien
Dept Parasitology



Center for Infectious Diseases



SKML 2022.4B
Blood – thin smear, Giemsa stained

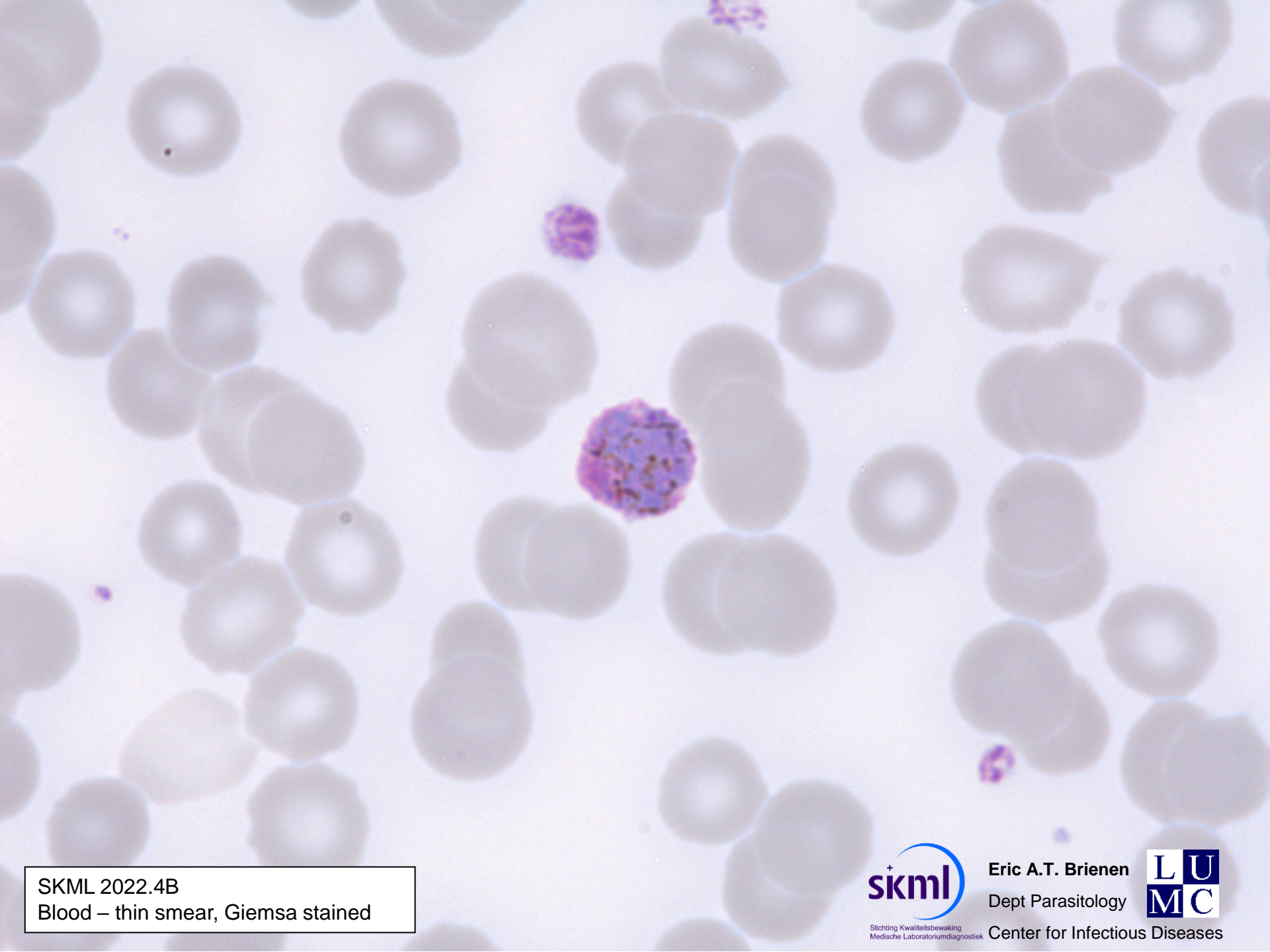


Stichting Kwaliteitsbewaking
Medische Laboratoriumdiagnostiek

Eric A.T. Brienens
Dept Parasitology



Center for Infectious Diseases



SKML 2022.4B
Blood – thin smear, Giemsa stained

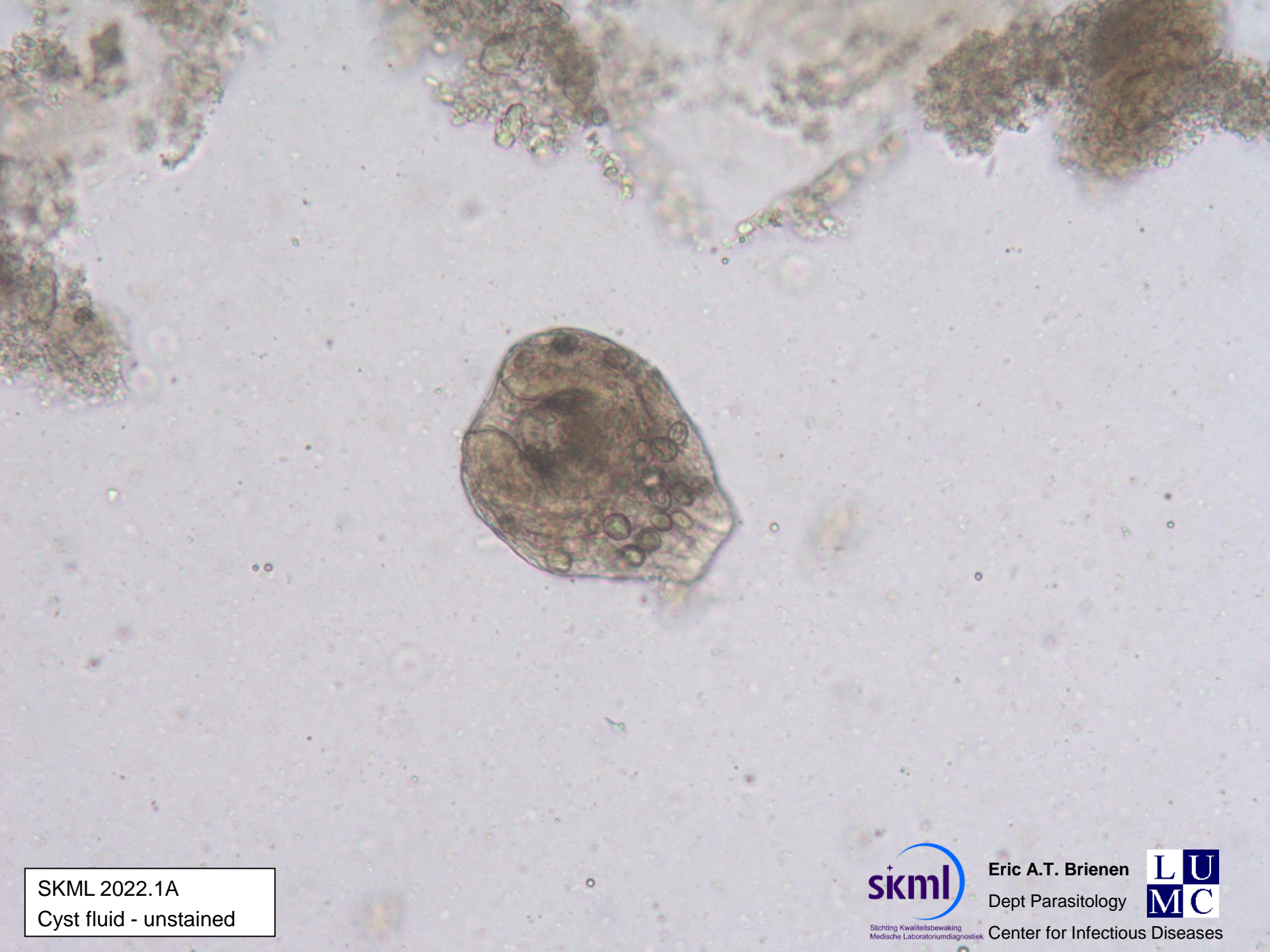

Stichting Kwaliteitsbewaking
Medische Laboratoriumdiagnostiek

Eric A.T. Brienens
Dept Parasitology



Center for Infectious Diseases



SKML 2022.1A
Cyst fluid - unstained

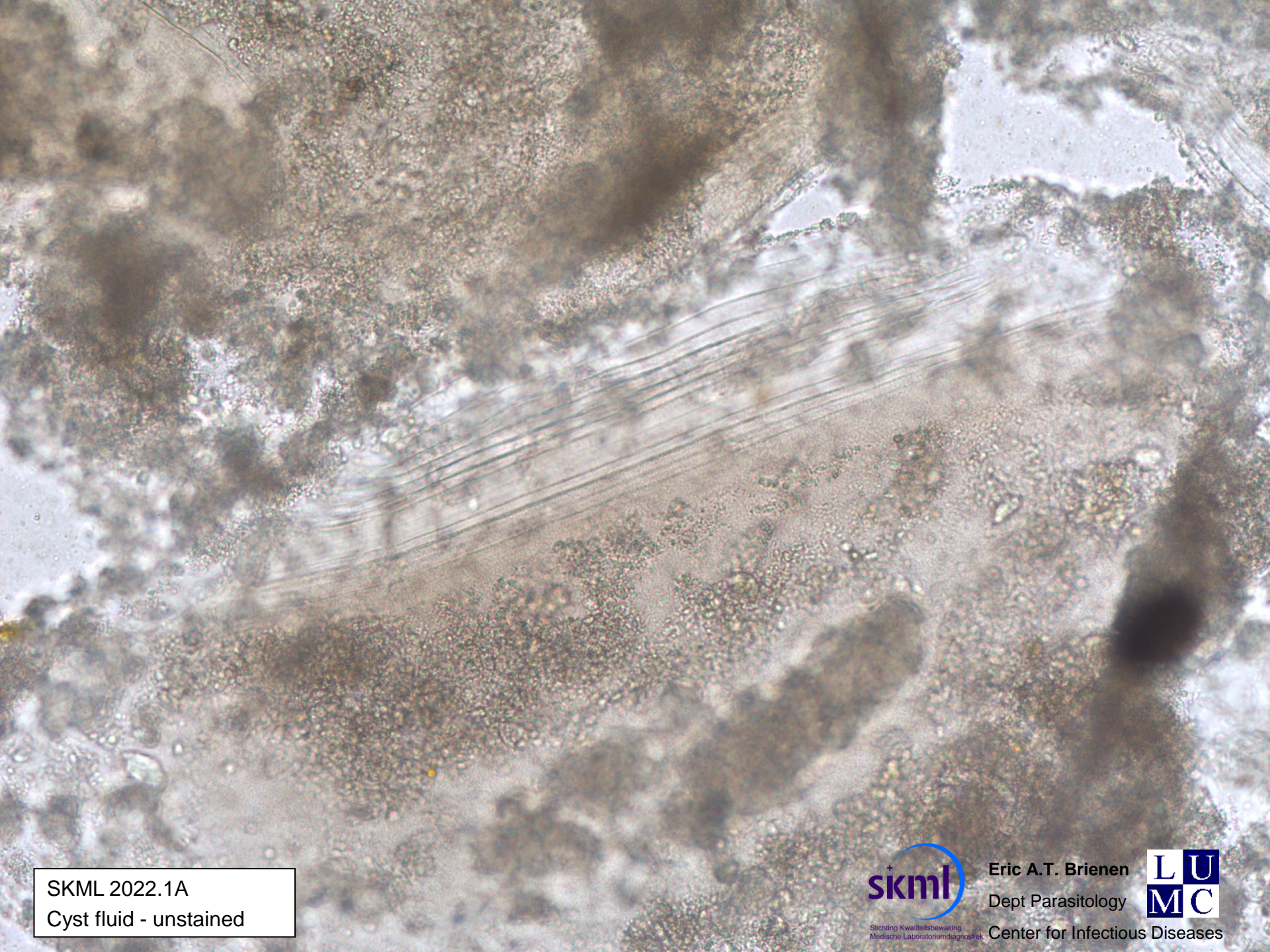


Stichting Kwaliteitsbewaking
Medische Laboratoriumdiagnostiek

Eric A.T. Brienen
Dept Parasitology



Center for Infectious Diseases



SKML 2022.1A
Cyst fluid - unstained

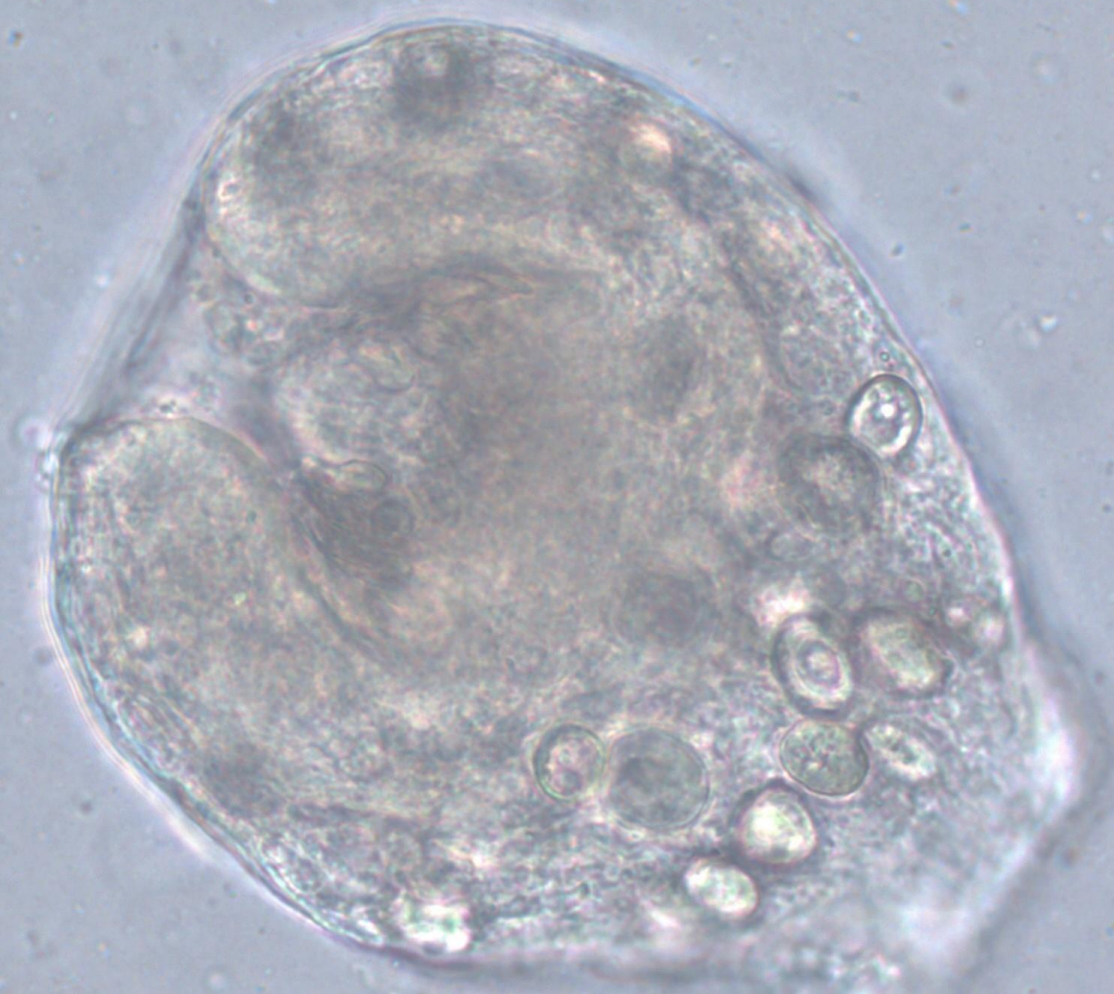


Stichting Kwaliteitsbewaking
Medische Laboratoriumdiagnostiek

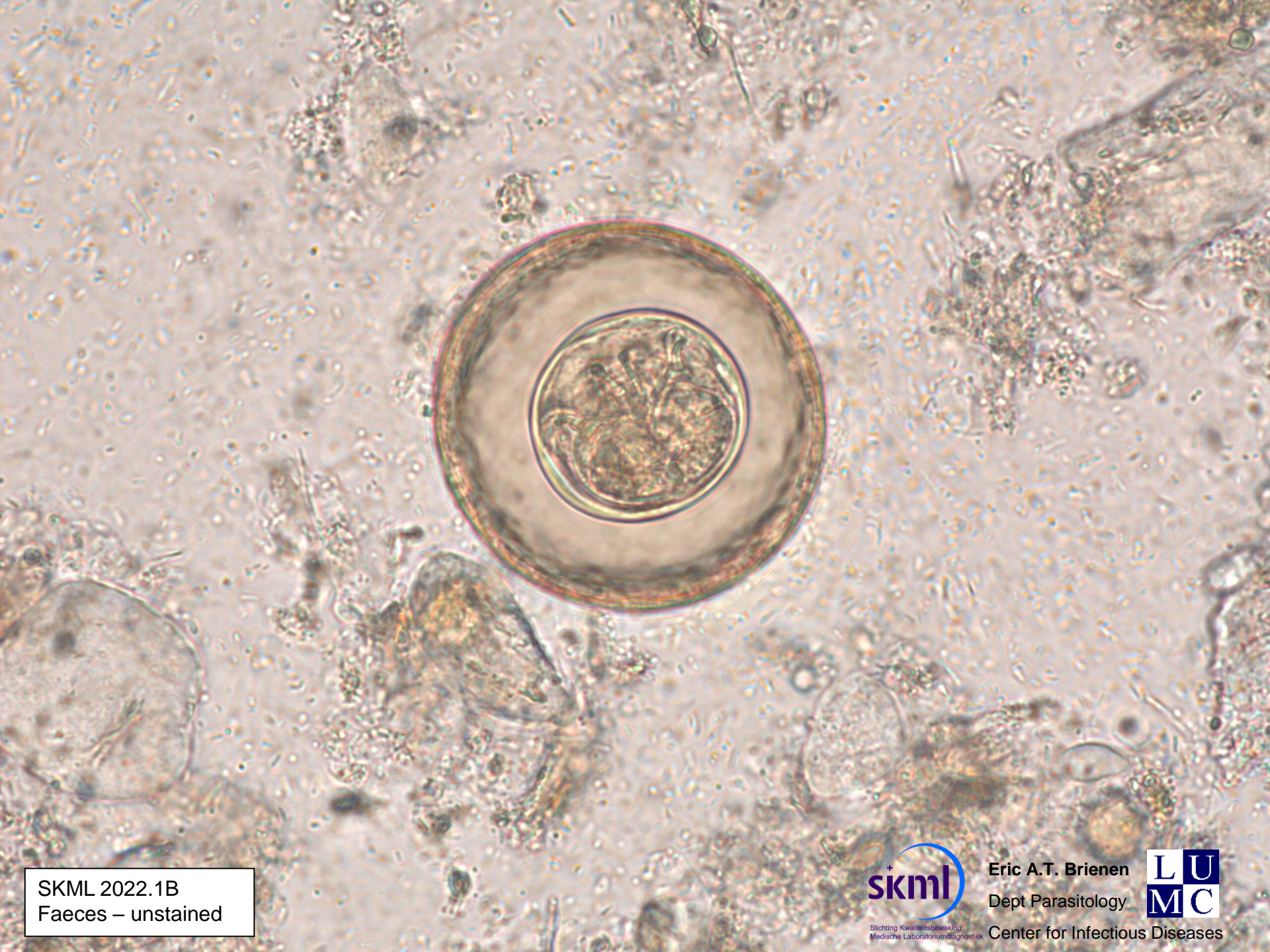Eric A.T. Brienens
Dept Parasitology



Center for Infectious Diseases



SKML 2022.1A
Cyst fluid - unstained



SKML 2022.1B
Faeces – unstained

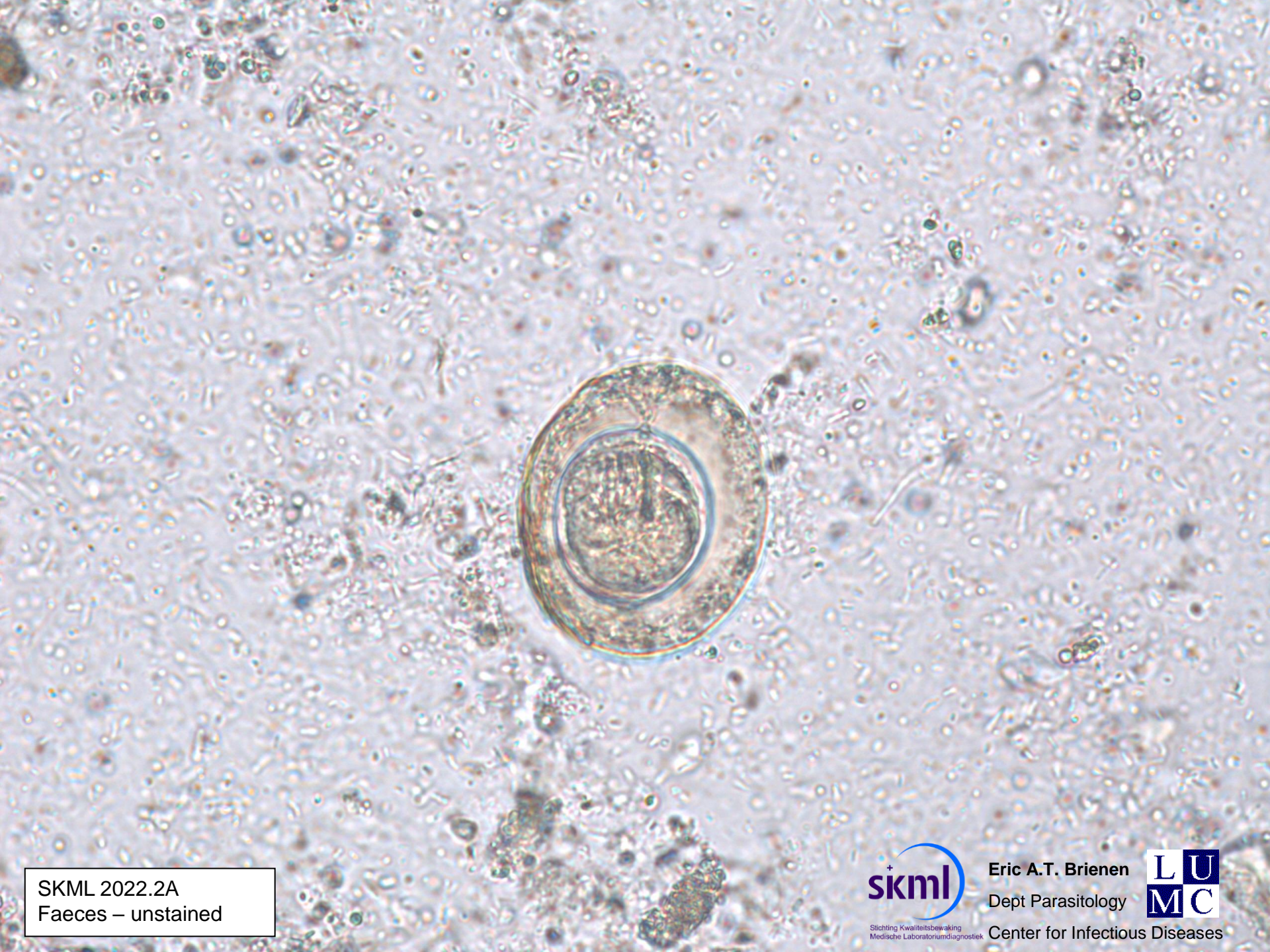


Stichting Kwaliteitsbewaking
Medische Laboratoriumdiagnostiek

Eric A.T. Brienens
Dept Parasitology



Center for Infectious Diseases



SKML 2022.2A
Faeces – unstained

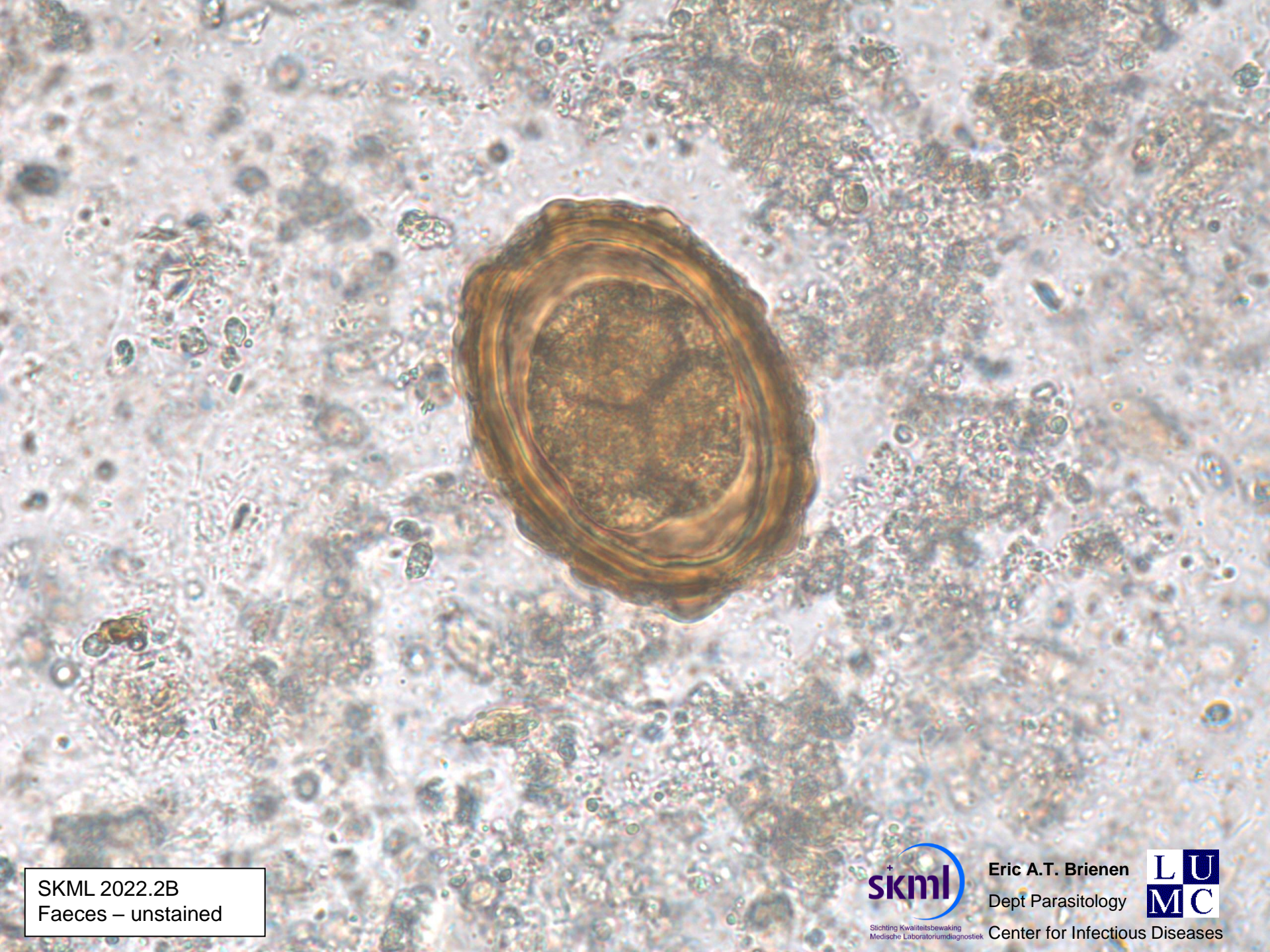


Stichting Kwaliteitsbewaking
Medische Laboratoriumdiagnostiek

Eric A.T. Brienen
Dept Parasitology



Center for Infectious Diseases



SKML 2022.2B
Faeces – unstained

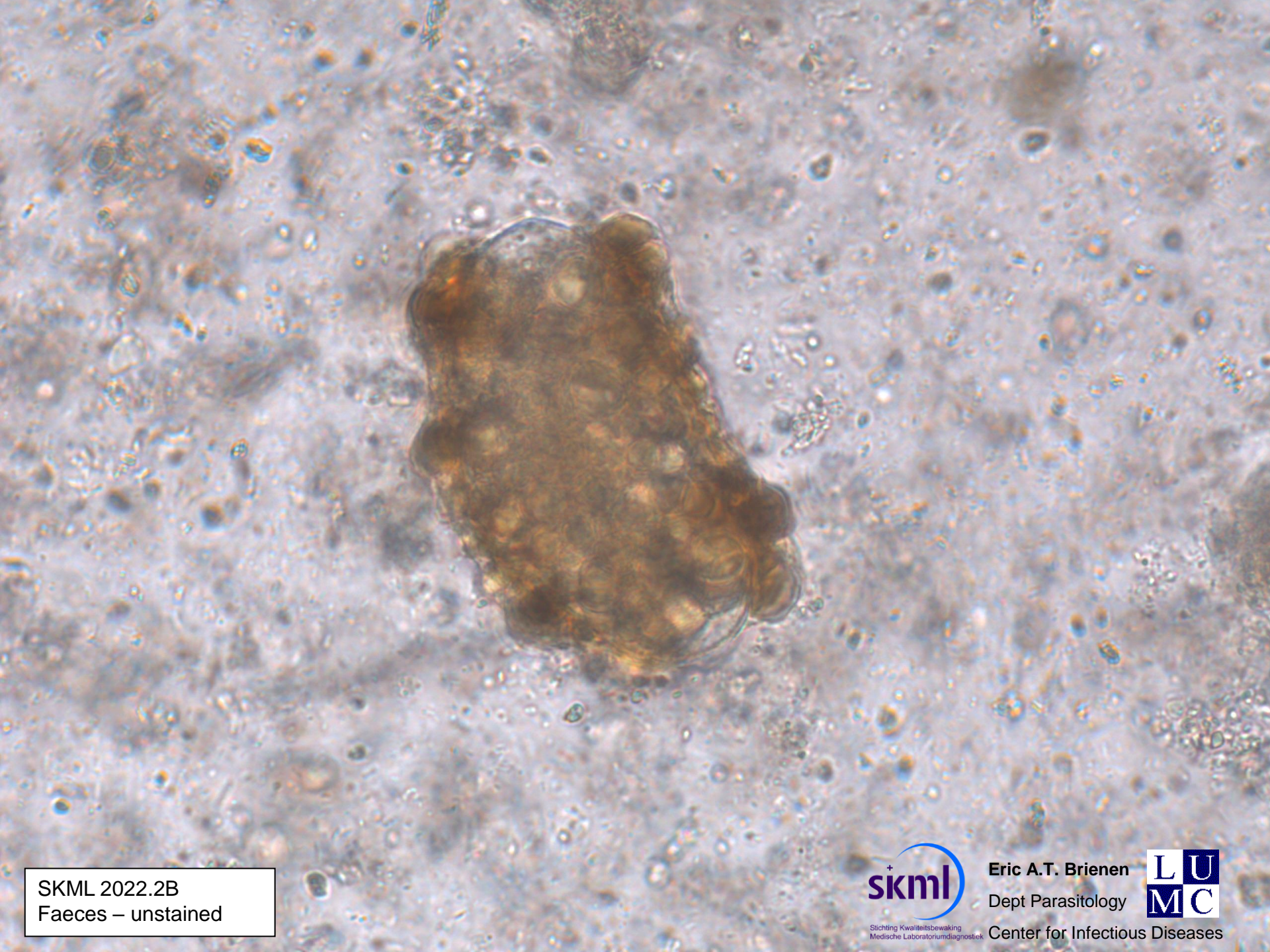


Stichting Kwaliteitsbewaking
Medische Laboratoriumdiagnostiek

Eric A.T. Brienen
Dept Parasitology



Center for Infectious Diseases



SKML 2022.2B
Faeces – unstained

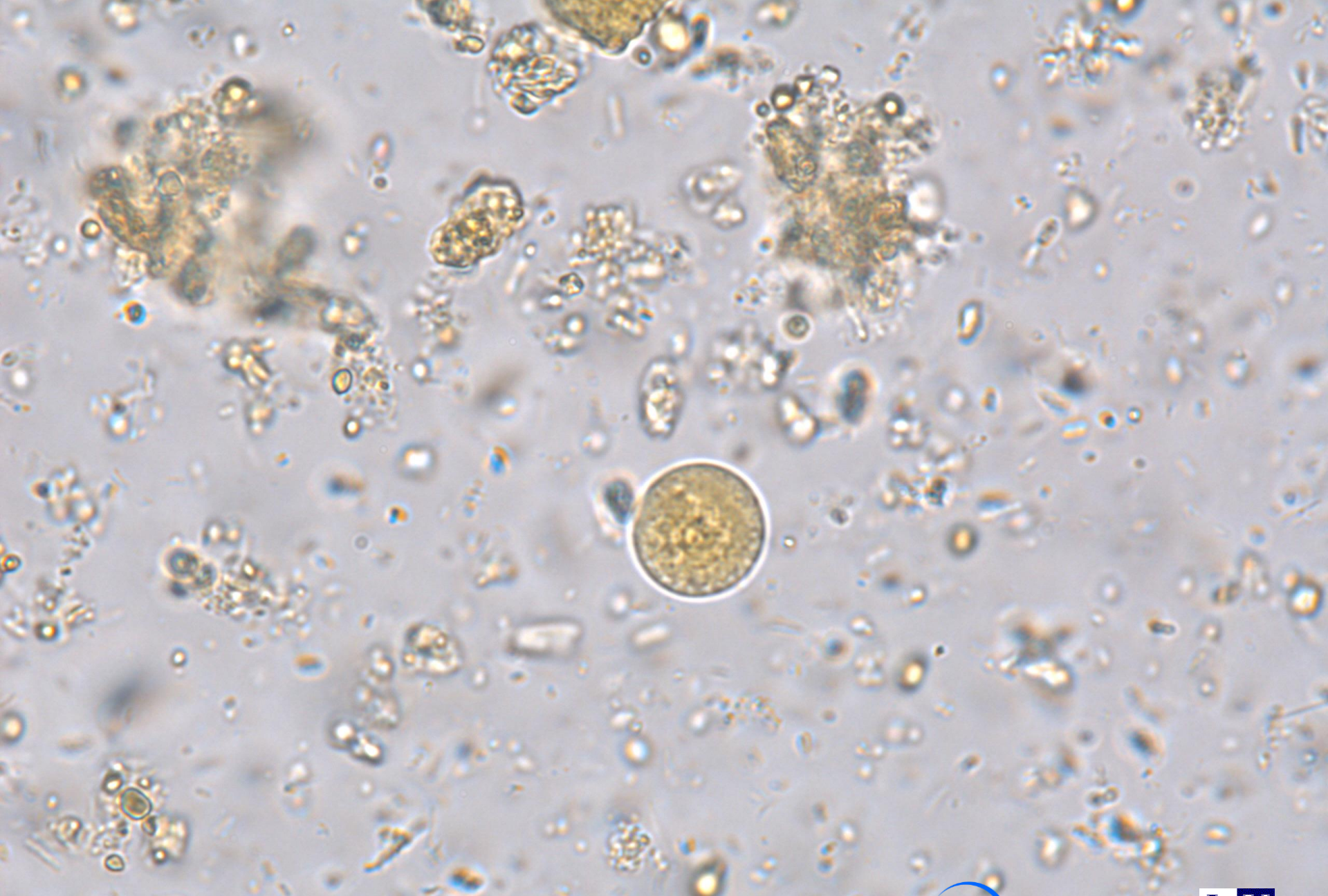


Stichting Kwaliteitsbewaking
Medische Laboratoriumdiagnostiek

Eric A.T. Brienen
Dept Parasitology



Center for Infectious Diseases



SKML 2022.2B
Faeces – Iodine stained

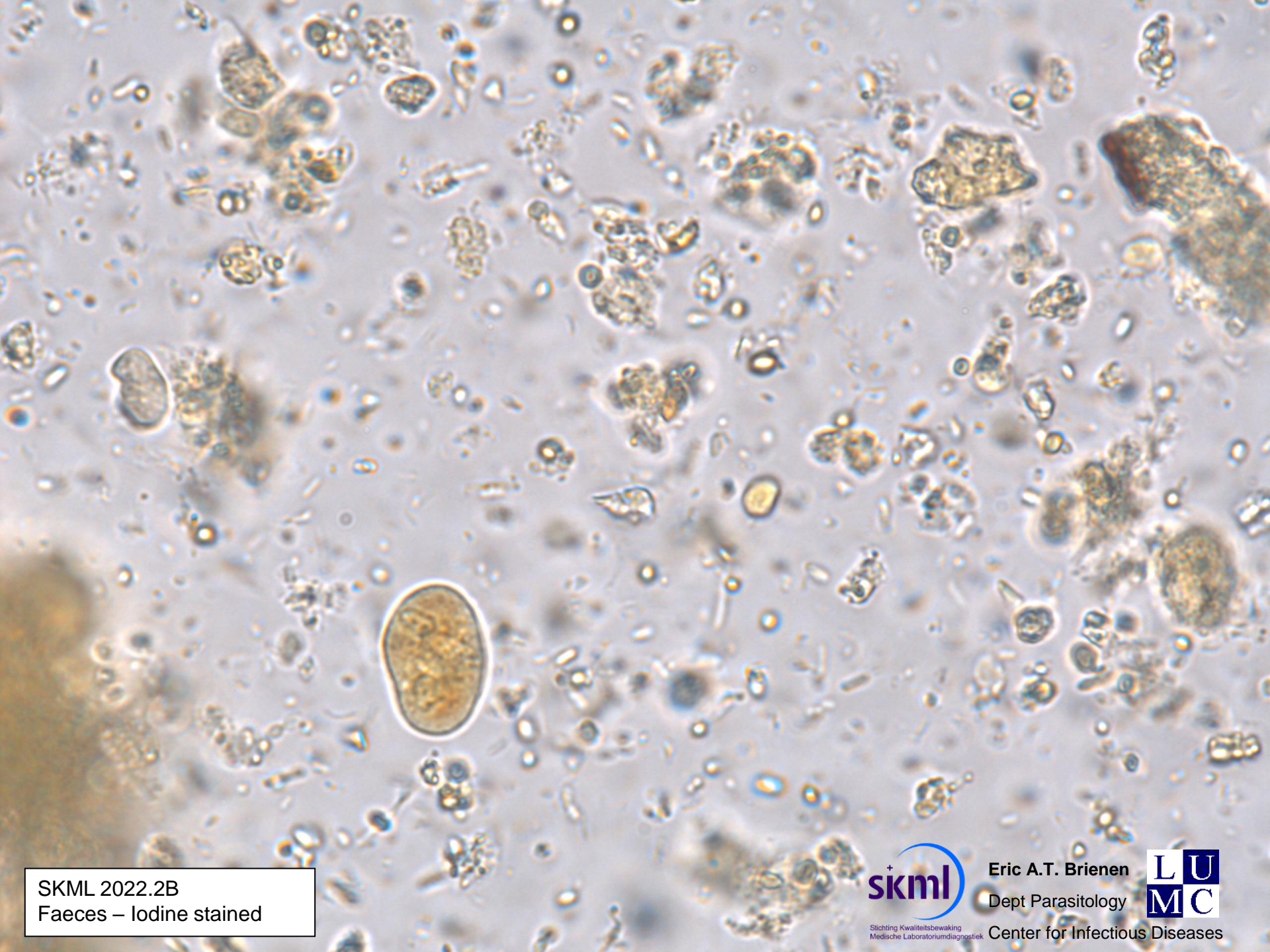


Stichting Kwaliteitsbewaking
Medische Laboratoriumdiagnostiek

Eric A.T. Brienen
Dept Parasitology



Center for Infectious Diseases



SKML 2022.2B
Faeces – Iodine stained

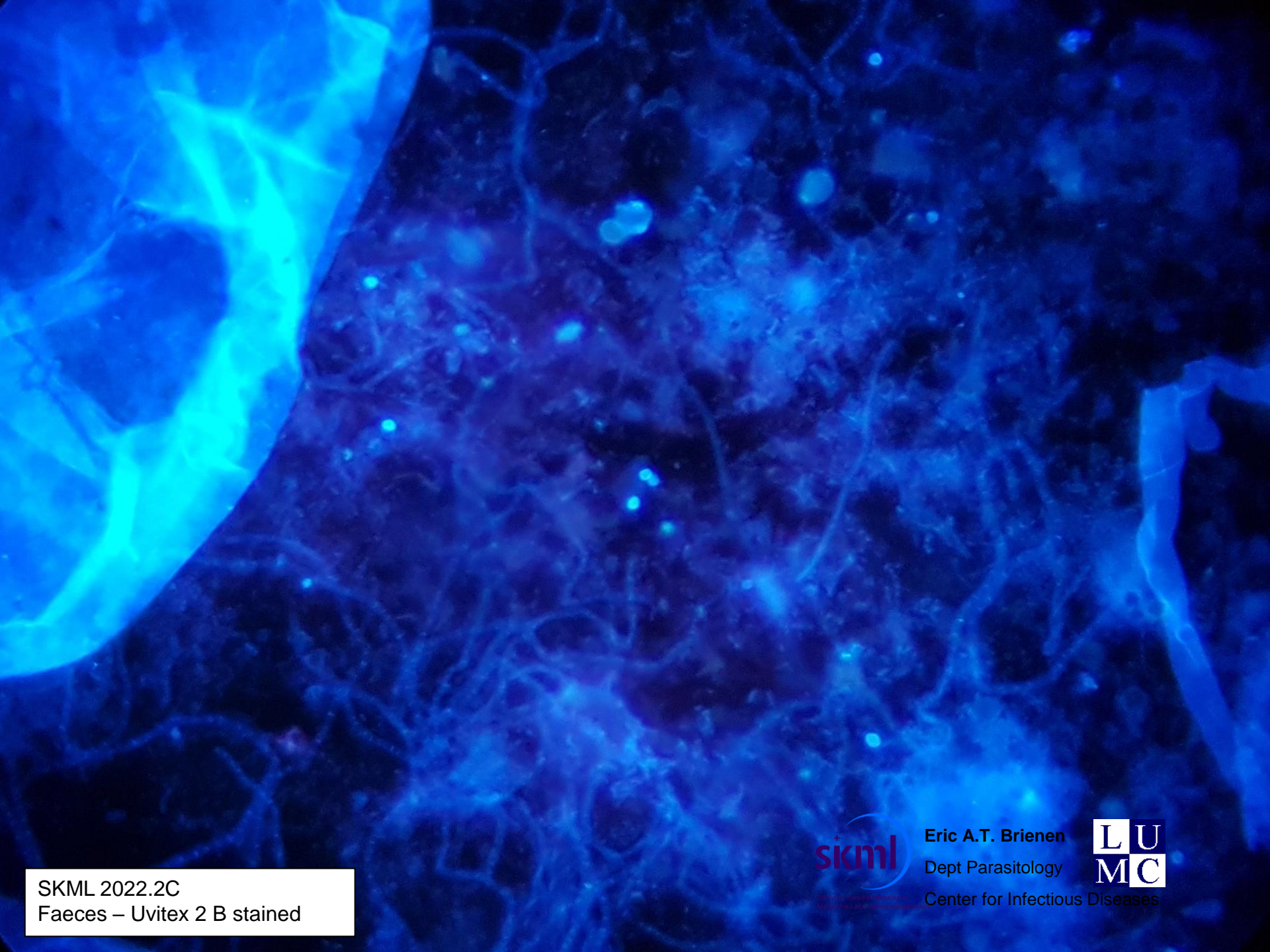


Stichting Kwaliteitsbewaking
Medische Laboratoriumdiagnostiek

Eric A.T. Brienens
Dept Parasitology



Center for Infectious Diseases

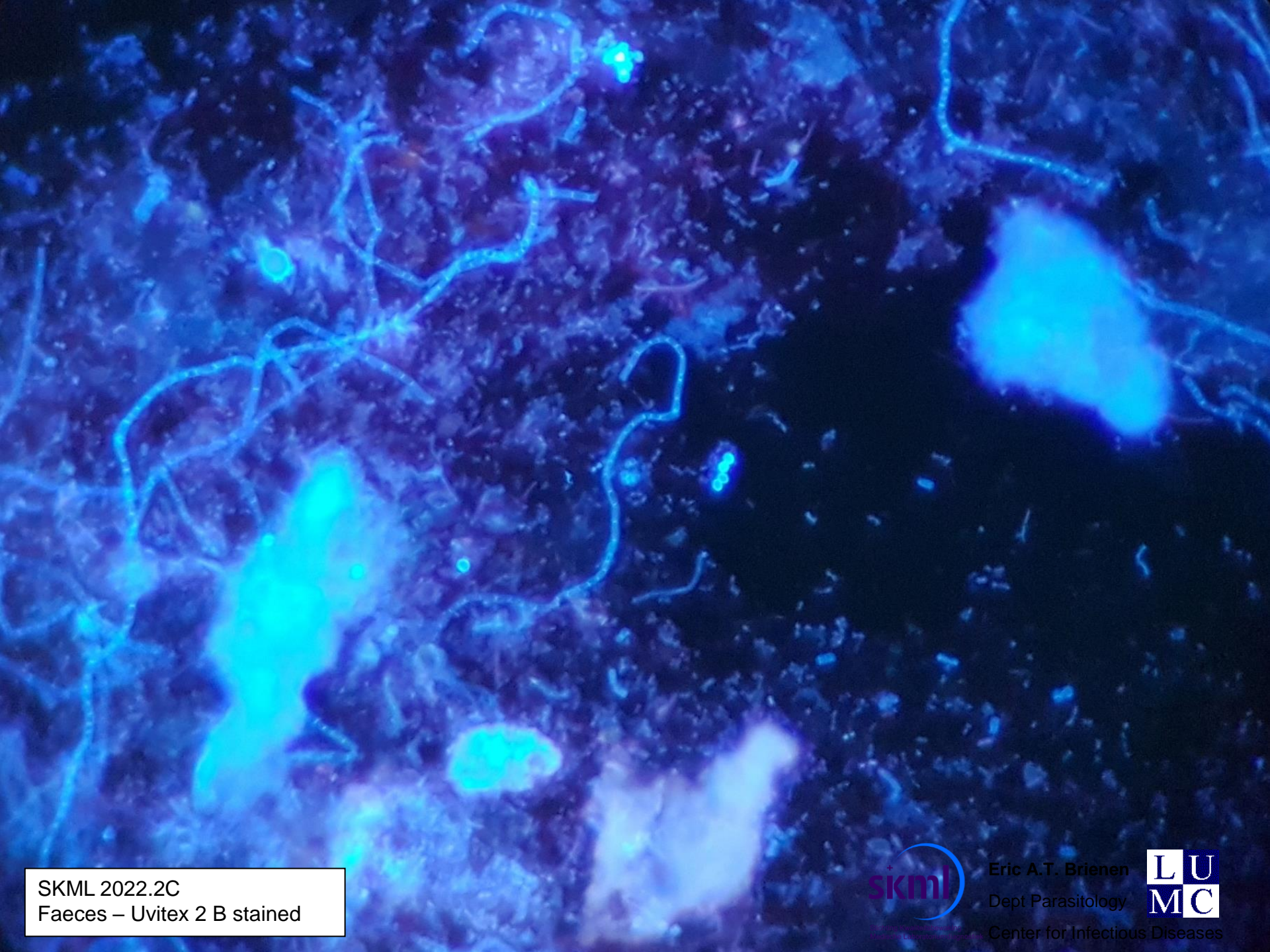


SKML 2022.2C
Faeces – Uvitex 2 B stained



Eric A.T. Brienen
Dept Parasitology
Center for Infectious Diseases



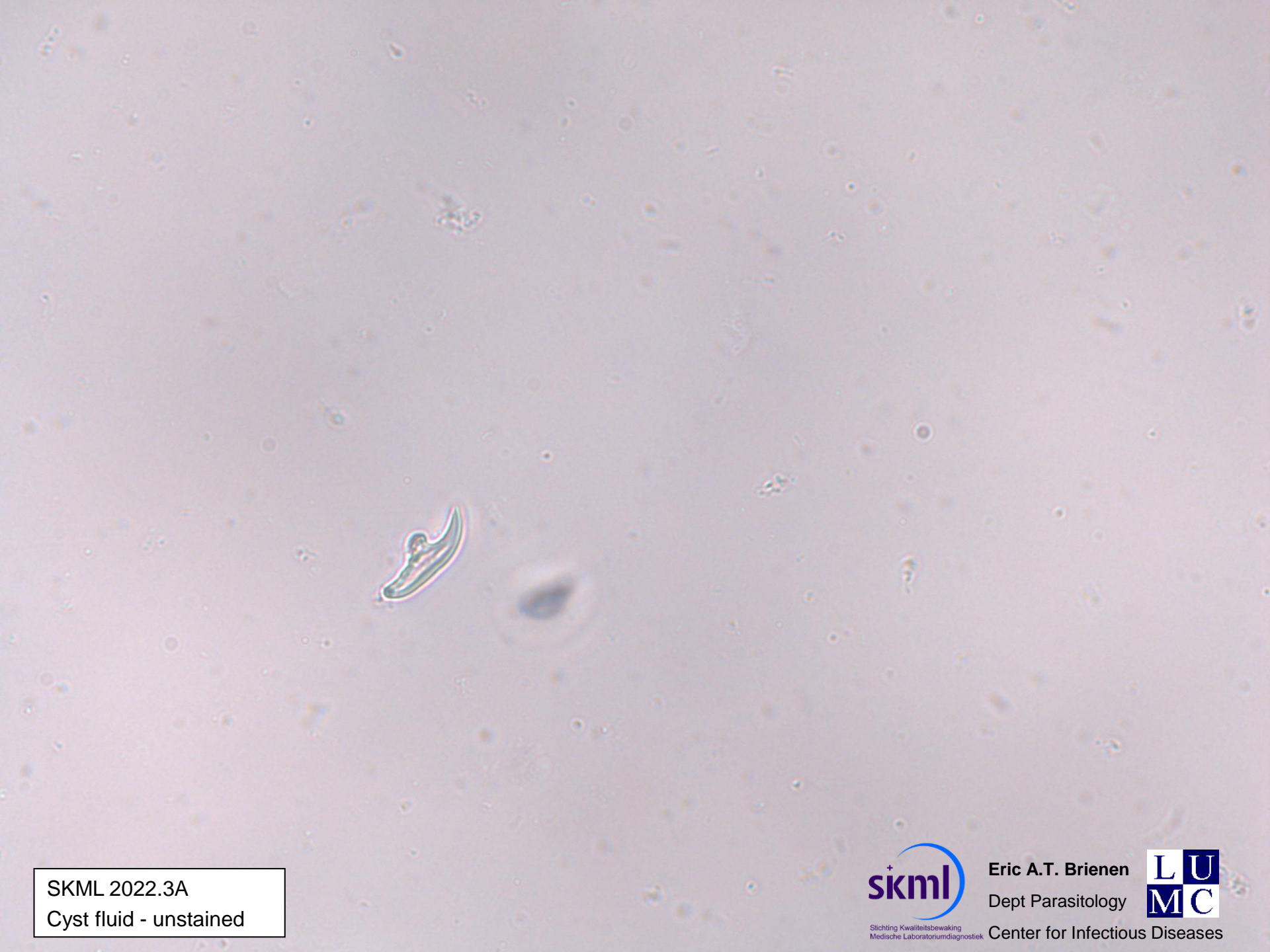


SKML 2022.2C
Faeces – Uvitex 2 B stained



Eric A.T. Brienen
Dept Parasitology
Center for Infectious Diseases





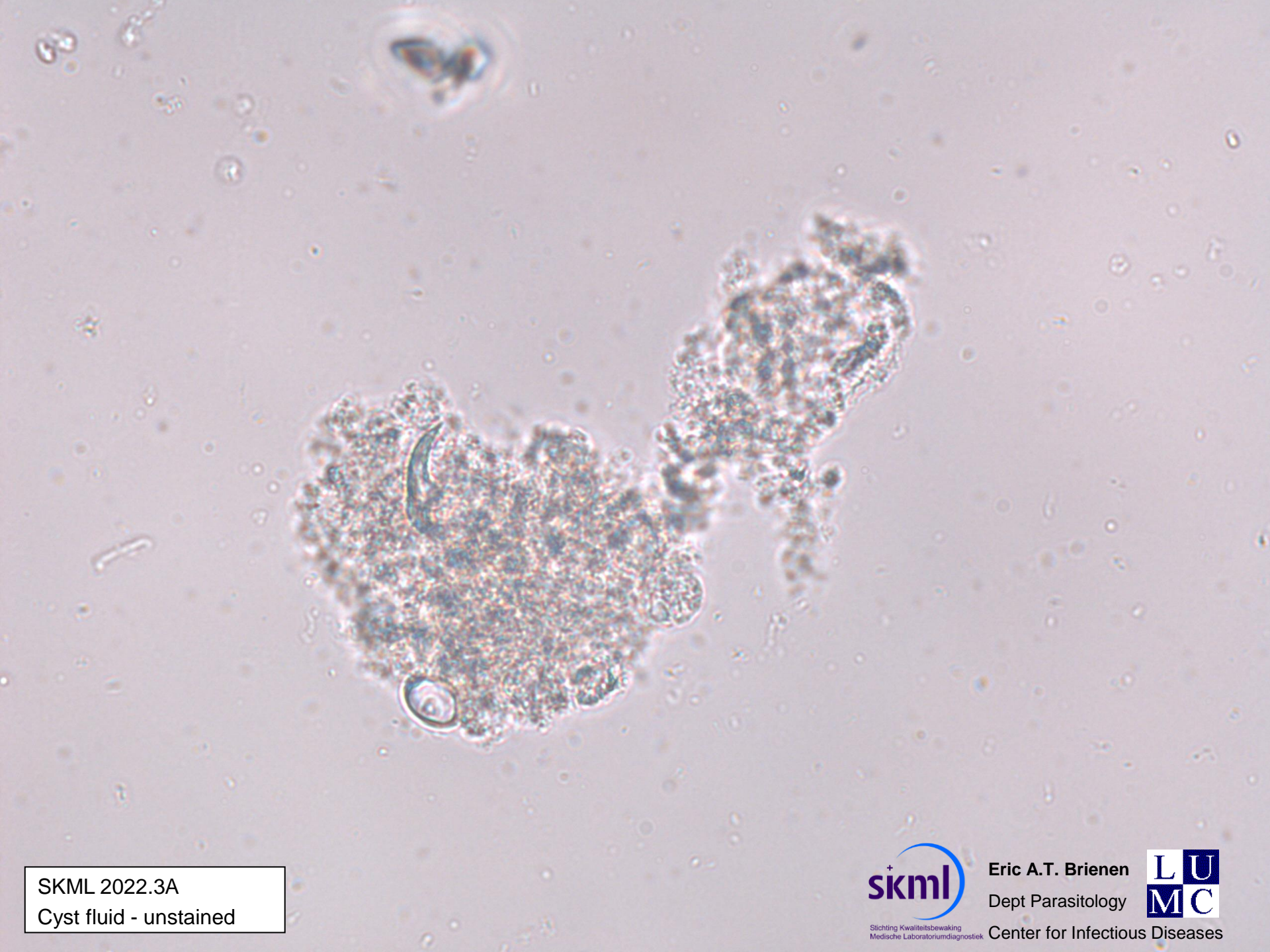
SKML 2022.3A
Cyst fluid - unstained



Eric A.T. Brienens
Dept Parasitology



Center for Infectious Diseases



SKML 2022.3A
Cyst fluid - unstained

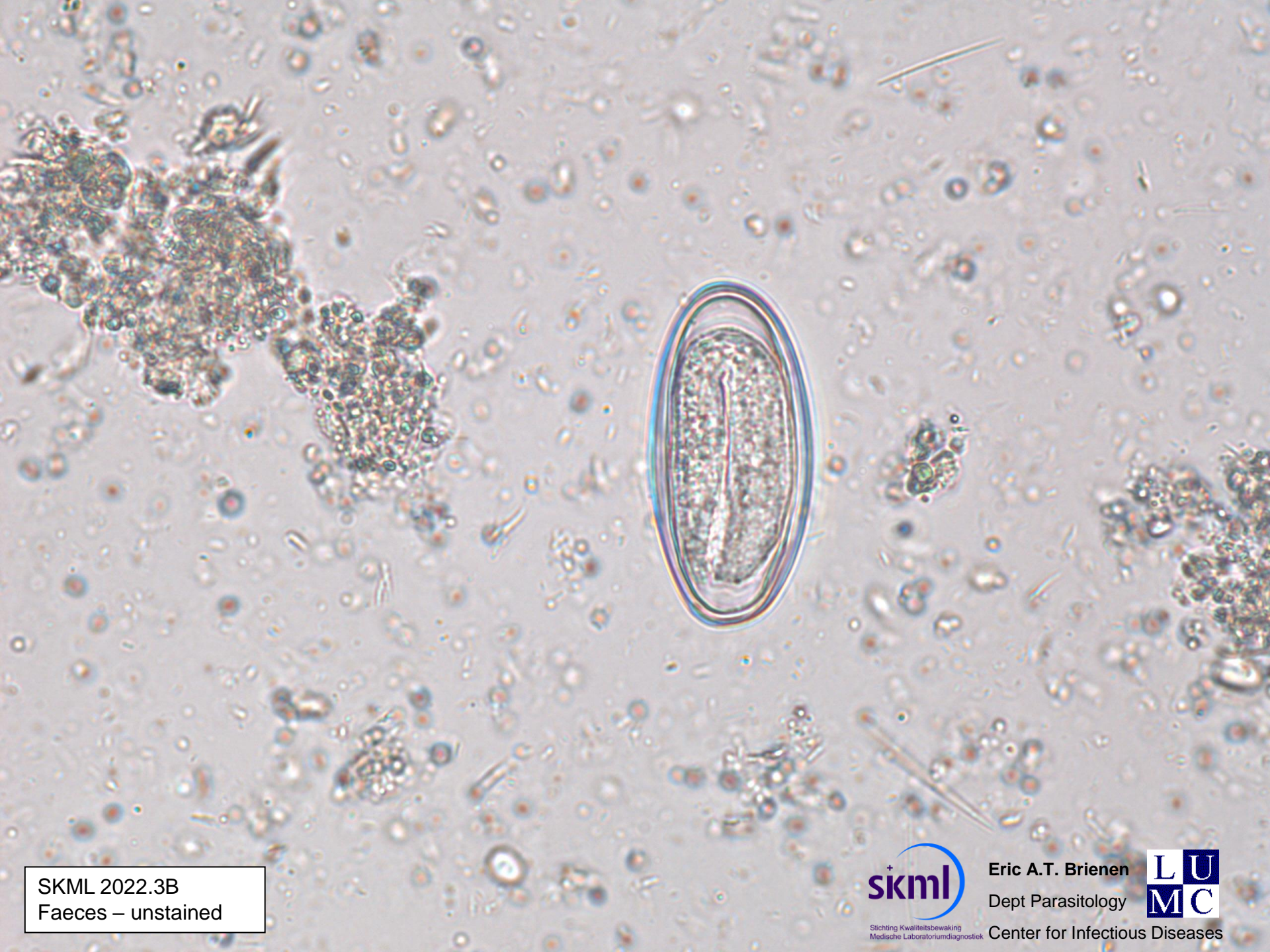

Stichting Kwaliteitsbewaking
Medische Laboratoriumdiagnostiek

Eric A.T. Brienen
Dept Parasitology



Center for Infectious Diseases



SKML 2022.3B
Faeces – unstained

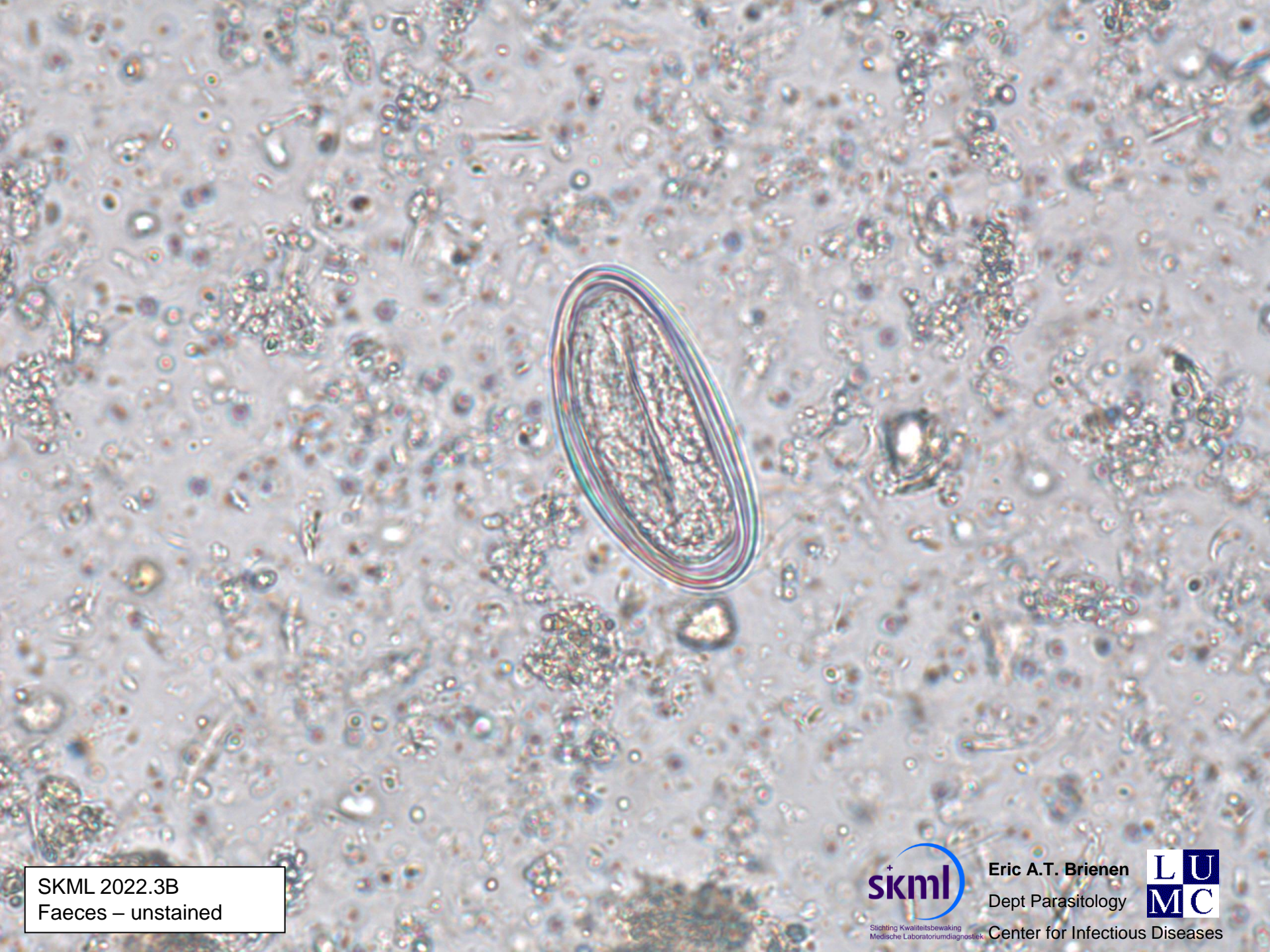

Stichting Kwaliteitsbewaking
Medische Laboratoriumdiagnostiek

Eric A.T. Brienen
Dept Parasitology



Center for Infectious Diseases



SKML 2022.3B
Faeces – unstained

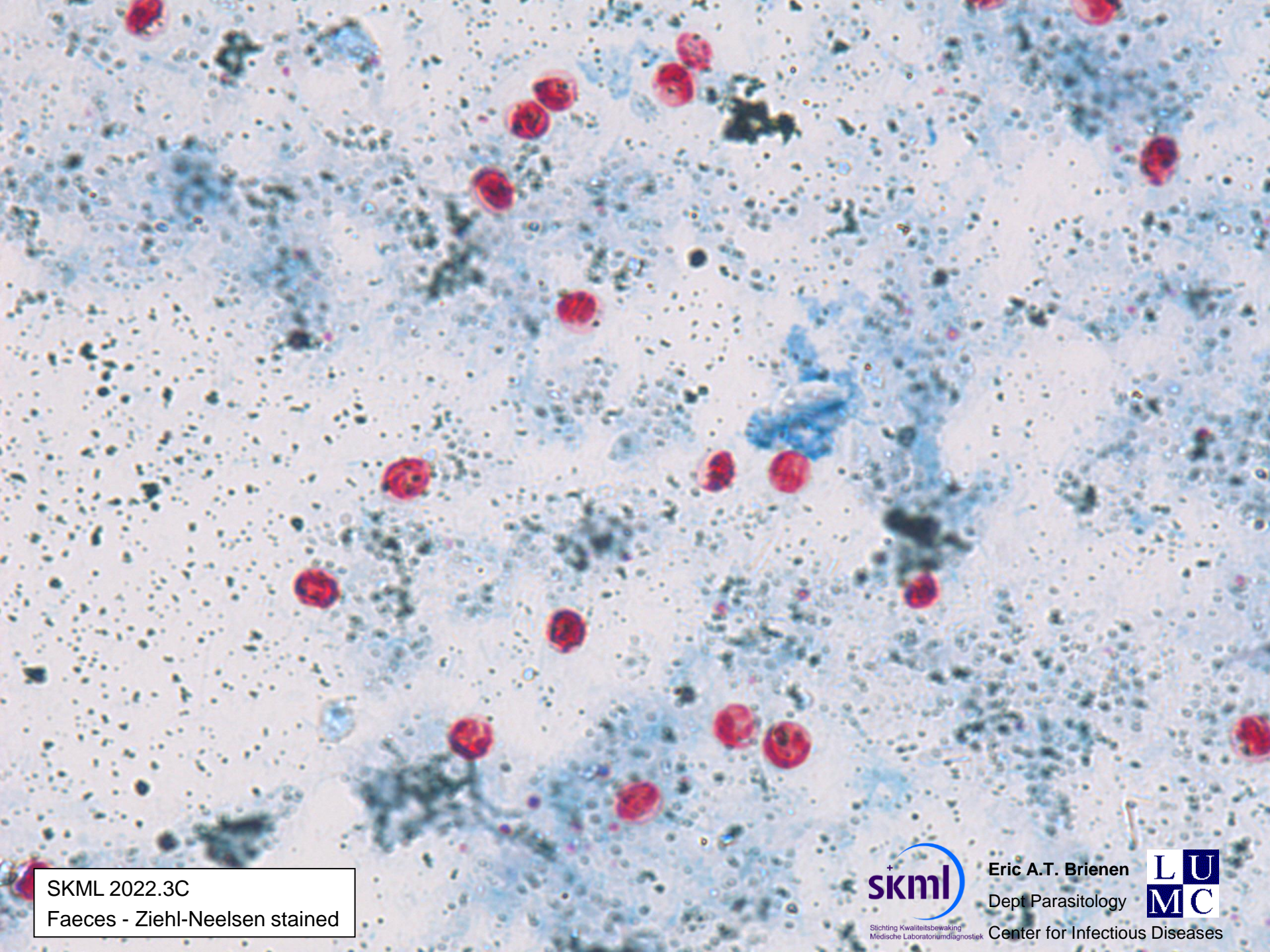


Stichting Kwaliteitsbewaking
Medische Laboratoriumdiagnostiek

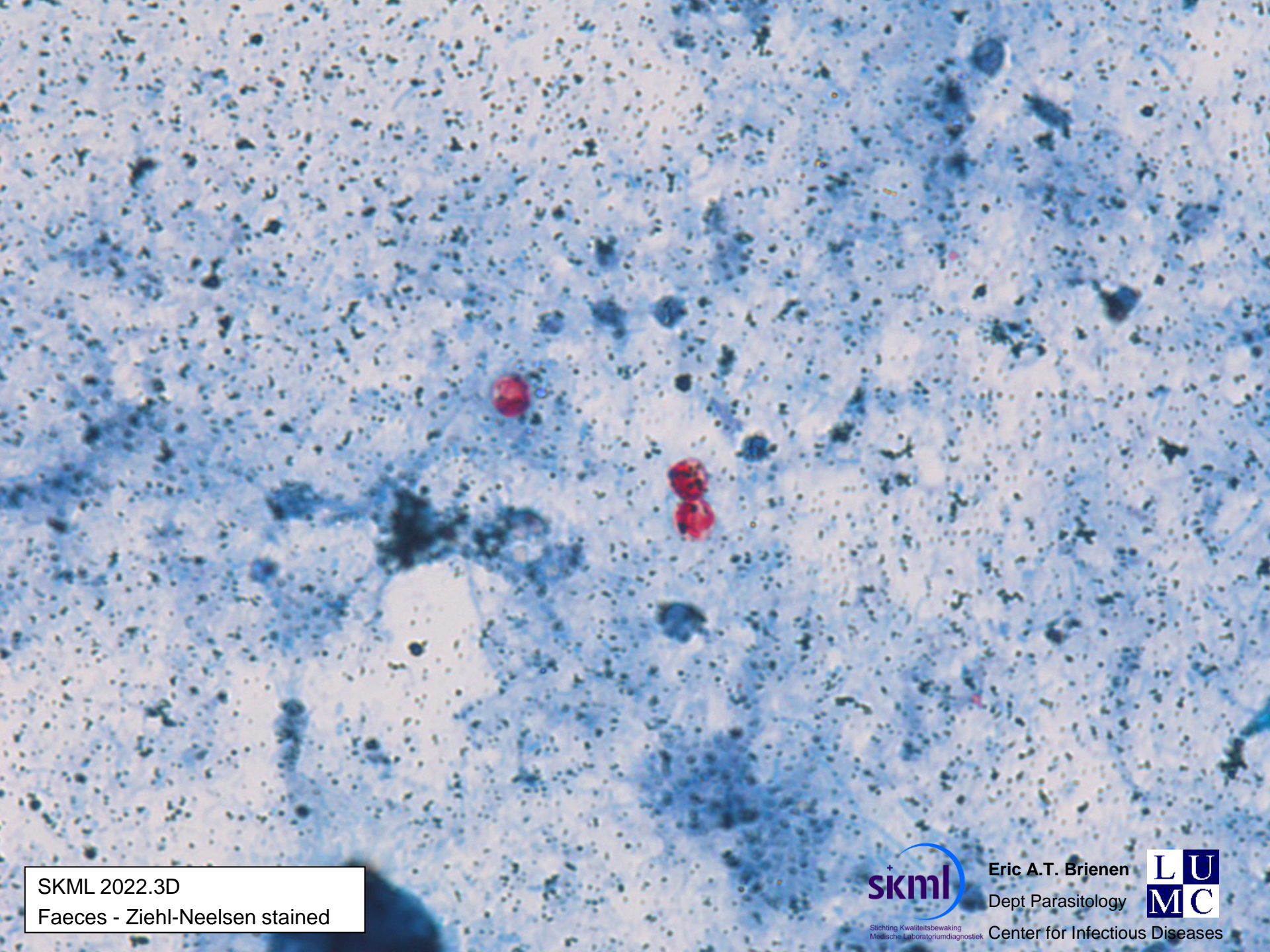
Eric A.T. Brienen
Dept Parasitology



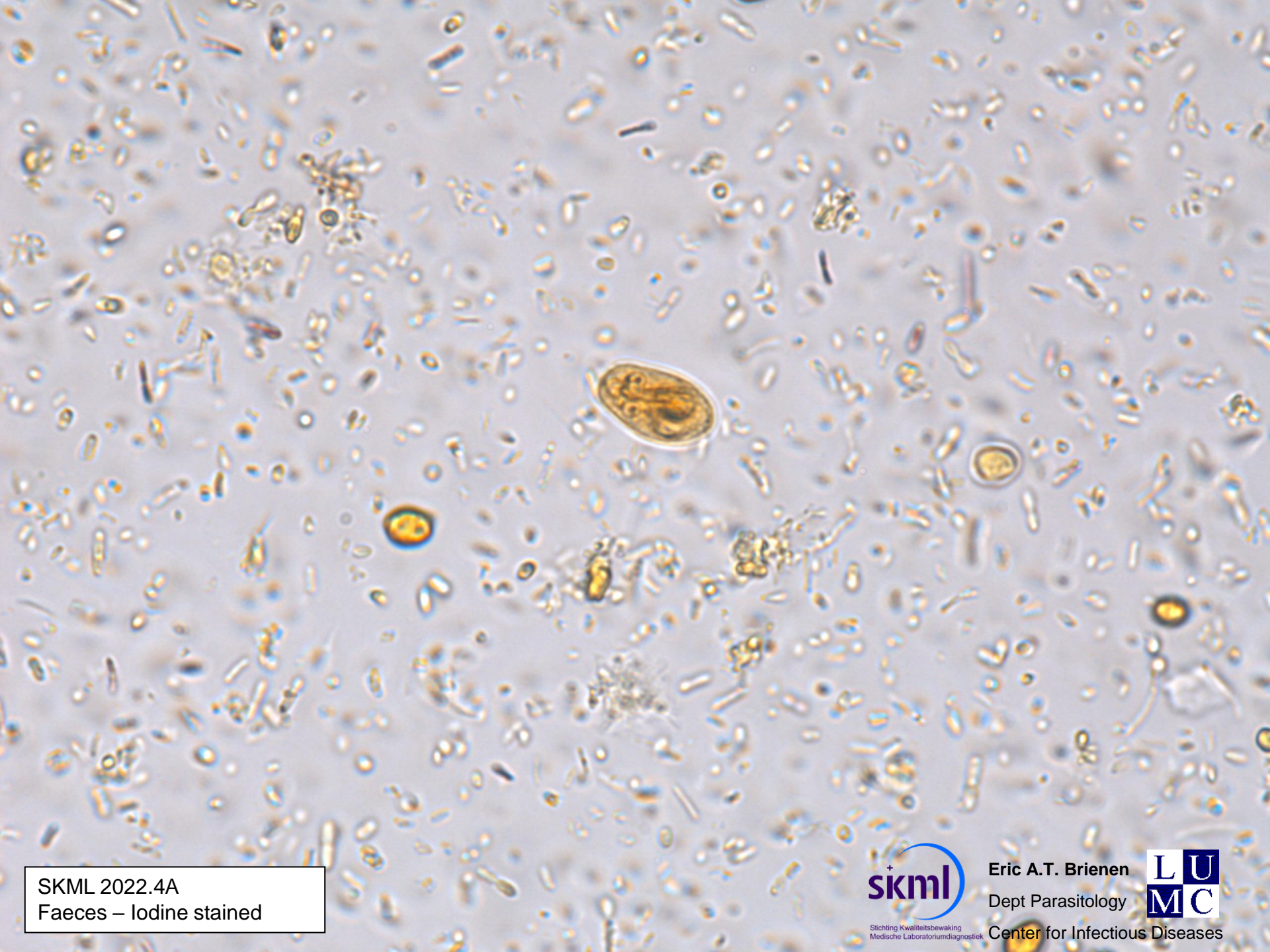
Center for Infectious Diseases



SKML 2022.3C
Faeces - Ziehl-Neelsen stained



SKML 2022.3D
Faeces - Ziehl-Neelsen stained



SKML 2022.4A
Faeces – Iodine stained

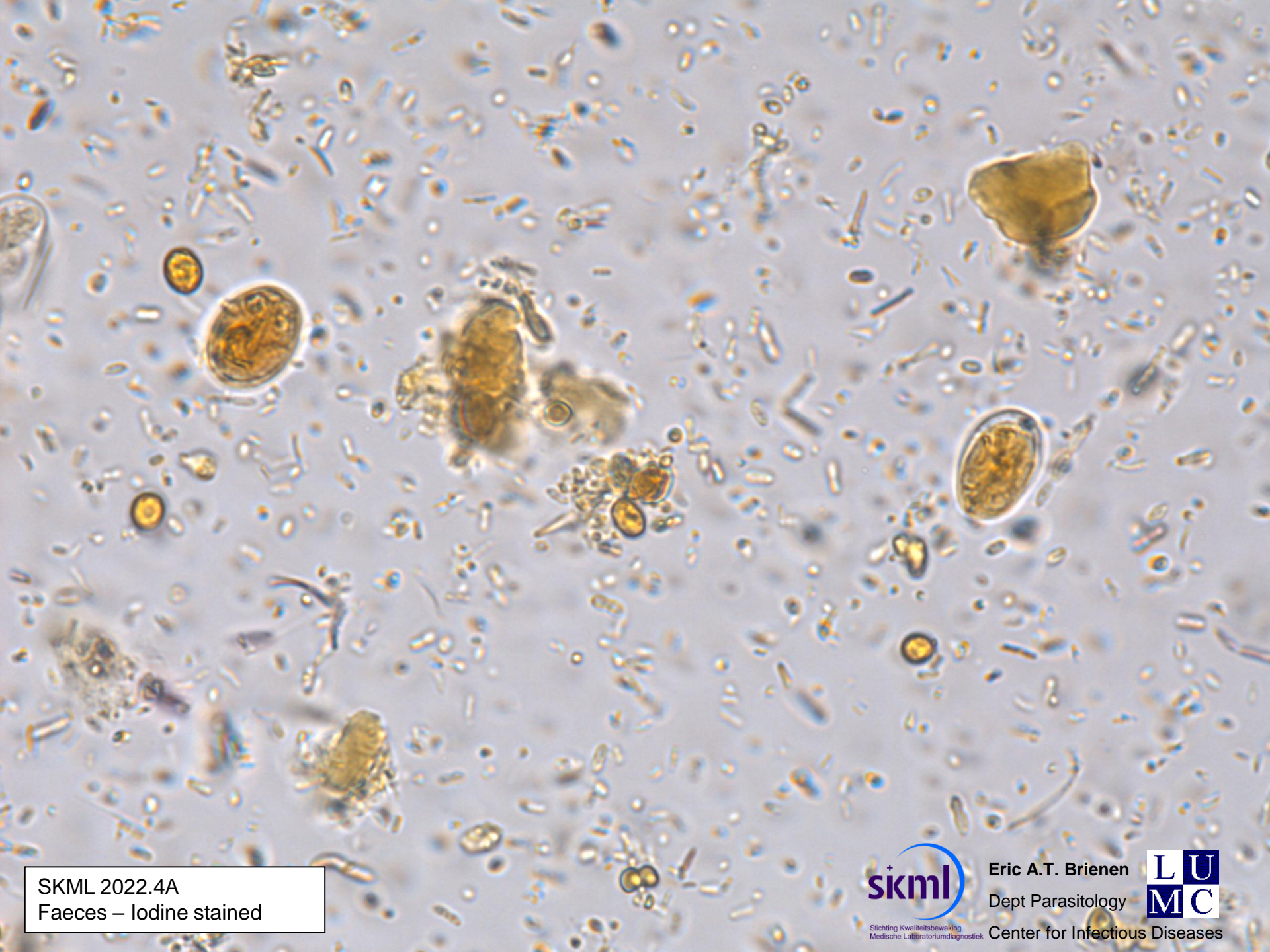


Stichting Kwaliteitsbewaking
Medische Laboratoriumdiagnostiek

Eric A.T. Brienens
Dept Parasitology



Center for Infectious Diseases



SKML 2022.4A
Faeces – Iodine stained




Stichting Kwaliteitsbewaking
Medische Laboratoriumdiagnostiek

Eric A.T. Brienen

Dept Parasitology

Center for Infectious Diseases





SKML 2022.4A
Faeces – Iodine stained

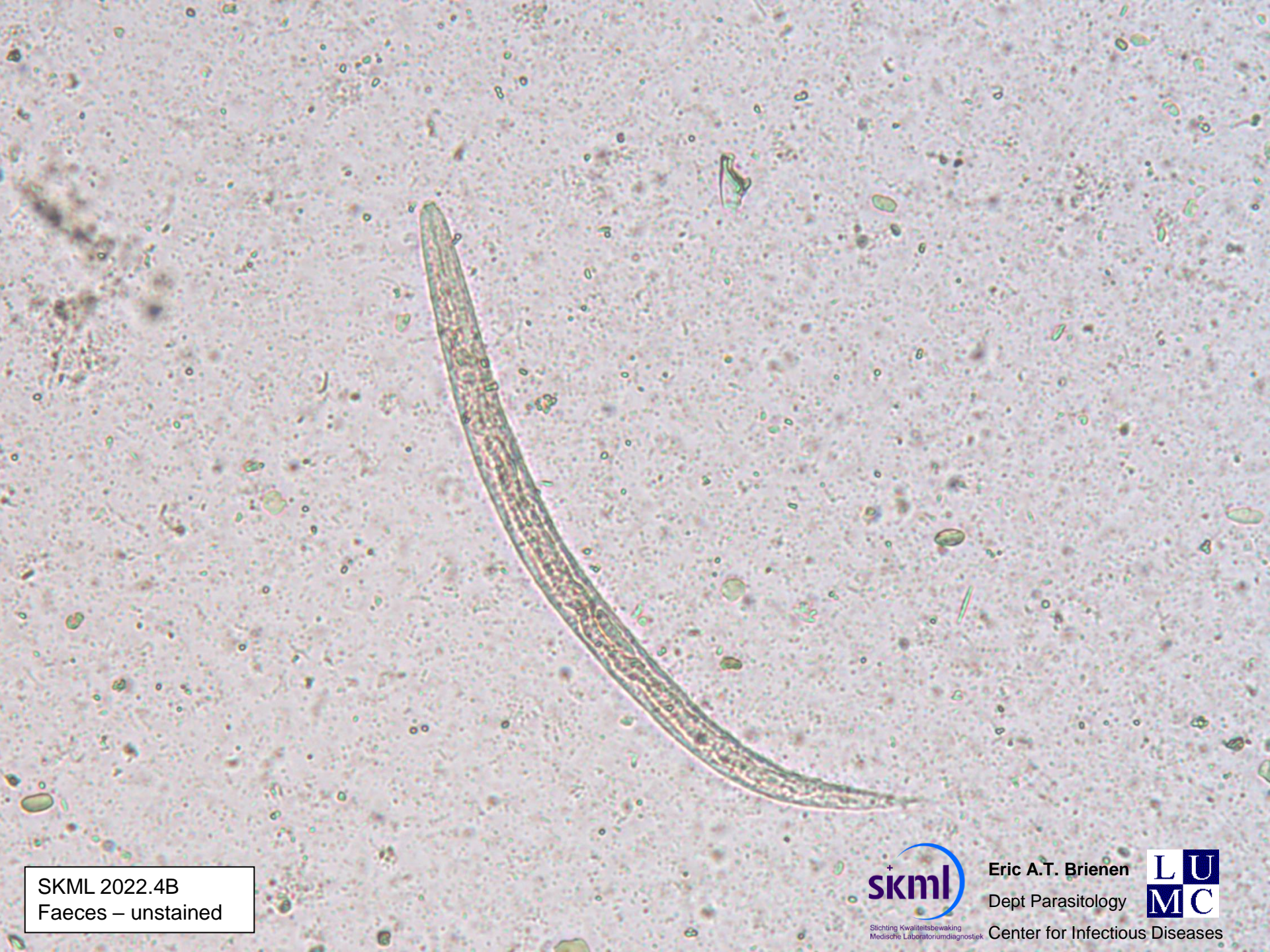

Stichting Kwaliteitsbewaking
Medische Laboratoriumdiagnostiek

Eric A.T. Brienens
Dept Parasitology



Center for Infectious Diseases



SKML 2022.4B
Faeces – unstained

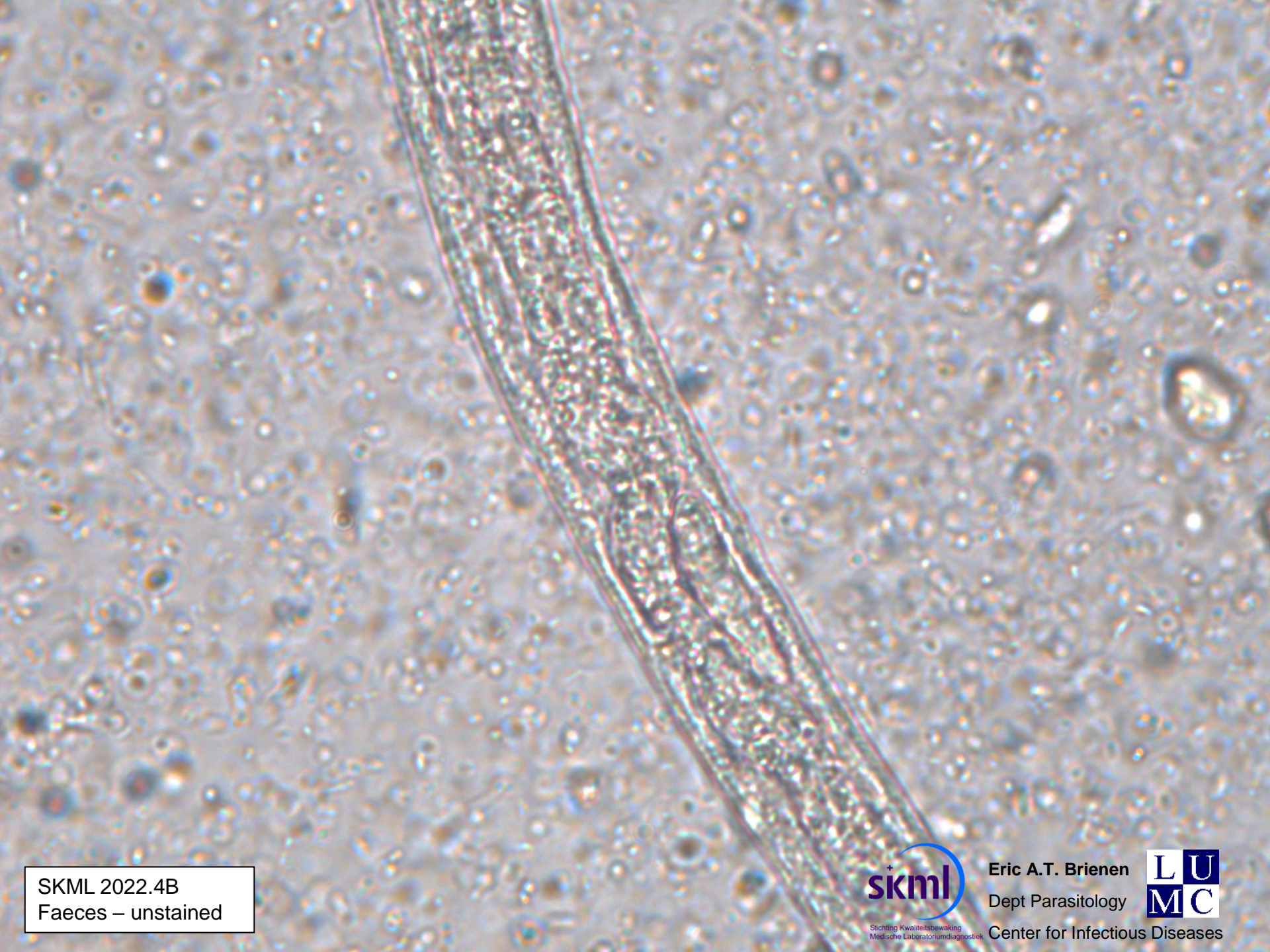

Stichting Kwaliteitsbewaking
Medische Laboratoriumdiagnostiek

Eric A.T. Brienen
Dept Parasitology



Center for Infectious Diseases



SKML 2022.4B
Faeces – unstained



Stichting Kwaliteitsbewaking
Medische Laboratoriumdiagnostiek

Eric A.T. Brienens
Dept Parasitology



Center for Infectious Diseases

SKML morphology parasitology – explanations

2022.1A *Plasmodium vivax* (only thick smear)

2022.1B *Plasmodium falciparum* \approx 1,5 %

2022.2A *Trypanosoma brucei* spp.

2022.2B *Plasmodium falciparum* \approx 1,4 % (only thin smear)

2022.3A *Plasmodium falciparum* (with schizonts and gametocytes) \approx 27 %

2022.3B *Plasmodium falciparum* \approx 1,75 %

2022.4A *Plasmodium falciparum* \approx 0,05 %

2022.4B *Plasmodium ovale*

2022.1A *Echinococcus granulosus* (with protoscolices)

2022.1B *Hymenolepis diminuta* (eggs)

2022.2A *Hymenolepis nana* (eggs)

2022.2B *Ascaris* spp. (eggs) + *Entamoeba histolytica/dispar* (cysts)

2022.2C *Enterocytozoon bieneusi* (spores)

2022.3A *Echinococcus granulosus* (only hooks)

2022.3B *Enterobius vermicularis* (eggs)

2022.3C *Cryptosporidium* spp. (oocysts)

2022.3D *Cryptosporidium* spp. (oocysts)

2022.4A *Giardia lamblia* (cysts and trophozoites) + *Hymenolepis nana* (eggs)

2022.4B *Strongyloides stercoralis* (rhabditiform larvae)